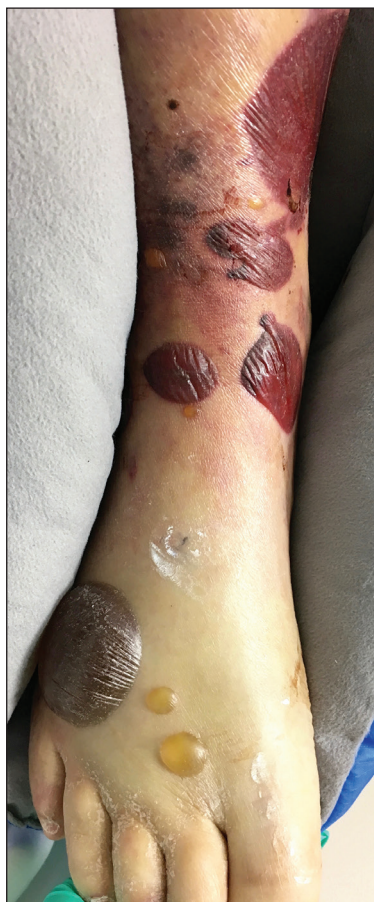

# Serous and Hemorrhagic Bullae on the Leg

Jacqueline Lin Bucher, MD; Mehwish Ahmed, MD

## Eligible for 1 MOC SA Credit From the ABD

This Photo Challenge in our print edition is eligible for 1 self-assessment credit for Maintenance of Certification from the American Board of Dermatology (ABD). After completing this activity, diplomates can visit the ABD website (<http://www.abderm.org>) to self-report the credits under the activity title "Cutis Photo Challenge." You may report the credit after each activity is completed or after accumulating multiple credits.



A 61-year-old wheelchair-bound man presented to the emergency department with increased swelling, bruising, and blister formation on the right lower leg over the last week. He had history of alcoholism and heavy smoking. Two weeks prior to presentation he had an open reduction and internal fixation of a right hip fracture. He recently started taking naproxen for pain and had taken a course of ciprofloxacin for a urinary tract infection. Physical examination showed a well-healed surgical wound along the right upper lateral thigh with no purulence or erythema. His right lower leg had extensive ecchymosis and pitting edema, and there was a cluster of well-defined, variably sized, serous and hemorrhagic bullae over the right lower ankle and dorsal aspect of the foot. He was hemodynamically stable and afebrile. Due to initial concern of cellulitis, he was given a dose of vancomycin in the emergency department. Computed tomography of the right leg showed diffuse edematous changes consistent with the recent surgery, and duplex ultrasonography showed no evidence of deep vein thrombosis. A shave biopsy was performed.

## WHAT'S THE DIAGNOSIS?

- bullous cellulitis
- bullous drug reaction
- bullous pemphigoid
- fracture blisters
- linear IgA bullous dermatosis

PLEASE TURN TO **PAGE 212** FOR THE DIAGNOSIS

Dr. Bucher is from the University of Texas Health Science Center at San Antonio. Dr. Ahmed is from the Department of Internal Medicine, University of Michigan, Ann Arbor.

The authors report no conflict of interest.

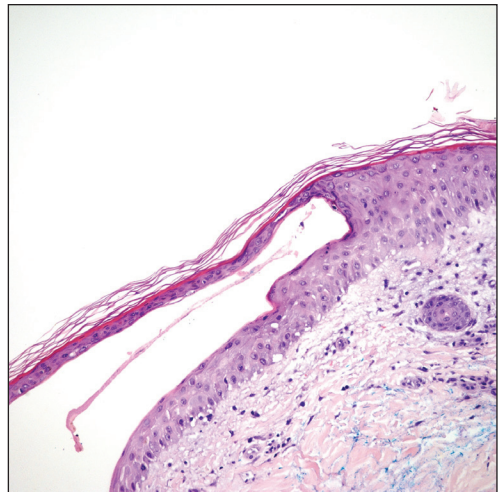
Correspondence: Mehwish Ahmed, MD, 448 Marblewood Ln, Saline, MI 48176 ([mehwish1028@gmail.com](mailto:mehwish1028@gmail.com)).

## THE DIAGNOSIS: Fracture Blisters

The shave biopsy pathology demonstrated a subepidermal bulla with re-epithelialization that was clinically consistent with fracture blisters (also known as fracture bullae)(Figure). Fracture blisters are a complication of bone fractures, usually occurring 24 to 48 hours after the trauma but possibly up to 3 weeks later. The skin usually is edematous with tense bullae overlying the fracture (in this case it was distal to the fracture); most blisters contain clear fluid, but older blisters tend to be more flaccid with hemorrhagic fluid.<sup>1</sup> The cause is thought to be the result of skin strain during fracture formation.<sup>2</sup> Edema and hypoxia from injured vessels and lymphatics contribute to the formation of bullae, which are seen as a dermoepidermal junction split on histology.<sup>1</sup>

The bullae are histologically indistinguishable from edema blisters. A clinical history can help to differentiate. Edema blisters occur in the setting of an acute exacerbation of chronic edema, usually on the lower extremities in the setting of fluid overload.<sup>3</sup> Bullous cellulitis is associated with skin erythema, warmth, and systemic symptoms. Bullous pemphigoid can be localized to the lower legs at times; however, biopsy would show a subepidermal bulla with eosinophils along the dermoepidermal junction. Linear IgA bullous dermatosis can be drug induced from vancomycin; however, pathology would show a subepidermal blister with a neutrophil predominant infiltrate. Nonsteroidal anti-inflammatory medications such as naproxen are a common culprit for bullous drug eruptions, which can be localized or generalized and include diagnoses such as fixed drug eruption, toxic epidermal necrolysis, and drug-induced pseudoporphyria. Naproxen-induced pseudoporphyria more commonly presents with blisters, erosions, and scarring with a predilection for the dorsal hands. Histology also will demonstrate subepidermal bullae. Clues to differentiate pseudoporphyria from fracture blisters include festooning of the dermal papilla and caterpillar bodies consisting of basement membrane material and colloid bodies in the basal layer of the epidermis, though they are not always present.<sup>4</sup>

Fracture blisters can be localized to the injury site or extend beyond the fracture site. They usually are found where there is minimal subcutaneous tissue, such as the tibia, ankles, and elbows. Fractures treated within



Pathology demonstrated a split at the dermoepidermal junction with re-epithelialization, clinically consistent with fracture blisters (H&E, original magnification  $\times 10$ ).

24 hours are much less likely to have bullae formation.<sup>1</sup> The bullae are sterile but may lead to wound healing complications, such as infections or delay in surgical management. However, there are no major adverse effects of postoperative fracture blisters.<sup>1</sup> Fracture blisters are self-healing, though silver sulfadiazine has been shown to minimize soft-tissue complications by promoting re-epithelialization.<sup>5</sup>

### REFERENCES

1. Varela CD, Vaughan TK, Carr JB, et al. Fracture blisters: clinical and pathological aspects. *J Orthop Trauma*. 1993;7:417-427.
2. Giordano CP, Scott D, Kummer F, et al. Fracture blister formation: a laboratory study. *J Trauma*. 1995;38:907-909.
3. Mascaro JM. Other vesicobullous diseases. In: Bologna JL, Schafer JV, Cerroni L, eds. *Dermatology*. Vol 1. Philadelphia, PA: Elsevier; 2018:554-561.
4. Patterson JW. The vesicobullous reaction pattern. In: Patterson JW. *Weedon's Skin Pathology*. 4th ed. Oxford, UK: Churchill Livingstone/Elsevier; 2016:135-187.
5. Strauss EJ, Petrucelli G, Bong M, et al. Blisters associated with lower-extremity fracture: results of a prospective treatment protocol. *J Orthop Trauma*. 2006;20:618-622.