

Man Thrown From Balky Bike

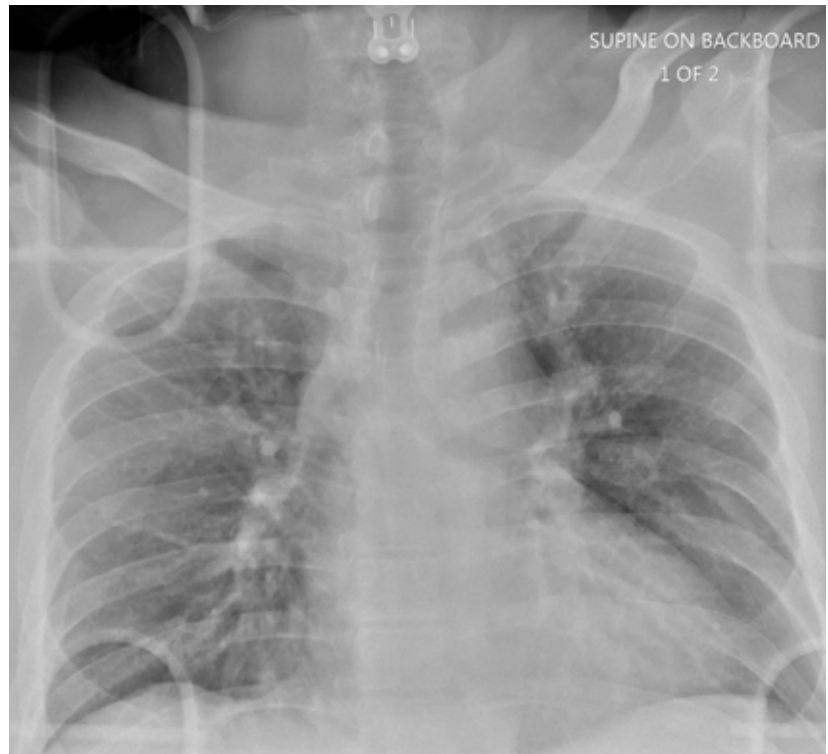
A 55-year-old man is brought to your facility following a motorcycle accident. He was a helmeted rider who was inadvertently thrown from the motorcycle when the accelerator got stuck. Bystanders reported he had brief loss of consciousness, but upon arrival to your facility, he is awake.

History is limited as the patient is confused and repetitive in his speech, indicating he is post concussive. He is complaining of head, face, and chest wall pain. His vital signs are all within normal limits; he is hemodynamically stable. His O₂ saturation is 98% on room air. Breath sounds are clear.

As you are completing your primary survey, portable chest

and pelvic radiographs are obtained. The chest radiograph is shown. What is your impression?

see answer on page 28 >>



Nandan R. Hichkad, PA-C, MMSc, practices at the Georgia Neurosurgical Institute in Macon.

>> *continued from page 23*

ANSWER

The radiograph does not demonstrate any evidence of acute chest or intrathoracic injury. Of note, it appears that the left humerus is dislocated anteriorly and inferiorly.

Dedicated shoulder radiographs were obtained, which confirmed the dislocation with no evidence of fracture. Orthopedics was consulted for evaluation and subsequent reduction. **CR**

