

# Obese Man With Severe Pain and Swollen Hand

Christen Goolsby, DNP, FNP-C, Chanique Ecby, DNP, FNP-C, Azizi Johnson-Aubert, DNP, FNP-C, Valerie Richard, DNP, FNP-C, Quinten Robertson, DNP, FNP-C

Christen Goolsby, Chanique Ecby, Azizi Johnson-Aubert, Valerie Richard, and Quinten Robertson are recent graduates of the Prairie View A&M University DNP Program and currently practice in Houston, Texas.

An obese 43-year-old Hispanic man presents to the emergency department (ED) with complaints of severe pain and swelling in his right hand. The patient states that he felt a bite on his hand as he was planting flowers and laying down potting soil near a tree and decorative rocks in his yard. He did not seek immediate medical treatment because the pain was minimal.

As the hours passed, though, the pain increased, and he began to notice tightness in his hand. Twelve hours after the initial bite, the pain became intolerable and his hand swelled to double its normal size, such that he could no longer bend his fingers. He then sought treatment at the ED.

The patient denies previous drug use but indicates that he smokes 1.5 packs of cigarettes daily and drinks alcohol occasionally in social settings. He has no known drug or food allergies. His history is remarkable for hypertension and hyperlipidemia, treated with simvastatin (40 mg/d) and lisinopril (10 mg/d), respectively.

The physical examination reveals an arterial blood pressure of 152/84 mm Hg; heart rate, 76 beats/min; respiratory rate, 18 breaths/min<sup>-1</sup>; and temperature, 99°F. His height is 5 ft 8 in and weight, 297 lb. Cardiovascular examination reveals no irregular heart rhythm, and S<sub>1</sub> and S<sub>2</sub> are heard, with no murmurs or gallops. He denies chest pain and palpitations. Respiratory examination reveals clear breath sounds that are equal and unlabored. He denies shortness of breath or coughing. The patient states that he had nausea earlier that day, but it has subsided.

Dermatologic examination reveals severe erythema and 3+ edema in the patient's right hand. A 3-cm, irregularly shaped, red,

hemorrhagic blister is observed close to the thumb on the posterior side of the right hand. There are two small holes in the center and slight bruising around the lesion. The right hand is hard and warm to the touch upon palpation, and the patient rates his pain as severe (10 out of 10).

The symptoms of severe pain and swelling and the early observation of bruising and hemorrhagic blistering raise suspicion for venomous spider bite (ICD-10 code: T63.331A). Laboratory work-up, including complete blood count, electrolytes, kidney function studies, and urinalysis, is performed. The results are inconclusive, and the reported symptoms and objective assessment are used to make the diagnosis of spider bite.

## DISCUSSION

The brown recluse spider (*Loxosceles reclusa*) is notorious for its bite, which can result in dermonecrosis within 24 to 48 hours. It inhabits the lower Midwest, south central, and southeastern regions of the United States and is not endemic in the West, Northeast, Mid-Atlantic, or Coastal South. Brown recluse spiders are nonaggressive and prefer warm, dark, dry habitats, dwelling under rocks, logs, woodpiles, and debris, as well as in attics, sheds, basements, boxes, travel bags, and motor vehicles.<sup>1,2</sup> They can survive for months without food and can withstand temperatures ranging from 46.4°F to 109.4°F.<sup>3</sup> They build irregular, cottony webs that serve as housing but are not used to capture prey.<sup>3</sup> (Note that webs found strung along walls, ceilings, outdoor vegetation, and in other exposed areas are nearly always associated with other types of spiders.) The brown

### IN THIS ARTICLE

- Diagnosis: questions to ask, page 22
- Treatment and management, page 22
- Follow-up care, page 24

recluse is nocturnal, seeking insect prey, either alive or dead.

Brown recluse spiders range in size from 6 mm to 20 mm; they have a violin-shaped pattern on the cephalothorax and long legs that allow them to move quickly (see Figure 1). A distinguishing feature is their six eyes, arranged in three pairs (most spiders have eight eyes).

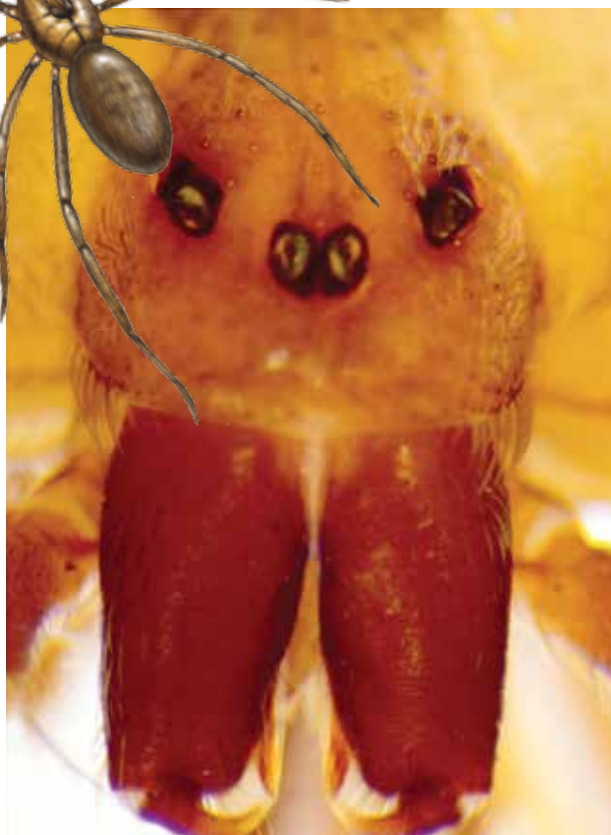
Venom production is influenced by the size and sex of the spider as well as ambient temperature.<sup>4</sup> The venom contains at least eight enzyme and protein components, including the most active enzyme, sphingomyelinase D.<sup>3</sup> This enzyme causes dermonecrosis, platelet aggregation, and complement-mediated hemolysis in vitro, and it may also be responsible for the ulcerating and systemic effects observed in humans.<sup>5</sup> Sphingomyelinase D has been shown to induce grossly visible tissue necrosis in rabbit tissue within 24 hours after envenomation.<sup>3</sup>

### CLINICAL PRESENTATION

The brown recluse spider bite may be imperceptible at the time of envenomation, requiring no medical attention. Depending on a person's sensitivity level and the amount of venom injected, however, a mild stinging sensation at the site may be felt, which is usually accompanied by redness and inflammation that may disappear within seconds or last for a couple of hours.<sup>6</sup>

Within two to eight hours, severe pain may occur, progressing to a burning sensation.<sup>5</sup> The bite site will become pale, due to venom-induced vasoconstriction, with increasing erythema and swelling in the surrounding tissue.<sup>5</sup> This extreme pain could be due to absorption of the venom by the muscle tissues; if untreated, further tissue damage can occur. Within 12 to 24 hours, there is painful edema with induration and an irregular area of ecchymosis and ischemia.<sup>7</sup> Occasionally, the site will develop red, white, and blue hemorrhagic blisters, with the blue ischemic portion centrally located and the red erythematous areas on the periphery.<sup>8</sup> In almost half of all cases, the le-

**FIGURE 1**  
*Loxosceles reclusa*



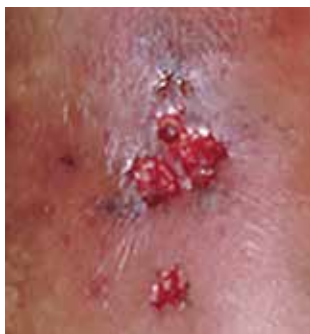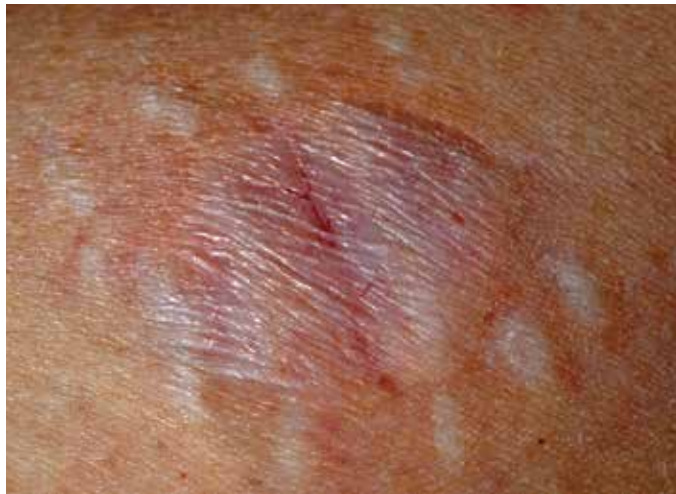Credits: Left, Scott Camazine & Rick Vetter/Science Source; right, Laurie O'Keefe/Science Source.

sion is associated with nonspecific systemic symptoms, such as generalized pruritus and rash, headache, nausea, vomiting, and low-grade fever in the first 24 to 48 hours.<sup>7</sup>

Three days after envenomation, the wound will expand and deepen, with skin breakdown noted not sooner than 72 hours after the bite (see Figure 2, next page).<sup>7,8</sup> After five to seven days, the cutaneous lesion forms a dry necrotic eschar with a well-demarcated border. Within two to three weeks after the bite, the necrotic tissue should detach, and the wound should develop granulated tissue that indicates healing.<sup>8</sup> Complete healing can take weeks or months, depending on the extent and depth of the wound, with scarring possible in severe cases.<sup>7</sup>

Severe systemic illness (ie, systemic loxoscelism)—rare in the US—is a potential complication of the brown recluse spider

**FIGURE 2**  
**Bite of the Brown Recluse Spider**



The site may become pale, erythematous, and swollen.

Necrosis (left) may manifest as a dark, leathery eschar or an ulceration.

Credits: Top, Francesco Tomasinelli/Science Source; left, used with permission from *Cutis* (2002;69[2]:91-95).

bite.<sup>4</sup> It manifests with fever, malaise, vomiting, headache, and rash; in rare instances, it results in death.<sup>7</sup>

### DIAGNOSIS

Brown recluse bite is diagnosed based on history and clinical presentation and, when possible, identification of the spider. However, patients often do not realize they have been bitten before they develop symptoms, making it impossible to confirm the etiology of the lesion. It is often helpful to ask the following questions during the assessment

- Did you feel the bite take place?
- Did you see or capture the spider? If so, can you describe it?
- Where were you when the spider bit you?
- Did you recently clean any clutter or debris?

Furthermore, patients who recall seeing a spider after being bitten typically do not

bring the arachnid to their health care facility. Another complicating factor is the numerous possible causes of necrotic skin lesions that can be mistaken for spider bites.<sup>5</sup> The differential diagnosis can include allergic dermatitis, cellulitis, methicillin-resistant *Staphylococcus aureus* (MRSA) infection, skin abscesses, other arthropod bites, necrotizing fasciitis, or bee sting.

### TREATMENT AND MANAGEMENT

One of the most important factors in successful treatment is timeliness of medical attention after the initial bite; because the most damaging tissue effects occur within the first three to six hours after envenomation, intervention during this time is imperative.<sup>8</sup> Initial treatment of cutaneous brown recluse spider bite is often conservative, given the variation in clinical presentation, inability to predict the future extent of lesions, and lack of evidence-based treatment options.<sup>9</sup> The goals of therapy are to ensure that skin integrity is maintained, infection is avoided, and circulation is preserved.<sup>10</sup>

**Nonpharmacologic treatments** for brown recluse spider bite consist of cleaning the wound, treating the bite area with “RICE” (rest-ice-compression-elevation) therapy during the first 72 hours to reduce tissue damage, and ensuring adequate hydration.<sup>1,10-13</sup> The affected area should be cleaned thoroughly; infected wounds require topical antiseptics and sterile dressings. Applying a cold compress to the bite area at 20-minute intervals during the first 72 hours after envenomation has been shown to reduce tissue damage.<sup>10</sup> Heat should not be applied to the area, as it may increase tissue damage.

**Pharmacologic treatment.** Patients who experience systemic symptoms such as nausea, vomiting, pain, fever, and pruritus should be provided antipyretics, hydration, and analgesics for symptomatic relief, as needed.<sup>9</sup> Antihistamines and benzodiazepines have been found to be useful in relieving symptoms of anxiety and pruritus. To help manage mild pain, OTC NSAIDs are recommended.<sup>10</sup>

continued on page 24 >>

&gt;&gt; continued from page 22

If the date of the last tetanus shot is unknown, a prophylactic tetanus booster (tetanus/diphtheria [Td] or Tdap) should be administered.<sup>10</sup> The prophylactic use of cephalosporins to treat infection is indicated in patients with tissue breakdown.<sup>1</sup>

Among the more controversial treatment choices are use of corticosteroids and dapsone, prescribed frequently in the past. Use of oral corticosteroids for cutaneous forms of spider bite is not supported by current evidence.<sup>5,10,14</sup> Research does, however, support their role in the treatment of bite-induced systemic illness, particularly for preventing kidney failure and hemolysis in children.<sup>1,15</sup>

Dapsone, prescribed for the necrotic lesions, may be useful in limiting the inflammatory response at the site of envenomation.<sup>1,3</sup> However, human studies have shown conflicting results with dapsone administration, with some demonstrating

referring to a wound care clinic for surgical excision of the eschar.<sup>9</sup>

To avoid future spider bites, advise patients to clear all clutter, move beds away from the wall, remove bed skirts or ruffles, avoid using underbed storage containers, avoid leaving clothing on the floor in piles, and check shoes before dressing.<sup>5</sup>

## OUTCOME FOR THE CASE PATIENT

Initial supportive treatment for this patient included cleaning the bite area with antiseptic soap and water. A cold compress was applied to the bite area at 20-minute intervals, and the right hand was elevated. Hydrocodone bitartrate/acetaminophen (5/325 mg qid) was administered to alleviate pain. The patient was also given a tetanus booster because the date of his last immunization was unknown.

After two hours of monitoring, the patient was no longer able to move his hand, swelling around the affected area increased, and the bite site began to appear necrotic. Cephalexin (500 mg bid) was ordered along with dapsone (100 mg/d). The patient was referred for consultation with wound care and infectious disease specialists because of possible tissue necrosis.

## CONCLUSION

Brown recluse spider bites are uncommon, and most are unremarkable and self-healing. Patients who present following a brown recluse bite typically can be managed successfully with supportive care (RICE) and careful observation. In rare cases, however, bites may result in significant tissue necrosis or even death.

The diagnosis is typically based on thorough physical examination, with attention to the lesion characteristics and appropriate questions about the spider and the development of the lesion over time. Diagnosis through identification of the spider seldom occurs, since patients typically do not capture the spider and bring it with them for identification. The geographic region where the bite occurs is an important factor as well, since brown recluse envenomation is higher on the differential

## ► One of the most important factors in successful treatment is timeliness of medical attention after the initial bite.

no improvement in patient outcomes.<sup>8</sup> The risks of dapsone's many adverse effects, including dose-related hemolysis, sore throat, pallor, agranulocytosis, aplastic anemia, and cholestatic jaundice, may outweigh its benefits.<sup>1,12</sup> Furthermore, dapsone treatment is restricted in patients with G6PD (glucose-6-phosphate dehydrogenase) deficiency because of their increased risk for hemolytic anemia.<sup>1</sup> Accordingly, dapsone is recommended only for moderate-to-severe or rapidly progressing cases in adults.<sup>1</sup>

## FOLLOW-UP CARE

A patient's follow-up care should be assessed individually, based on the nature of his/her reaction to the bite. In all instances, however, ask the patient to report worsening of symptoms and changes in the skin around the bite area; if systemic symptoms develop, patients should proceed to the ED. If, after six to eight weeks, the necrotic lesion is large and has stabilized in size, consider

diagnosis of necrotic skin lesions in areas where these spiders are endemic (the lower Midwest, south central, and southeastern regions of the US). **CR**

## REFERENCES

1. Andersen RJ, Campoli J, Johar SK, et al. Suspected brown recluse envenomation: a case report and review of different treatment modalities. *J Emerg Med.* 2011;41(2):e31-e37.
2. Vetter RS. Seasonality of brown recluse spiders, *Loxosceles reclusa*, submitted by the general public: implications for physicians regarding loxoscelism diagnoses. *Toxicon.* 2011;58(8):623-625.
3. Forks TP. Brown recluse spider bites. *J Am Board Fam Pract.* 2000;13(6):415-423.
4. Peterson ME. Brown spider envenomation. *Clin Tech Small Anim Pract.* 2006;21(4):191-193.
5. Vetter RS, Isbister GK. Medical aspects of spider bites. *Ann Rev Entomol.* 2008;53:409-429.
6. Szalay J. Brown recluse spiders: facts, bites & symptoms (2014). [www.livescience.com/39996-brown-recluse-spiders.html](http://www.livescience.com/39996-brown-recluse-spiders.html). Accessed March 1, 2017.
7. Isbister GK, Fan HW. Spider bite. *Lancet.* 2011;378:2039-2047.
8. Hogan CJ, Barbaro KC, Winkel K. Loxoscelism: old obstacles, new directions. *Ann Emerg Med.* 2000;44:608-624.
9. Bernstein B, Ehrlich F. Brown recluse spider bites. *J Emerg Med.* 1986;4:457-462.
10. Rhoads J. Epidemiology of the brown recluse spider bite. *J Am Acad Nurse Pract.* 2007;19(2):79-85.
11. Carlson DS. Spider bite. *Nursing.* 2013;43(2):72.
12. Frundle TC. Management of spider bites. *Air Med J.* 2004;23(4):24-26.
13. Sams HH, King LE Jr. Brown recluse spider bites. *Dermatol Nurs.* 1999;11(6):427-433.
14. Nunnelee JD. Brown recluse spider bites: a case report. *J Perianesth Nurs.* 2006;21(1):12-15.
15. Wendell RP. Brown recluse spiders: a review to help guide physicians in nonendemic areas. *South Med J.* 2003;96(5):486-490.