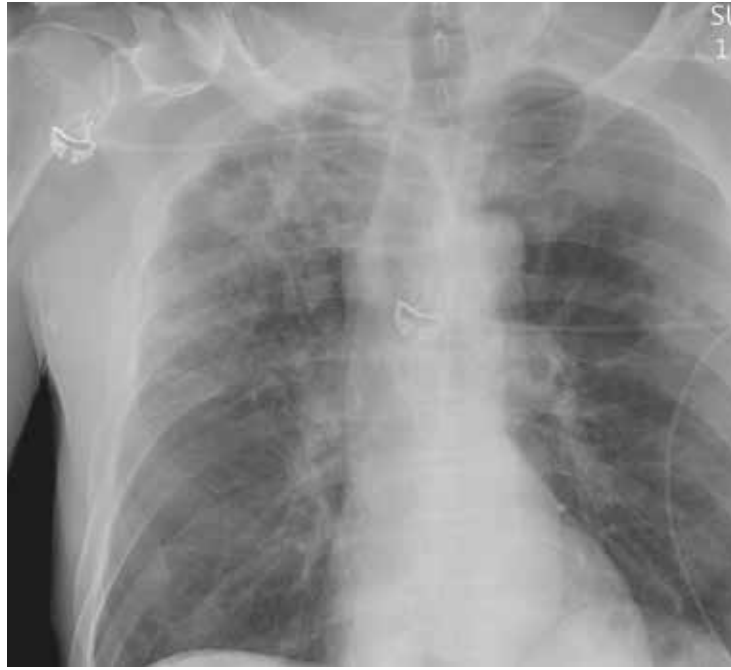


# The Man With No Medical History

**F**ollowing a motor vehicle collision, a 60-year-old man is brought to the emergency department via ambulance. He was an unrestrained front-seat passenger in a vehicle that lost control on the roadway and went into a ditch. The patient complains of headache, chest wall pain, and left arm pain. He does not believe he lost consciousness.

He denies any medical history and adds that he does not seek regular medical treatment. He admits to tobacco use and frequent alcohol use.

On physical exam, you note an elderly-appearing male in no obvious distress with a Glasgow Coma Scale score of 15. His vital signs are all within normal limits. Other than slight swelling on the left side of his head, tenderness in the anterior chest wall,



and pain in his left humerus, his exam is normal.

You order trauma lab tests and appropriate radiographic studies; a portable chest radiograph is completed (shown). What is your impression?

continued on page 29 >>



**Nandan R. Hichkad,** PA-C, MMSc, practices at the Georgia Neurosurgical Institute in Macon and is a clinical instructor at the Mercer University School of Medicine, Macon.

>> continued from page 9

### ANSWER

The radiograph demonstrates no acute fractures or pneumothorax. Of note is a right upper lobe infiltrate, within which is a rounded cavitory lesion measuring approximately 4 cm. The differential includes pulmonary malignancy, active or previous pulmonary infection (eg, tuberculosis), or pneumatocele. Further evaluation with CT and a pulmonary consultation was coordinated. **CR**

