

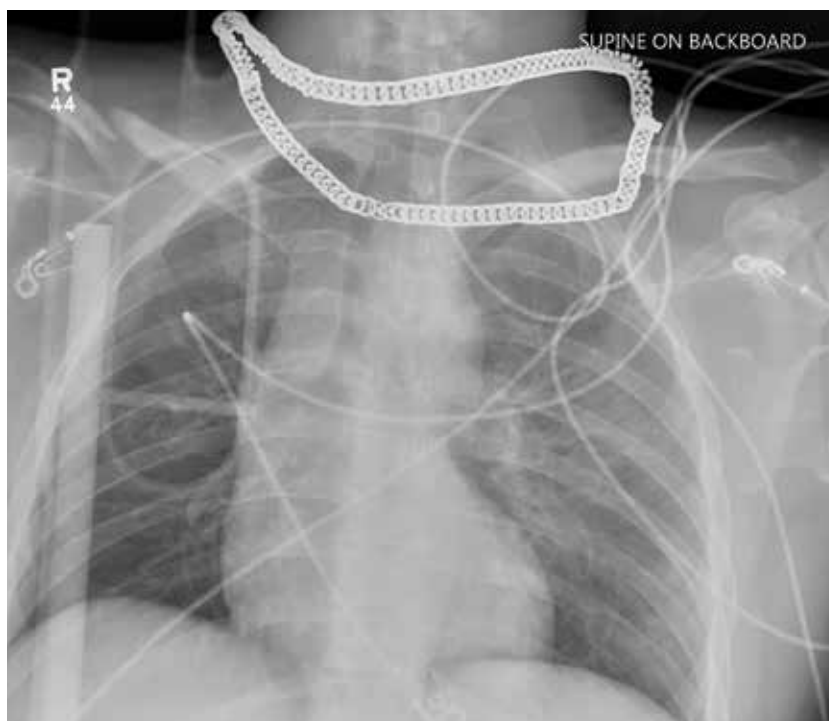
Cross at the Green, Not in Between

Nandan R. Hichkad, PA-C, MMSc

A 25-year-old man is brought to your facility by EMS transport following an accident while riding a bicycle. Witnesses say he was hit by a car when he suddenly tried to cross a busy intersection. They also report that he was not wearing a helmet and that he was thrown off the bike, landing several feet away.

Initial survey reveals a male who is arousable but nonverbal, just moaning and groaning. There are obvious deformities in both lower extremities and the right upper extremity. The patient's blood pressure is 100/50 mm Hg and his heart rate, 130 beats/min. Pulse oximetry shows his O₂ saturation to be 95% with 100% oxygen via nonrebreather mask. His pupils are equal and reactive bilaterally. Heart and lungs sound clear. Abdomen is soft.

While you continue examining the patient and begin your secondary survey, a portable chest radiograph is obtained (shown). What is your impression?



Nandan R. Hichkad, PA-C, MMSc, practices at the Georgia Neurosurgical Institute in Macon and is a clinical instructor at the Mercer University School of Medicine, Macon.

ANSWER

Aside from the usual artifacts from placement on a backboard and from the presence of monitoring devices and wires, the radiograph shows a displaced fracture of the right clavicle. No other significant abnormalities are present.

The patient was ultimately diagnosed with multiple orthopedic injuries, and orthopedics was called to evaluate and manage accordingly. **CR**

