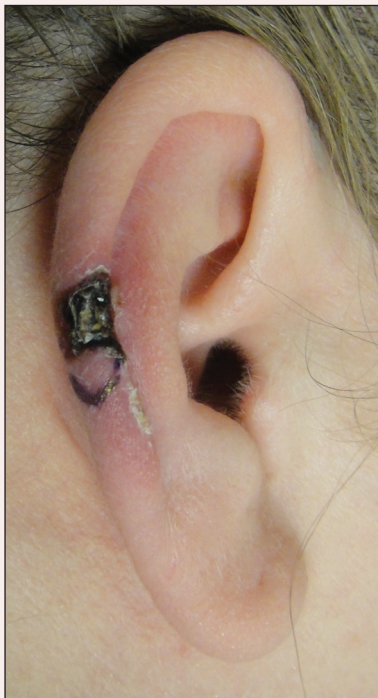

Necrotic Lesion of the Ear

Elaine Kunzler, BS; Joshua Weaver, MD; Christina Cernik, MD

Eligible for 1 MOC SA Credit From the ABD

This Photo Challenge in our print edition is eligible for 1 self-assessment credit for Maintenance of Certification from the American Board of Dermatology (ABD). After completing this activity, diplomates can visit the ABD website (<http://www.abderm.org>) to self-report the credits under the activity title "Cutis Photo Challenge." You may report the credit after each activity is completed or after accumulating multiple credits.



A 43-year-old woman presented with a painful necrotic lesion on the right ear of 1 month's duration. She denied trauma to the ear and had no other skin lesions elsewhere on the body. A course of doxycycline prior to presentation did not result in improvement. Her medical history was remarkable for diabetes mellitus, deep vein thrombosis, depression, and gastroesophageal reflux disease. She had been taking warfarin regularly for years. She denied using recreational drugs. On physical examination, the right ear demonstrated a 6-mm necrotic area with surrounding tender erythema. Examinations of the left ear, face, and legs were normal. An excisional biopsy was performed.

What's the diagnosis?

- actinic keratosis
- basal cell carcinoma
- chondrodermatitis nodularis chronica helioides
- squamous cell carcinoma
- weathering nodules

PLEASE TURN TO PAGE 301 FOR PHOTO CHALLENGE DISCUSSION

Ms. Kunzler is from Northeast Ohio Medical University, Rootstown. Drs. Weaver and Cernik are from Summa Akron City Hospital, Ohio. The authors report no conflict of interest.
Correspondence: Elaine Kunzler, BS, 1677 Fixler Rd, Wadsworth, OH 44281 (ekunzler@neomed.edu).

The Diagnosis: Chondrodermatitis Nodularis Chronica Helicis

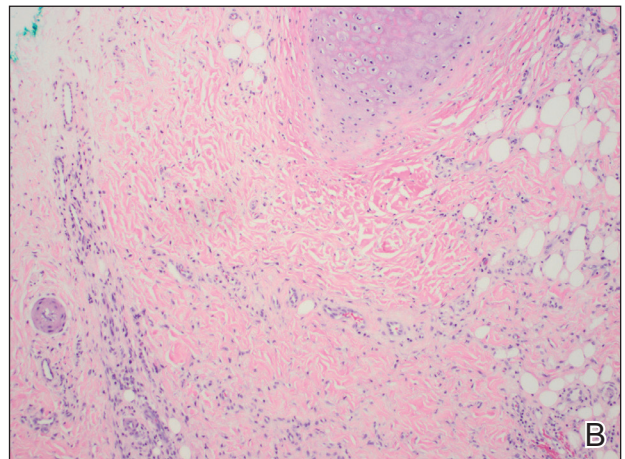
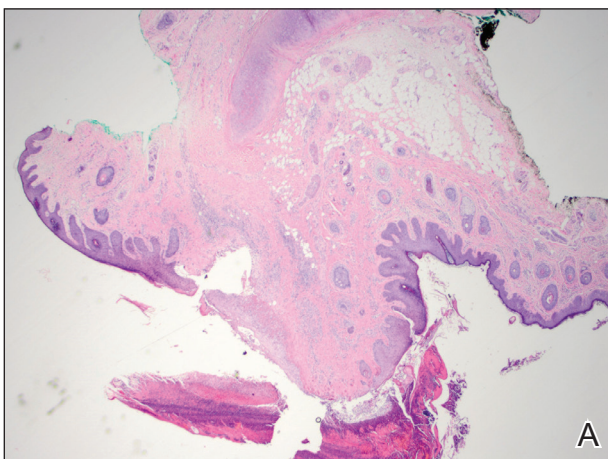
Histopathologic examination revealed focal epidermal erosion and ulceration directly overlying the hyaline cartilage with degenerative changes (Figure). The dermis was relatively noninflamed with fibroplasia of the vasculature. The blood vessels indirectly beneath the ulceration were found to be unremarkable with no indications of fibrinoid necrosis, vasculitis, or the presence of thrombi. The patient was informed of the diagnosis, at which point she reported that she slept on the right side. The excisional biopsy site healed well without recurrence of chondrodermatitis nodularis chronica helicis (CNH).

Chondrodermatitis nodularis chronica helicis, also known as clavus helicis, is a benign, usually solitary, painful lesion. Historically, it was first described in 1915 by Winkler¹ and in the 1960s the most common documented cases were attributed to the headpieces of telephone operators and nuns.² In the early 2000s, cell phones were determined to be a growing cause.³ Chondrodermatitis nodularis chronica helicis is most commonly found on the helix with the antihelix being affected less often.⁴ The condition is more common in men, with a male to female ratio being reported as high as 10:1. Possible causes of this disorder stem from damage to cartilage associated with pressure, sun exposure, cold temperatures,

and microvascular disease. Additionally, some researchers have hypothesized that the cartilaginous damage resulting from solar elastosis and minor trauma leaves a susceptibility to CNH. This disorder usually presents as a small, exquisitely tender nodule that may ulcerate and crust.⁴ Chondrodermatitis nodularis chronica helicis may be mistaken for basal cell carcinoma, squamous cell carcinoma, actinic keratosis, and weathering nodules, though CNH tends to be more painful.

The diagnosis of CNH often is clinical but may require a skin biopsy. Histopathology of CNH shows a benign inflammatory lesion with an acanthotic hyperkeratotic epidermis that may be ulcerated. A primarily lymphocytic infiltrate usually is observed with variable presence of histiocytes and neutrophils. Cartilaginous changes range from simple perichondral thickening to notable areas of degeneration with calcification and ossification.⁴

Although the diagnosis of CNH often is straightforward, the remarkable necrosis present in our case made for an interesting differential diagnosis. Pernio, cryoglobulinemia, and levamisole-induced vasculopathy were all considered. Pernio, caused by cold-induced vasoconstriction and hypoxemia, classically presents as erythematous lesions with a symmetrical distribution on acral



Excisional biopsy specimen of the necrotic area of the right helix (A and B)(H&E, original magnifications $\times 20$ and $\times 100$). Sections demonstrated focal epidermal erosion and ulceration directly overlying hyalinized cartilage with degenerative changes. The dermis was relatively noninflamed with angiofibroplasia. The blood vessels not directly beneath the ulceration were unremarkable.

sites.⁵ Cryoglobulinemia involves proteins that precipitate at cold temperatures causing damage via an occlusive vasculopathy or an immune complex-mediated vasculitis. The presence of cryoglobulinemia is strongly associated with concomitant hepatitis C virus infection.⁶ Ulcerated and purpuric lesions of cryoglobulinemia may become necrotic. Levamisole is a veterinary antihelminthic drug and common cocaine contaminant, often added to cocaine as a cutting agent. Levamisole-induced vasculopathy favors acral sites and often is noted on the ears as purpuric patches, sometimes with necrosis.⁷

Several therapies for CNH have been reported with variable effectiveness.⁸ First-line treatments are the use of pressure-relieving devices including a doughnut-shaped pillow during sleep and intralesional corticosteroids.⁹ Surgical treatments including cryotherapy, simple excision, electrodesiccation and curettage, wedge resection with helical rim advancement flap, punch and graft technique, and CO₂ laser have been tried.⁸ Photodynamic therapy and topical nitroglycerine also have shown to be of benefit.^{8,9}

Our case of CNH is unique because of the remarkable degree of necrosis present on clinical examination. Chondrodermatitis nodularis chronica helioides with such an impressive necrotic presentation is rare. We speculate that the patient's underlying hypercoagulable state may have contributed to the dramatic presentation. It is important to keep

CNH in mind when evaluating any necrotic lesion on the ear.

REFERENCES

1. Winkler M. Knötchenförmige Erkrankung am helix. chondrodermatitis nodularis chronica helioides. *Arch für Dermatologie und Syphilis*. 1915;121:278-285.
2. Barker L, Young AW, Sachs W. Chondrodermatitis of the ears: a differential study of nodules of the helix and antihelix. *Arch Dermatol*. 1960;81:15-25.
3. Elgart M. Cell phone chondrodermatitis. *Arch Dermatol*. 2000;136:1568.
4. Cribier B, Scrivener Y, Peltre B. Neural hyperplasia in chondrodermatitis nodularis chronica helioides. *J Am Acad Dermatol*. 2006;55:844-848.
5. King JM, Plotner AN, Adams BB. Perniosis induced by a cold-therapy system. *Arch Dermatol*. 2012;148:1101-1102.
6. Berk DR, Mallory SB, Keeffe EB, et al. Dermatologic disorders associated with chronic hepatitis C: effect of interferon therapy. *Clin Gastroenterol Hepatol*. 2007;5:142-151.
7. Hennings C, Miller J. Illicit drugs: what dermatologists need to know. *J Am Acad Dermatol*. 2013;69:135-142.
8. Flynn V, Chisholm C, Grimwood R. Topical nitroglycerin: a promising treatment option for chondrodermatitis nodularis helioides. *J Am Acad Dermatol*. 2011;64:531-536.
9. Gilaberte Y, Frias M, Pérez-Lorenz J. Chondrodermatitis nodularis helioides successfully treated with photodynamic therapy. *Arch Dermatol*. 2010;146:1080-1082.