

Current Concepts in Lip Augmentation

Gabrielle N. Mannino, MD; Shari R. Lipner, MD, PhD

PRACTICE POINTS

- Hyaluronic acid (HA) fillers are approved by the US Food and Drug Administration for lip augmentation and/or treatment of perioral rhytides in adults 21 years and older.
- Most complications encountered with HA lip augmentation are mild and transient and can include injection-site reactions such as pain, erythema, and edema.
- Combination treatment with dermal fillers and neurotoxins (off label) may demonstrate effects that last longer than either modality alone without additional adverse events.

Facial rejuvenation, particularly lip augmentation, has gained widespread popularity. An appreciation of perioral anatomy as well as the structural characteristics that define the aging face is critical to achieve optimal patient outcomes. Although techniques and technology evolve continuously, hyaluronic acid (HA) dermal fillers continue to dominate aesthetic practice. A combination approach including neurotoxin and volume restoration demonstrates superior results in select settings.

Cutis. 2016;98:325-329.

Historically, a variety of tools have been used to alter one's appearance for cultural or religious purposes or to conform to standards of beauty. As a defining feature of the face, the lips provide a unique opportunity for facial aesthetic enhancement. There has been a paradigm shift in medicine favoring preventative health and a desire to slow and even reverse the aging process.¹ Acknowledging that product technology, skill sets, and cultural ideals continually evolve, this article highlights perioral anatomy, explains aging of the

lower face, and reviews techniques to achieve perioral rejuvenation through volume restoration and muscle control.

Perioral Anatomy

The layers of the lips include the epidermis, subcutaneous tissue, orbicularis oris muscle fibers, and mucosa. The upper lip extends from the base of the nose to the mucosa inferiorly and to the nasolabial folds laterally. The curvilinear lower lip extends from the mucosa to the mandible inferiorly and to the oral commissures laterally.² Circumferential at the vermilion-cutaneous junction, a raised area of pale skin known as the white roll accentuates the vermilion border and provides an important landmark during lip augmentation.³ At the upper lip, this elevation of the vermilion joins at a V-shaped depression centrally to form the Cupid's bow. The cutaneous upper lip has 2 raised vertical pillars known as the philtral columns, which are formed from decussating fibers of the orbicularis oris muscle.² The resultant midline depression is the philtrum. These defining features of the upper lip are to be preserved during augmentation procedures (Figure 1).⁴

The superior and inferior labial arteries, both branches of the facial artery, supply the upper and lower lip, respectively. The anastomotic arch of the superior labial artery is susceptible to injury from deep injection of the upper lip between the muscle layer and mucosa; therefore, caution must be exercised in this area.⁵ Injections into the vermilion and

From Weill Cornell Medical College, New York, New York.

The authors report no conflict of interest.

Correspondence: Shari R. Lipner MD, PhD, Department of Dermatology, Weill Cornell Medical College, 1305 York Ave, New York, NY 10021 (shl9032@med.cornell.edu).

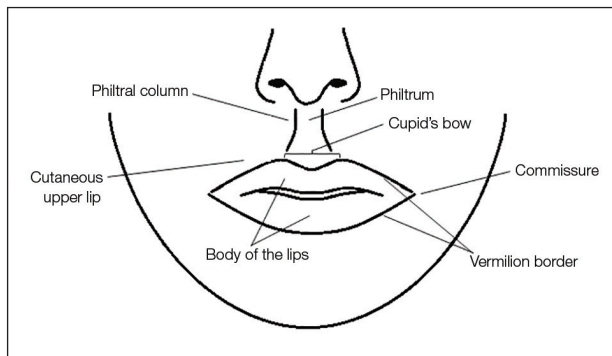


Figure 1. A diagram of the perioral anatomy.

lower lip can be safely performed with less concern for vascular compromise. The vermilion derives its red color from the translucency of capillaries in the superficial papillae.² The capillary plexus at the papillae and rich sensory nerve network render the lip a highly vascular and sensitive structure.

Aging of the Lower Face

Subcutaneous fat atrophy, loss of elasticity, gravitational forces, and remodeling of the skeletal foundation all contribute to aging of the lower face. Starting as early as the third decade of life, intrinsic factors including hormonal changes and genetically determined processes produce alterations in skin quality and structure. Similarly, extrinsic aging through environmental influences, namely exposure to UV radiation and smoking, accelerate the loss of skin integrity.⁶

The decreased laxity of the skin in combination with repeated contraction of the orbicularis oris muscle results in perioral rhytides.⁷ For women in particular, vertically oriented perioral rhytides develop above the vermilion; terminal hair follicles, thicker skin, and a greater density of subcutaneous fat are presumptive protective factors for males.⁸ With time, the cutaneous portion of the upper lip lengthens and there is redistribution of volume with effacement of the upper lip vermilion.⁹ Additionally, the demarcation of the vermilion becomes blurred secondary to pallor, flattening of the philtral columns, and loss of projection of the Cupid's bow.¹⁰

Downturning of the oral commissures is observed secondary to a combination of gravity, bone resorption, and soft tissue volume loss. Hyperactivity of the depressor anguli oris muscle exacerbates the mesolabial folds, producing marionette lines and a saddened expression.⁷ With ongoing volume loss and ligament laxity, tissue redistributes near the jaws and chin, giving rise to jowls. Similarly, perioral volume loss and descent of the malar fat-pad deepen the nasolabial folds in the aging midface.⁶

The main objective of perioral rejuvenation is to reinstate a harmonious refreshed look to the lower face; however, aesthetic analysis should occur within the context of the face as a whole, as the lips should complement the surrounding perioral cosmetic unit and overall skeletal foundation of the face. To accomplish this goal, the dermatologist's armamentarium contains a broad variety of approaches including restriction of muscle movement, volume restoration, and surface contouring.

Volume Restoration

Treatment Options—In 2015, hyaluronic acid (HA) fillers constituted 80% of all injectable soft-tissue fillers, an 8% increase from 2014.¹¹ Hyaluronic acid has achieved immense popularity as a temporary dermal filler given its biocompatibility, longevity, and reversibility via hyaluronidase.¹²

Hyaluronic acid is a naturally occurring glycosaminoglycan that comprises the connective tissue matrix. The molecular composition affords HA its hydrophilic property, which augments dermal volume.⁷ Endogenous HA has a short half-life, and chemical modification by a cross-linking process extends longevity by 6 to 12 months. The various HA fillers are distinguished by method of purification, size of molecules, concentration and degree of cross-linking, and viscosity.^{7,13,14} These differences dictate overall clinical performance such as flow properties, longevity, and stability. As a general rule, a high-viscosity product is more appropriate for deeper augmentation; fillers with low viscosity are more appropriate for correction of shallow defects.¹ Table 1 lists the HA fillers that are currently approved by the US Food and Drug Administration for lip augmentation and/or perioral rhytides in adults 21 years and older.¹⁵⁻¹⁷

Randomized controlled trials comparing the efficacy, longevity, and tolerability of different HA products are lacking in the literature and, where present, have strong industry influence.^{18,19} The advent of assessment scales has provided an objective evaluation of perioral and lip augmentation, facilitating comparisons between products in both clinical research and practice.²⁰

Semipermanent biostimulatory dermal fillers such as calcium hydroxylapatite and poly-L-lactic acid are not recommended for lip augmentation due to an increased incidence of submucosal nodule formation.^{6,14,21} Likewise, permanent fillers are not recommended given their irreversibility and risk of nodule formation around the lips.^{14,22} Nonetheless, liquid silicone (purified polydimethylsiloxane) administered via a microdroplet technique (0.01 mL of silicone at a time, no more than 1 cc per lip per session) has

Table 1.

HA Fillers FDA Approved for Lip Augmentation and/or Perioral Rhytides in Adults

Product (Manufacturer)	Approval Date	Material	Indication(s)
Belotero Balance (Merz Aesthetics)	2011	22.5 mg/mL HA	Perioral rhytides
Juvéderm Ultra XC (Allergan, Inc)	2015	24 mg/mL HA, lidocaine 0.3%	Lip augmentation, perioral rhytides
Juvéderm Volbella XC ^{15,16} (Allergan, Inc)	2016	15 mg/mL HA, lidocaine 0.3%	Lip augmentation, perioral rhytides
Restylane (Galderma Laboratories, LP)	2011	20 mg/mL HA	Lip augmentation, perioral rhytides
Restylane-L (Galderma Laboratories, LP)	2012	20 mg/mL HA, lidocaine 0.3%	Lip augmentation, perioral rhytides
Restylane Silk (Galderma Laboratories, LP)	2014	20 mg/mL HA, lidocaine 0.3%	Lip augmentation, perioral rhytides

Abbreviations: HA, hyaluronic acid; FDA, US Food and Drug Administration.

been used off label as a permanent filling agent for lip augmentation with limited complications.²³ Regardless, trepidations about its use with respect to reported risks continue to limit its application.²²

Similarly, surgical lip implants such as expanded polytetrafluoroethylene is an option for a subset of patients desiring permanent enhancement but are less commonly utilized given the side-effect profile, irreversibility, and relatively invasive nature of the procedure.²² Lastly, autologous fat transfer has been used in correction of the nasolabial and mesolabial folds as well as in lip augmentation; however, irregular surface contours and unpredictable longevity secondary to postinjection resorption (20%–90%) has limited its popularity.^{3,14,21}

HA Injection Technique—With respect to HA fillers in the perioral area, numerous approaches have been described.^{10,22} The techniques in Table 2 provide a foundation for lip rejuvenation.

Several injection techniques exist, including serial puncture, linear threading, cross-hatching, and fanning in a retrograde or anterograde manner.²⁴ A blunt microcannula (27 gauge, 38 mm) may be used in place of sharp needles and offers the benefit of increased patient comfort, reduced edema and ecchymosis, and shortened recovery period.^{25,26} Gentle massage of the product after injection can assist with an even contour. Lastly, a key determinant of successful outcomes

is using an adequate volume of HA filler (1–2 mL for shaping the vermilion border and volumizing the lips).²⁷ Figure 2 highlights a clinical example of HA filler for lip augmentation.

Fortunately, most complications encountered with HA lip augmentation are mild and transient. The most commonly observed side effects include injection-site reactions such as pain, erythema, and edema. Similarly, most adverse effects are related to injection technique. All HA fillers are prone to the Tyndall effect, a consequence of too superficial an injection plane. Patients with history of recurrent herpes simplex virus infections should receive prophylactic antiviral therapy.¹²

Muscle Control

An emerging concept in rejuvenation of the lower face recognizes not only restoration of volume but also control of muscle movement. Local injection of botulinum toxin type A induces relaxation of hyperfunctional facial muscles through temporary inhibition of neurotransmitter release.⁶ The potential for paralysis of the oral cavity may limit the application of botulinum toxin type A in that region.⁷ Nonetheless, the off-label potential of botulinum toxin type A has expanded to include several targets in the lower face. The orbicularis oris muscle is targeted to soften perioral rhytides. Conservative dosing (1–2 U per lip quadrant or approximately 5 U total) and superficial injection is emphasized in

Table 2.

Injection Techniques for Lip Augmentation

Targeted Treatment Area	Technique
Body of lips	Injection at wet-dry line; preserve natural lip protuberances (3 tubercles on upper lip, 2 tubercles on lower lip) ²² ; ideal vertical height ratio of upper lip to lower lip is 1:1.6 in white individuals ⁹ ; ideal projection of upper lip to lower lip ratio on lateral view is 1.6:1 in white individuals ⁹
Oral commissures	Inject at lateral aspect of lower lip to uplift and support
Perioral rhytides	Vertical injection, parallel to rhytides; superficial application of a less viscous filler
Philtral columns	Inject in intradermal plane; injection at upper cutaneous lip, maintaining triangular shape of column with apex at the nostril
Vermilion border and Cupid's bow	Inject along vermilion-cutaneous junction; avoid overcorrection, which would eliminate the Cupid's bow and create a "sausage or duck lip" appearance; stretch lip adequately to allow uniform flow

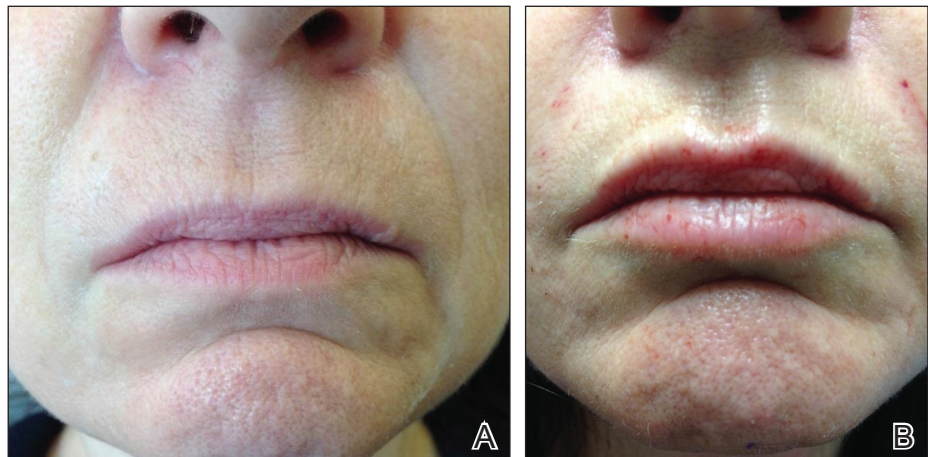

Figure 2. A 51-year-old woman who presented for lip augmentation before (A) and immediately after injection of 0.3 mL of a hyaluronic acid filler into the lip body and vermilion (B).

this area.²⁷ Similarly, the depressor anguli oris muscle is targeted by injection of 4 U bilaterally to soften the marionette lines. In the chin area, the mentalis muscle can be targeted by injection of 2 U deep into each belly of the muscle to reduce the mental crease and dimpling.²⁸ Combination treatment with dermal filler and neurotoxin demonstrates effects that last longer than either modality alone without additional adverse events.²⁹ With combination therapy, guidelines suggest treating with filler first.²⁷

Conclusion

A greater understanding of the extrinsic and intrinsic factors that contribute to the structural and

surface changes of the aging face coupled with a preference for minimally invasive procedures has revolutionized the dermatologist's approach to perioral rejuvenation. Serving as a focal point of the face, the lips and perioral skin are well poised to benefit from this paradigm shift. A multifaceted approach utilizing dermal fillers and neurotoxins may be most appropriate and has demonstrated optimal outcomes in facial aesthetics.

REFERENCES

1. Buck DW, Alam M, Kim JYS. Injectable fillers for facial rejuvenation: a review. *J Plast Reconstr Aesthet Surg.* 2009;62:11-18.

2. Guareschi M, Stella E. Lips. In: Goisis M, ed. *Injections in Aesthetic Medicine*. Milan, Italy: Springer; 2014:125-136.
3. Byrne PJ, Hilger PA. Lip augmentation. *Facial Plast Surg*. 2004;20:31-38.
4. Niamtu J. Rejuvenation of the lip and perioral areas. In: Bell WH, Guerrero CA, eds. *Distraction Osteogenesis of the Facial Skeleton*. Ontario, Canada: BC Decker Inc; 2007:38-48.
5. Tansatit T, Apinuntrum P, Phetudom T. A typical pattern of the labial arteries with implication for lip augmentation with injectable fillers. *Aesthet Plast Surg*. 2014;38:1083-1089.
6. Sadick NS, Karcher C, Palmisano L. Cosmetic dermatology of the aging face. *Clin Dermatol*. 2009;27(suppl):S3-S12.
7. Ali MJ, Ende K, Mass CS. Perioral rejuvenation and lip augmentation. *Facial Plast Surg Clin N Am*. 2007;15:491-500.
8. Chien AL, Qi J, Cheng N, et al. Perioral wrinkles are associated with female gender, aging, and smoking: development of a gender-specific photonumeric scale. *J Am Acad Dermatol*. 2016;74:924-930.
9. Iblher N, Stark GB, Penna V. The aging perioral region—do we really know what is happening? *J Nutr Health Aging*. 2012;16:581-585.
10. Sarnoff DS, Gotkin RH. Six steps to the “perfect” lip. *J Drugs Dermatol*. 2012;11:1081-1088.
11. American Society of Plastic Surgeons. 2015 Cosmetic plastic surgery statistics. <https://d2wirczt3b6wjm.cloudfront.net/News/Statistics/2015/cosmetic-procedure-trends-2015.pdf>. Published February 26, 2015. Accessed October 5, 2016.
12. Abduljabbar MH, Basendwh MA. Complications of hyaluronic acid fillers and their managements. *J Dermatol Surg*. 2016;20:1-7.
13. Luebberding S, Alexiades-Armenakas M. Facial volume augmentation in 2014: overview of different filler options. *J Drugs Dermatol*. 2013;12:1339-1344.
14. Huang Attenello N, Mass CS. Injectable fillers: review of material and properties. *Facial Plast Surg*. 2015;31:29-34.
15. Eccleston D, Murphy DK. Juvéderm Volbella in the perioral area: a 12-month perspective, multicenter, open-label study. *Clin Cosmet Investig Dermatol*. 2012;5:167-172.
16. Raspaldo H, Chantrey J, Belhaouari L, et al. Lip and perioral enhancement: a 12-month prospective, randomized, controlled study. *J Drugs Dermatol*. 2015;14:1444-1452.
17. Soft tissue fillers approved by the center for devices and radiological health. US Food and Drug Administration website. <http://www.fda.gov/MedicalDevices/ProductsandMedicalProcedures/CosmeticDevices/WrinkleFillers/ucm227749.htm>. Updated July 27, 2015. Accessed October 5, 2016.
18. Butterwick K, Marmur E, Narurkar V, et al. HCY-24L demonstrates greater effectiveness with less pain than CPM-22.5 for treatment of perioral lines in a randomized controlled trial. *Dermatol Surg*. 2015;41:1351-1360.
19. San Miguel Moragas J, Reddy RR, Hernández Alfaro F, et al. Systematic review of “filling” procedures for lip augmentation regarding types of material, outcomes and complications. *J Craniomaxillofac Surg*. 2015;43:883-906.
20. Cohen JL, Thomas J, Paradkar D, et al. An interrater and intrarater reliability study of 3 photographic scales for the classification of perioral aesthetic features. *Dermatol Surg*. 2014;40:663-670.
21. Broder KW, Cohen SR. An overview of permanent and semipermanent fillers. *Plast Reconstr Surg*. 2006;118(3 suppl):7S-14S.
22. Sarnoff DS, Saini R, Gotkin RH. Comparison of filling agents for lip augmentation. *Aesthet Surg J*. 2008;28:556-563.
23. Moscona RA, Fodor L. A retrospective study on liquid injectable silicone for lip augmentation: long-term results and patient satisfaction. *J Plast Reconstr Aesthet Surg*. 2010;63:1694-1698.
24. Bertucci V, Lynde CB. Current concepts in the use of small-particle hyaluronic acid. *Plast Reconstr Surg*. 2015;136(5 suppl):132S-138S.
25. Wilson AJ, Taglienti AJ, Chang CS, et al. Current applications of facial volumization with fillers. *Plast Reconstr Surg*. 2016;137:E872-E889.
26. Dewandre L, Caperton C, Fulton J. Filler injections with the blunt-tip microcannula compared to the sharp hypodermic needle. *J Drugs Dermatol*. 2012;11:1098-1103.
27. Carruthers JD, Glogau RG, Blitzer A; Facial Aesthetics Consensus Group Faculty. Advances in facial rejuvenation: botulinum toxin type A, hyaluronic acid dermal fillers, and combination therapies-consensus recommendations. *Plast Reconstr Surg*. 2008;121(5 suppl):5S-30S.
28. Wu DC, Fabi SG, Goldman MP. Neurotoxins: current concepts in cosmetic use on the face and neck-lower face. *Plast Reconstr Surg*. 2015;136(5 suppl):76S-79S.
29. Carruthers A, Carruthers J, Monheit GD, et al. Multi-center, randomized, parallel-group study of the safety and effectiveness of onabotulinumtoxin A and hyaluronic acid dermal fillers (24-mg/mL smooth, cohesive gel) alone and in combination for lower facial rejuvenation. *Dermatol Surg*. 2010;36:2121-2134.