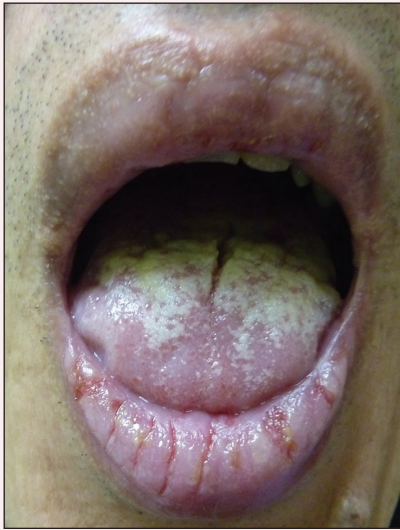

Painful Oral and Genital Ulcers

Chin Chwen Ch'ng, MBBS, MRCP, AdvMDerm; Su-Ming Wong, MBBCh BAO, MRCP, AdvMDerm; Yin Yin Lee, MD, MRCP, MMed, AdvMDerm



A 52-year-old man presented with persistent painful oral ulcers and penile and perianal erosions of 6 months' duration. He strongly denied engaging in high-risk sexual activities and had lost 10 kg over the last 6 months. He did not report taking any over-the-counter or alternative medications. On physical examination there were multiple fissures on the lower lip with erosive white plaques on the tongue and buccal mucosa. There were erosions over the foreskin and glans penis and a few erosive plaques on the perianal skin. Bilateral inguinal lymph nodes were enlarged.

What's the diagnosis?

- a. Behçet disease
- b. chancroid
- c. lymphogranuloma venereum
- d. oral and genital candidiasis
- e. pemphigus vegetans

From the Department of Medicine, Faculty of Medicine, University Malaya, Kuala Lumpur, Malaysia.

The authors report no conflict of interest.

Correspondence: Chin Chwen Ch'ng, MBBS, MRCP, AdvMDerm, Department of Medicine, Faculty of Medicine, University Malaya, Lembah Pantai, 50603 Kuala Lumpur, Malaysia (chinchwen@gmail.com).

The Diagnosis: Pemphigus Vegetans

Pemphigus vegetans is a rare variant of pemphigus vulgaris. Clinically, pemphigus vegetans is characterized by vegetative lesions over the flexures, but any area of the skin may be involved. There have been case reports involving the scalp,^{1,2} mouth,³ and foot.⁴ There are 2 clinical subtypes: the Neumann type and the Hallopeau type.⁵ The Hallopeau type is relatively benign, requires lower doses of systemic corticosteroids, and has a prolonged remission, while the Neumann type necessitates higher doses of systemic corticosteroids and often presents with relapses and remissions.

The diagnosis of pemphigus vegetans is based on clinical suspicion and confirmed by histological examination and immunological findings. The diagnosis may be difficult, as its presentation varies and histopathological findings may resemble other conditions.

Systemic corticosteroids are the well-established drug of choice for treating pemphigus vegetans to induce remission and maintain healing before cautiously tapering down the dosage approximately 50% every 2 weeks.⁶ Adjuvant drugs used in conjunction with steroids for steroid-sparing purpose include azathioprine, cyclophosphamide, mycophenolate mofetil, methotrexate, and cyclosporine.⁶ Pulsed intravenous steroids,⁷ intravenous immunoglobulins,⁸ pulsed dexamethasone cyclophosphamide,⁹

and extracorporeal photopheresis¹⁰ are given for severe and recalcitrant disease.

Laboratory investigations of our patient showed a normal complete blood cell count and a normal renal and liver profile. Herpes simplex virus serology was positive for type 1 and type 2 IgM and IgG. Urethral swab was dry and negative for gonorrhea. Serology for chlamydia, toxoplasma, amoebiasis, and leishmaniasis was negative. Human immunodeficiency virus serology, hepatitis screening, rapid plasma reagin, *Treponema pallidum* hemagglutination, rheumatoid factor, and antinuclear antibody all were negative. The patient was given a course of oral acyclovir 400 mg 3 times daily and empirical treatment with oral doxycycline 100 mg twice daily for a week with no clinical response.

Two biopsies from the perianal ulcers showed inflamed squamous papillomata with no Donovan bodies. A third biopsy from an intact blister showed acantholytic cells in the suprabasal bullae with eosinophilic and lymphocytic infiltrates at the upper dermis. Direct immunofluorescence demonstrated intercellular C3 and IgG deposits.

The patient was started on oral prednisolone at 1 mg/kg daily and oral azathioprine 50 mg daily with resolution of the perianal, penile, and oral ulcers (Figures 1 and 2). He achieved good

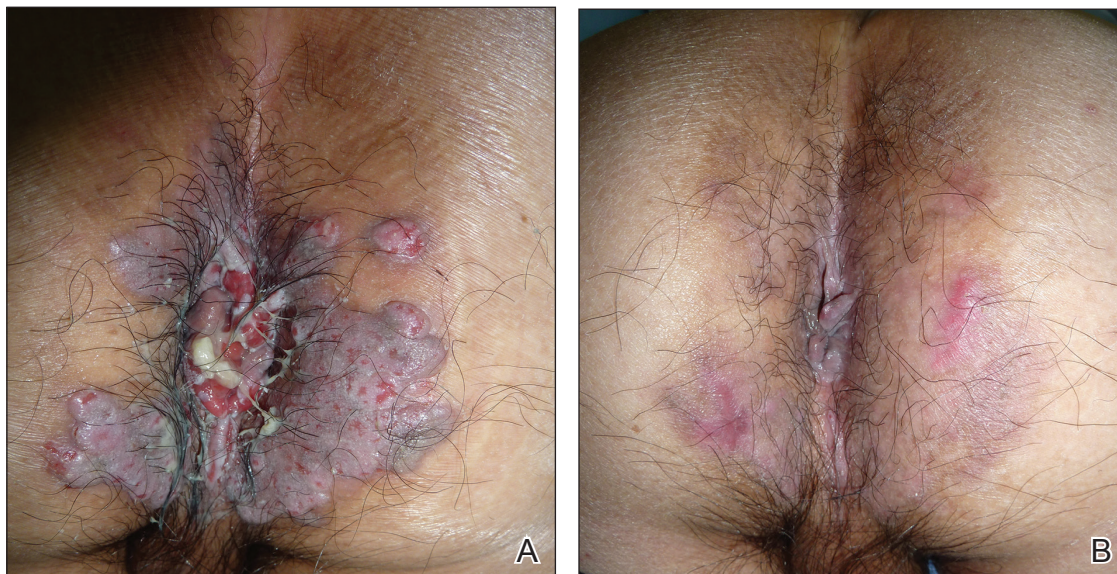


Figure 1. Weepy erosive plaques on perianal skin before (A) and after initiation of oral prednisolone and oral azathioprine (B). Residual hypertrophic scarring and postinflammatory hyperpigmentation were present 1 month after treatment.

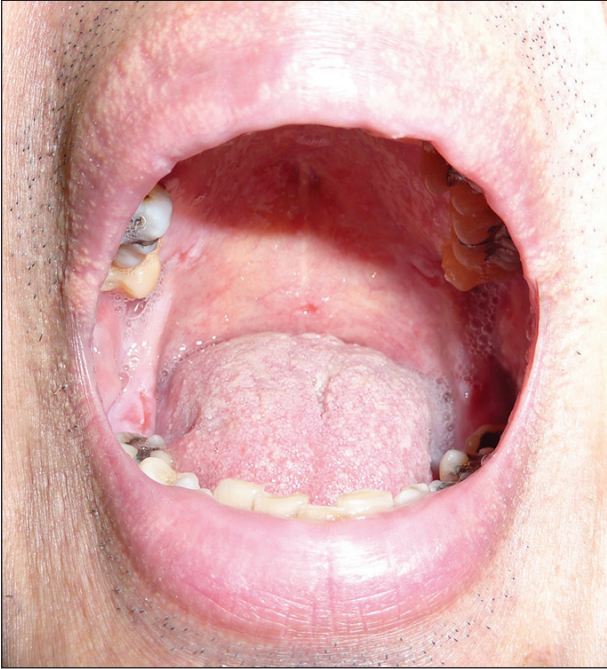

Figure 2. Minimal buccal and palatal erosion 1 month after initiation of oral prednisolone and oral azathioprine.

suppression of further eruption. At the patient's most recent follow-up (2.5 years after the initial presentation), he was in remission and was currently taking oral azathioprine 100 mg once daily and no oral corticosteroids.

REFERENCES

1. Danopoulou I, Stavropoulos P, Stratigos A, et al. Pemphigus vegetans confined to the scalp. *Int J Dermatol*. 2006;45:1008-1009.
2. Mori M, Mariotti G, Grandi V, et al. Pemphigus vegetans of the scalp [published online October 22,2014]. *J Eur Acad Dermatol Venereol*. 2016;30:368-370.
3. Augusto de Oliveira M, Martins E, Martins F, Lourenço S, et al. Oral pemphigus vegetans: a case report. *Dermatol Online J*. 2012;18:10.
4. Ma DL, Fang K. Hallopeau type of pemphigus vegetans confined to the right foot: case report. *Chin Med J (Engl)*. 2009;122:588-590.
5. Ahmed AR, Blose DA. Pemphigus vegetans. Neumann type and Hallopeau type. *Int J Dermatol*. 1984;23:135-141.
6. Harman KE, Albert S, Black MM, et al. Guidelines for the management of pemphigus vulgaris. *Br J Dermatol*. 2003;149:926-937.
7. Chrysomallis F, Dimitriades A, Chaidemenos GC, et al. Steroid-pulse therapy in pemphigus vulgaris long term follow-up. *Int J Dermatol*. 1995;34:438-442.
8. Ahmed AR. Intravenous immunoglobulin therapy in the treatment of patients with pemphigus vulgaris unresponsive to conventional immunosuppressive treatment. *J Am Acad Dermatol*. 2001;45:679-690.
9. Pasricha JS, Khaitan BK, Raman RS, et al. Dexamethasone-cyclophosphamide pulse therapy for pemphigus. *Int J Dermatol*. 1995;34:875-882.
10. Rook AH, Jegasothy BV, Heald P, et al. Extracorporeal photochemotherapy for drug-resistant pemphigus vulgaris. *Ann Int Med*. 1990;112:303-305.