

# Phacomatosis Cesiioflammea in Association With von Recklinghausen Disease (Neurofibromatosis Type I)

Bhushan Madke, MD; Sumit Kar, MD; Nitin Gangane, MD; Neha Singh, MD

### PRACTICE POINTS

- Phacomatosis cesiioflammea can be associated with neurofibromatosis type I.
- The port-wine stain component of phacomatosis cesiioflammea may develop nodularity in long-standing cases.
- The Nd:YAG laser is beneficial for treating blue spots of phacomatosis cesiioflammea.

To the Editor:

Vascular lesions associated with melanocytic nevi were first described by Ota et al<sup>1</sup> in 1947 and given the name phacomatosis pigmentovascularis. In 2005, Happle<sup>2</sup> reclassified phacomatosis pigmentovascularis into 3 well-defined types: (1) phacomatosis cesiioflammea: blue spots (*caesius* means bluish gray in Latin) and nevus flammeus; (2) phacomatosis spilorozea: nevus spilus coexisting with a pale pink telangiectatic nevus; and (3) phacomatosis cesiomarmorata: blue spots and cutis marmorata telangiectatica congenita. In 2011 Joshi et al<sup>3</sup> described a case of a 31-year-old woman who had a port-wine stain in association with neurofibromatosis type I (NF-1). We present a case of phacomatosis cesiioflammea in association with NF-1.

A 20-year-old woman presented to our outpatient section with a bluish black birthmark on the left side of the face since birth with the onset of multiple

painless flesh-colored nodules on the trunk and arms of 1 year's duration. She reported having occasional pruritus over the nodular lesions. Cutaneous examination showed multiple well-defined café au lait macules (0.5–3.0 cm) with regular margins. Multiple flesh-colored nodules were evident on the upper arms (Figure 1) and trunk. The nodules were firm in consistency and showed buttonholing phenomenon with some of the lesions demonstrating bag-of-worms consistency on palpation. Both palms showed multiple brownish frecklelike macules (Figure 2). A single bluish patch extended from the left ala of the nose to the sideburns. Adjoining the bluish patch was a subtle, ill-defined, nonblanchable red patch extending from the lower margin of the bluish patch to the mandibular ridge (Figure 3). Ocular examination showed melanosis bulbi of the left sclera and a few iris hamartomas (Lisch nodules) in both eyes. A biopsy of the skin nodule was obtained under local anesthesia after obtaining the patient's informed consent; the specimen was fixed in 10% buffered formalin. A hematoxylin and eosin–stained section showed a well-circumscribed nonencapsulated tumor in the dermis composed of loosely spaced spindle cells and wavy collagenous strands (Figure 4). Routine hemogram and blood biochemistry including urinalysis were within reference range. Radiologic examination of the long bones was unremarkable. Our patient had 3 of 6 criteria defined by the National Institutes of

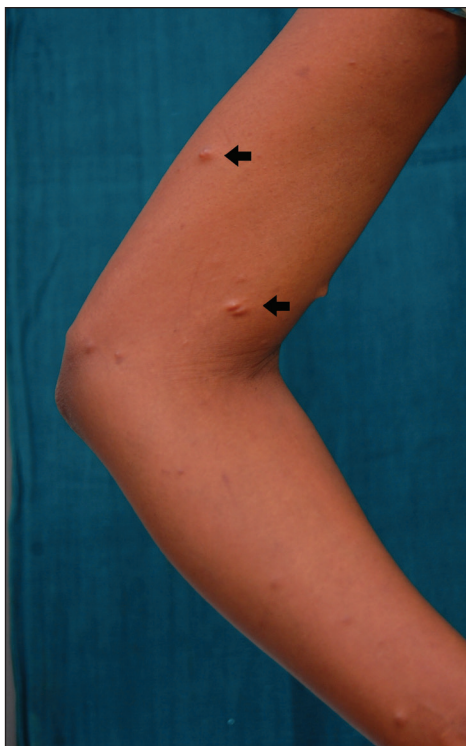---

From Mahatma Gandhi Institute of Medical Sciences, Sewagram, Wardha, Maharashtra, India. Drs. Madke, Kar, and Singh are from the Department of Dermatology, Venereology, and Leprosy.

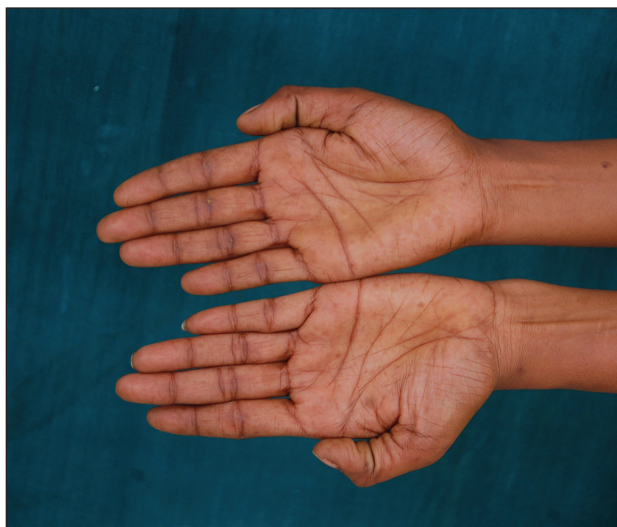
Dr. Gangane is from the Department of Pathology.

The authors report no conflict of interest.

Correspondence: Sumit Kar, MD, Department of Dermatology, Venereology, and Leprosy, Mahatma Gandhi Institute of Medical Sciences, Sewagram, Wardha, Maharashtra, India (karmgims@gmail.com).

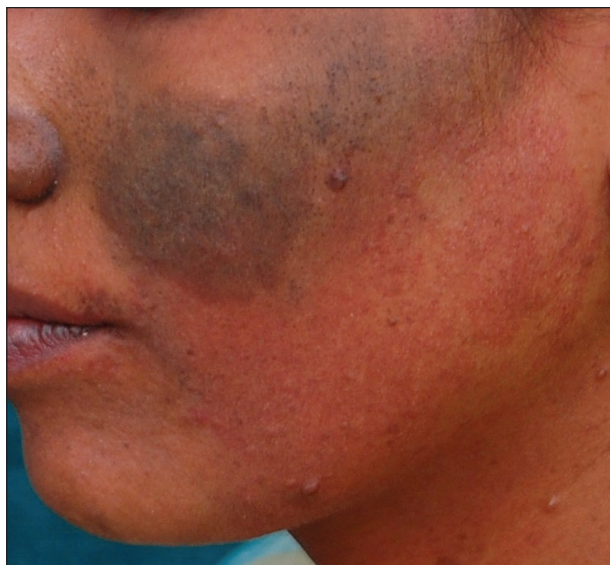

**Figure 1.** Cutaneous neurofibromas (molluscum fibrosa) (black arrows) on the left upper arm.

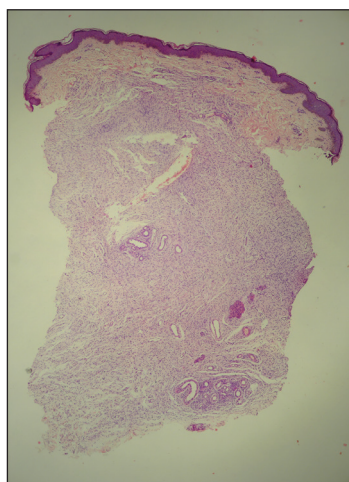


**Figure 2.** Multiple brownish frecklelike macules on both palmar surfaces.

Health for diagnosis of NF-1.<sup>4</sup> On clinicopathological correlation we made a diagnosis of phacomatosis cesioflammea in association with NF-1. We have reassured the patient about the benign nature of vascular nevus. She was informed that the skin nodules could increase in size during pregnancy and



**Figure 3.** Evidence of twin spotting with pigmented nevus (nevus of Ota) along with adjoining vascular nevus (nevus flammeus, port-wine stain).



**Figure 4.** Histopathology of a neurofibroma showing proliferation of spindle cells with elongated wavy nuclei (H&E, original magnification  $\times 10$ ).

to regularly follow-up with an eye specialist if any visual abnormalities occur.

The term *phacomatosis* is applied to genetically determined disorders of tissue derived from ectodermal origin (eg, skin, central nervous system, eyes) and commonly includes NF-1, tuberous sclerosis, and von Hippel-Lindau syndrome. Neurofibromatosis type I was first described by German pathologist Friedrich Daniel von Recklinghausen.<sup>5</sup> Phacomatosis pigmento-vascularis has been defined as the association of vascular nevus with a pigmented nevus. Its pathogenesis can

be explained by the twin spotting phenomenon.<sup>6</sup> Twin spots are paired patches of mutant tissue that differ from each other and from the surrounding normal background skin. They can occur as 2 clinical types: allelic and nonallelic twin spotting. Our patient had nonallelic twin spots for 2 nevoid conditions: vascular (nevus flammeus) and pigmentary (nevus of Ota). Nevus of Ota was distributed in the V2 segment (maxillary nerve) of the fifth cranial nerve along with classical melanosis bulbi, which is considered a characteristic clinical feature of nevus of Ota (nevus cesius).<sup>7</sup> Nevus flammeus (port-wine stain) is a vascular malformation presenting with flat lesions that persists throughout a patient's life. The phenomenon of twin spotting, or didymosis (*didymos* means twin in Greek), has been proposed for co-occurrence of vascular and pigmented nevi.<sup>8</sup> The association of NF-1 along with phacomatosis cesioflammea (a twin spot) could be explained from mosaicism of tissues derived from neuroectodermal and mesenchymal elements. Neurofibromatosis type I can occur as a mosaic disorder due to either postzygotic germ line or somatic mutations in the *NF1* gene located on the proximal long arm of chromosome 17.<sup>9</sup> Irrespective of the mutational event, a mosaic patient has a mixture of cells, some have normal copies of a particular gene and others have an abnormal copy of the same gene. Somatic mutation can lead to segmental (localized), generalized, or gonadal mosaicism. Somatic mutations occurring early during embryonic development produce generalized mosaicism, and generalized mosaics clinically appear similar to nonmosaic NF-1 cases.<sup>10,11</sup> However, due to a lack of adequate facilities for mutation analysis and financial constraints, we were unable to confirm our case as generalized somatic mosaic for *NF1* gene.

Several morphologic abnormalities have been reported with phacomatosis cesioflammea. Wu et al<sup>12</sup> reported a single case of phacomatosis cesioflammea associated with pectus excavatum in a 9-month-old infant. Shields et al<sup>13</sup> suggested that a thorough ocular examination on a periodic basis is essential to rule out melanoma of ocular tissues in patients with nevus flammeus and ocular melanosis.

Phacomatosis cesioflammea can occur in association with NF-1. The exact incidence of association is not known. The nevoid condition can be treated with appropriate lasers.

## REFERENCES

- Ota M, Kawamura T, Ito N. Phacomatosis pigmentovascularis (Ota). *Jpn J Dermatol*. 1947;52:1-3.
- Happle R. Phacomatosis pigmentovascularis revisited and reclassified. *Arch Dermatol*. 2005;141:385-388.
- Joshi A, Manchanda Y, Rijhwani M. Port-wine-stain with rare associations in two cases from Kuwait: phacomatosis pigmentovascularis redefined. *Gulf J Dermatol Venereol*. 2011;18:59-64.
- Neurofibromatosis. Conference Statement. National Institutes of Health Consensus. *Arch Neurol*. 1988; 45:575-578.
- Gerber PA, Antal AS, Neumann NJ, et al. Neurofibromatosis. *Eur J Med Res*. 2009;14:102-105.
- Goyal T, Varshney A. Phacomatosis cesioflammea: first case report from India. *Indian J Dermatol Venereol Leprol*. 2010;76:307.
- Happle R. Didymosis cesioanemica: an unusual counterpart of phacomatosis cesioflammea. *Eur J Dermatol*. 2011;21:471.
- Happle R, Steijlen PM. Phacomatosis pigmentovascularis interpreted as a phenomenon of twin spots [in German]. *Hautarzt*. 1989;40:721-724.
- Adigun CG, Stein J. Segmental neurofibromatosis. *Dermatol Online J*. 2011;17:25.
- Ruggieri M, Huson SM. The clinical and diagnostic implications of mosaicism in the neurofibromatoses. *Neurology*. 2001;56:1433-1443.
- Boyd KP, Korf BR, Theos A. Neurofibromatosis type 1. *J Am Acad Dermatol*. 2009;61:1-14.
- Wu CY, Chen PH, Chen GS. Phacomatosis cesioflammea associated with pectus excavatum. *Acta Derm Venereol*. 2009;89:309-310.
- Shields CL, Kligman BE, Suriano M, et al. Phacomatosis pigmentovascularis of cesioflammea type in 7 patients: combination of ocular pigmentation (melanocytosis or melanosis) and nevus flammeus with risk for melanoma. *Arch Ophthalmol*. 2011;129:746-750.