

What's Eating You? Lone Star Tick (*Amblyomma americanum*)

H. Harris Reynolds, MD; Dirk M. Elston, MD

PRACTICE POINTS

- *Amblyomma americanum* (lone star tick) is widely distributed throughout the United States and is an important cause of several tick-borne illnesses.
- Prompt diagnosis and treatment of tick-borne disease improves patient outcomes.
- In some cases, tick bites may cause the human host to develop certain IgE antibodies that result in a delayed-onset anaphylaxis after ingestion of red meat.

Amblyomma americanum, also known as the lone star tick, is found in much of the eastern United States. Since the mid-20th century, the lone star tick has been implicated in human disease. Today, *A. americanum* remains an important vector for tick-borne illness. In addition to others, species of *Rickettsia*, *Ehrlichia*, and *Borrelia* are all transmitted by the lone star tick. Recently described conditions such as Southern tick-associated rash illness and anaphylaxis to red meat following tick bites have been attributed to the lone star tick. Impressive local reactions also can result after bites from *A. americanum*. Early treatment of

tick-borne illness is crucial to ensure good patient outcomes. Tick-control measures also are an important part of disease management in endemic areas. We discuss the tick's biology, human illnesses associated with *A. americanum*, and methods to control tick numbers and eliminate disease in local reservoirs.

Cutis. 2017;99:111-114.

The lone star tick (*Amblyomma americanum*) is distributed throughout much of the eastern United States. It serves as a vector for species of *Rickettsia*, *Ehrlichia*, and *Borrelia* that are an important cause of tick-borne illness (Table). In addition, the bite of the lone star tick can cause impressive local and systemic reactions. Delayed anaphylaxis to ingestion of red meat has been attributed to the bite of *A. americanum*.¹ Herein, we discuss human disease associated with the lone star tick as well as potential tick-control measures.

Tick Characteristics

Lone star ticks are characterized by long anterior mouthparts and an ornate scutum (hard dorsal plate). Widely spaced eyes and posterior festoons also are present. In contrast to some other ticks, adanal plates are absent on the ventral surface in male lone star ticks. *Amblyomma americanum* demonstrates a single white spot on the female's

Dr. Reynolds is from the Medical Department, Training Air Wing SIX, Naval Air Station Pensacola, Florida. Dr. Elston is from the Department of Dermatology and Dermatologic Surgery, Medical University of South Carolina, Charleston.

The authors report no conflict of interest.

The views expressed are those of the authors and are not to be construed as official or as representing those of the US Navy or the Department of Defense. The authors were full-time federal employees at the time portions of this work were completed. The images are in the public domain.

Correspondence: H. Harris Reynolds, MD, Medical Department, Training Air Wing SIX, Naval Air Station Pensacola, 390 San Carlos Rd, Ste C, Pensacola, FL 32508 (hoyt.reynolds@navy.mil).

scutum (Figure 1). The male has inverted horseshoe markings on the posterior scutum. The female's scutum often covers only a portion of the body to allow room for engorgement.

Patients usually become aware of tick bites while the tick is still attached to the skin, which provides the physician with an opportunity to identify the tick and discuss tick-control measures as well as symptoms of tick-borne disease. Once the tick has been removed, delayed-type hypersensitivity to the tick antigens continues at the attachment site. Erythema and pruritus can be dramatic. Nodules with a pseudolymphomatous histology can occur. Milder reactions respond to application

of topical corticosteroids. More intense reactions may require intralesional corticosteroid injection or even surgical excision.

Most hard ticks have a 3-host life cycle, meaning they attach for one long blood meal during each phase of the life cycle. Because they search for a new host for each blood meal, they are efficient disease vectors. The larval ticks, so-called seed ticks, have 6 legs and feed on small animals. Nymphs and adults feed on larger animals. Nymphs resemble small adult ticks with 8 legs but are sexually immature.

Distribution

Amblyomma americanum has a wide distribution in the United States from Texas to Iowa and as far north as Maine (Figure 2).² Tick attachments often are seen in individuals who work outdoors, especially in areas where new commercial or residential development disrupts the environment and the tick's usual hosts move out of the area. Hungry ticks are left behind in search of a host.

Disease Transmission

Lone star ticks have been implicated as vectors of *Ehrlichia chaffeensis*, the agent of human monocytic ehrlichiosis (HME),³ which has been documented from the mid-Atlantic to south-central United States. It may present as a somewhat milder Rocky Mountain spotted fever–like illness with fever and headache or as a life-threatening systemic illness with organ failure. Prompt diagnosis and treatment with a tetracycline has been correlated with a better prognosis.⁴ Immunofluorescent antibody testing and polymerase chain reaction can be used to establish the diagnosis.⁵

Diseases Transmitted by <i>Amblyomma americanum</i> ^a	
Disease (Causative Agent)	
Bullis fever (unknown, <i>Rickettsia</i> is presumed)	
Heartland virus (Bunyaviridae: <i>Phlebovirus</i>)	
Human ehrlichiosis ewingii (<i>Ehrlichia ewingii</i>)	
Human monocytic ehrlichiosis (<i>Ehrlichia chaffeensis</i>)	
Southern tick-associated rash illness (<i>Borrelia lonestari</i>)	
Spotted fever rickettsiosis (<i>Rickettsia parkeri</i>)	
Tularemia (<i>Francisella tularensis</i>)	

^a*Amblyomma americanum* also may transmit Rocky Mountain spotted fever and Q fever.

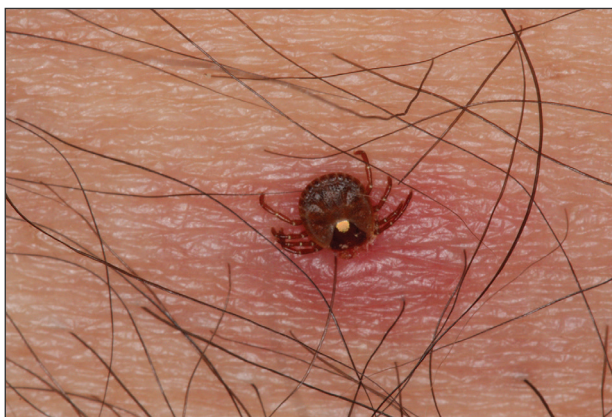

Figure 1. The female lone star tick demonstrates a single white spot on the scutum, leading to the common name lone star tick. A local inflammatory reaction has surrounded the site of attachment.

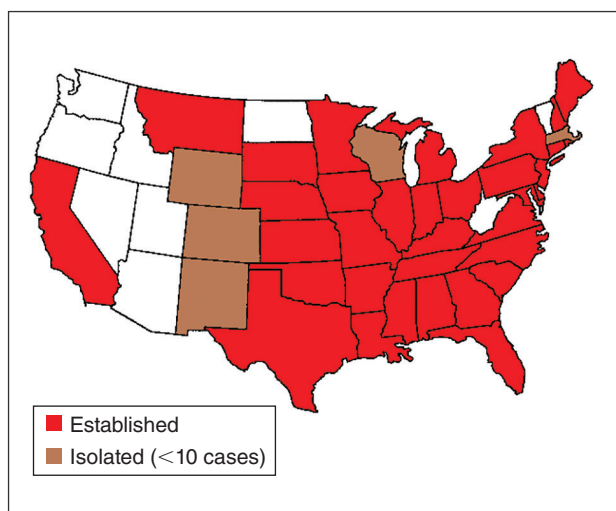


Figure 2. Distribution of *Amblyomma americanum* in 2014. Red states represent areas with established populations, while brown states represent areas with isolated reports of the tick. Data from Springer et al.²

Two tick species—*A. americanum* and *Dermacentor variabilis*—have been implicated as vectors, but *A. americanum* appears to be the major vector.^{6,7}

The lone star tick also is a vector for *Ehrlichia ewingii*, the cause of human ehrlichiosis *ewingii*. Human ehrlichiosis *ewingii* is a rare disease that presents similar to HME, with most reported cases occurring in immunocompromised hosts.⁸

A novel member of the *Phlebovirus* genus, the Heartland virus, was first described in 2 Missouri farmers who presented with symptoms similar to HME but did not respond to doxycycline treatment.⁹ The virus has since been isolated from *A. americanum* adult ticks, implicating them as the major vectors of the disease.¹⁰

Rickettsia parkeri, a cause of spotted fever rickettsiosis, is responsible for an eschar-associated illness in affected individuals.¹¹ The organism has been detected in *A. americanum* ticks collected from the wild. Experiments show the tick is capable of transmitting *R. parkeri* to animals in the laboratory. It is unclear, however, what role *A. americanum* plays in the natural transmission of the disease.¹²

In Missouri, strains of *Borrelia* have been isolated from *A. americanum* ticks that feed on cottontail rabbits, but it seems unlikely that the tick plays any role in transmission of true Lyme disease^{13,14}; *Borrelia* has been shown to have poor survival in the saliva of *A. americanum* beyond 24 hours.¹⁵ Southern tick-associated rash illness is a Lyme disease-like illness with several reported cases due to *A. americanum*.¹⁶ Patients generally present with an erythema migrans-like rash and may have headache, fever, arthralgia, or myalgia.¹⁶ The causative organism remains unclear, though *Borrelia lonestari* has been implicated.¹⁷ Lone star ticks also transmit tularemia and may transmit Rocky Mountain spotted fever and Q fever.¹³

Bullis fever (first reported at Camp Bullis near San Antonio, Texas) affected huge numbers of military personnel from 1942 to 1943.¹⁸ The causative organism appears to be rickettsial. During one outbreak of Bullis fever, it was noted that *A. americanum* was so numerous that more than 4000 adult ticks were collected under a single juniper tree and more than 1000 ticks were removed from a single soldier who sat in a thicket for 2 hours.¹² No cases of Bullis fever have been reported in recent years,¹² which probably relates to the introduction of fire ants.

Disease Hosts

At Little Rock Air Force Base in Arkansas, *A. americanum* has been a source of *Ehrlichia* infection. During one outbreak, deer in the area were found to have as many as 2550 ticks per ear,¹⁹ which

demonstrates the magnitude of tick infestation in some areas of the United States. Tick infestation is not merely of concern to the US military. Ticks are ubiquitous and can be found on neatly trimmed suburban lawns as well as in rough thickets.

More recently, bites from *A. americanum* have been found to induce allergies to red meat in some patients.¹ IgE antibodies directed against galactose-alpha-1,3-galactose (alpha gal) have been implicated as the cause of this reaction. These antibodies cause delayed-onset anaphylaxis occurring 3 to 6 hours after ingestion of red meat. Tick bites appear to be the most important and perhaps the only cause of IgE antibodies to alpha gal in the United States.¹

Wild white-tailed deer serve as reservoir hosts for several diseases transmitted by *A. americanum*, including HME, human ehrlichiosis *ewingii*, and Southern tick-associated rash illness.^{12,20} Communities located close to wildlife reserves may have higher rates of infection.²¹ Application of acaricides to corn contained in deer feeders has been shown to be an effective method of decreasing local tick populations, which is a potential method for disease control in at-risk areas, though it is costly and time consuming.²²

Tick-Control Measures

Hard ticks produce little urine. Instead, excess water is eliminated via salivation back into the host. Loss of water also occurs through spiracles. Absorption of water from the atmosphere is important for the tick to maintain hydration. The tick produces intensely hygroscopic saliva that absorbs water from surrounding moist air. The humidified saliva is then reingested by the tick. In hot climates, ticks are prone to dehydration unless they can find a source of moist air, usually within a layer of leaf debris.²³ When the leaf debris is stirred by a human walking through the area, the tick can make contact with the human. Therefore, removal of leaf debris is a critical part of tick-control efforts, as it reduces tick numbers by means of dehydration. Tick eggs also require sufficient humidity to hatch. Leaf removal increases the effectiveness of insecticide applications, which would otherwise do little harm to the ticks below if sprayed on top of leaf debris.

Some lone star ticks attach to birds and disseminate widely. Attachments to animal hosts with long-range migration patterns complicate tick-control efforts.²⁴ Animal migration may contribute to the spread of disease from one geographic region to another.

Imported fire ants are voracious eaters that gather and consume ticks eggs. Fire ants provide an excellent natural means of tick control. Tick numbers in places such as Camp Bullis have declined dramatically since the introduction of imported fire ants.²⁵

REFERENCES

1. Commins SP, Platts-Mills TA. Tick bites and red meat allergy. *Curr Opin Allergy Clin Immunol*. 2013; 13:354-359.
2. Springer YP, Eisen L, Beati L, et al. Spatial distribution of counties in the continental United States with records of occurrence of *Amblyomma americanum* (Ixodida: Ixodidae). *J Med Entomol*. 2014;51:342-351.
3. Yu X, Piesman JF, Olson JG, et al. Geographic distribution of different genetic types of *Ehrlichia chaffeensis*. *Am J Trop Med Hyg*. 1997;56:679-680.
4. Dumler JS, Bakken JS. Human ehrlichiosis: newly recognized infections transmitted by ticks. *An Rev Med*. 1998;49:201-213.
5. Dumler JS, Madigan JE, Pusterla N, et al. Ehrlichioses in humans: epidemiology, clinical presentation, diagnosis, and treatment. *Clin Infect Dis*. 2007;45 (suppl 1):S45-S51.
6. Lockhart JM, Davidson WR, Stallknecht DE, et al. Natural history of *Ehrlichia chaffeensis* (Rickettsiales: Ehrlichieae) in the piedmont physiographic province of Georgia. *J Parasitol*. 1997;83:887-894.
7. Centers for Disease Control and Prevention (CDC). Human ehrlichiosis—Maryland, 1994. *MMWR Morb Mortal Wkly Rep*. 1996;45:798-802.
8. Ismail N, Bloch KC, McBride JW. Human ehrlichiosis and anaplasmosis. *Clin Lab Med*. 2010;30:261-292.
9. McMullan LK, Folk SM, Kelly AJ, et al. A new phlebovirus associated with severe febrile illness in Missouri. *N Engl J Med*. 2012;367:834-841.
10. Savage HM, Godsey MS Jr, Panella NA, et al. Surveillance for heartland virus (Bunyaviridae: Phlebovirus) in Missouri during 2013: first detection of virus in adults of *Amblyomma americanum* (Acari: Ixodidae) [published online March 30, 2016]. *J Med Entomol*. pii:tjw028.
11. Cragun WC, Bartlett BL, Ellis MW, et al. The expanding spectrum of eschar-associated rickettsioses in the United States. *Arch Dermatol*. 2010;146:641-648.
12. Paddock CD, Sumner JW, Comer JA, et al. *Rickettsia parkeri*: a newly recognized cause of spotted fever rickettsiosis in the United States. *Clin Infect Dis*. 2004;38:805-811.
13. Goddard J, Varela-Stokes AS. Role of the lone star tick, *Amblyomma americanum* (L.) in human and animal diseases. *Vet Parasitol*. 2009;160:1-12.
14. Oliver JH, Kollars TM, Chandler FW, et al. First isolation and cultivation of *Borrelia burgdorferi* sensu lato from Missouri. *J Clin Microbiol*. 1998;36:1-5.
15. Ledin KE, Zeidner NS, Ribeiro JM, et al. Borreliacidal activity of saliva of the tick *Amblyomma americanum*. *Med Vet Entomol*. 2005;19:90-95.
16. Feder HM Jr, Hoss DM, Zemel L, et al. Southern tick-associated rash illness (STARI) in the North: STARI following a tick bite in Long Island, New York. *Clin Infect Dis*. 2011;53:e142-e146.
17. Varela AS, Luttrell MP, Howerth EW, et al. First culture isolation of *Borrelia lonestari*, putative agent of southern tick-associated rash illness. *J Clin Microbiol*. 2004;42:1163-1169.
18. Livesay HR, Pollard M. Laboratory report on a clinical syndrome referred to as “Bullis Fever.” *Am J Trop Med*. 1943;23:475-479.
19. Goddard J. Ticks and tickborne diseases affecting military personnel. US Air Force School of Aerospace Medicine USAFSAM-SR-89-2. <http://www.dtic.mil/dtic/tr/fulltext/u2/a221956.pdf>. Published September 1989. Accessed January 19, 2017.
20. Lockhart JM, Davidson WR, Stallknecht DE, et al. Isolation of *Ehrlichia chaffeensis* from wild white tailed deer (*Odocoileus virginianus*) confirms their role as natural reservoir hosts. *J Clin Microbiol*. 1997;35:1681-1686.
21. Standaert SM, Dawson JE, Schaffner W, et al. Ehrlichiosis in a golf-oriented retirement community. *N Engl J Med*. 1995;333:420-425.
22. Schulze TL, Jordan RA, Hung RW, et al. Effectiveness of the 4-Poster passive topical treatment device in the control of *Ixodes scapularis* and *Amblyomma americanum* (Acari: Ixodidae) in New Jersey. *Vector Borne Zoonotic Dis*. 2009;9:389-400.
23. Strey OF, Teel PD, Longnecker MT, et al. Survival and water-balance characteristics of unfed *Amblyomma cajennense* (Acari: Ixodidae). *J Med Entomol*. 1996;33:63-73.
24. Popham TW, Garris GI, Barre N. Development of a computer model of the population dynamics of *Amblyomma variegatum* and simulations of eradication strategies for use in the Caribbean. *Ann New York Acad Sci*. 1996;791:452-465.
25. Burns EC, Melancon DG. Effect of important fire ant (Hymenoptera: Formicidae) invasion on lone star tick (Acarina: Ixodidae) populations. *J Med Entomol*. 1977;14:247-249.

ATTENTION RESIDENTS!

Cutis® can help with

Fast Facts for Board Review

Download and print fact sheets and practice questions on commonly tested topics.



Studying for the dermatology boards examination?

NOW AVAILABLE:

Transient Benign Neonatal Skin Findings

Fact sheets and practice questions posted monthly.

www.cutis.com