

Radiographic Changes of Osteomyelitis in a Patient With Periungual Lichen Planus

Nita Kohli, MD, MPH; Daniel Gutierrez, MD; Kord S. Honda, MD

PRACTICE POINTS

- Lichen planus (LP) is an inflammatory mucocutaneous disorder with variable presentations.
- With extensive nail involvement, nail LP may impart radiographic findings suggestive of osteomyelitis.

To the Editor:

A 60-year-old woman presented for evaluation of a 1-year history of left hallux nail plate dystrophy and proximal nail fold inflammation. Her medical history included Cushing disease with associated uncontrolled diabetes mellitus (DM) and a remote history of cutaneous lichen planus (LP) that resolved 15 years prior to presentation. She noted improvement during intravenous courses of antibiotics for other infections.

Examination of the left hallux revealed onycholysis, loss of the nail plate, and a yellow fibrinous base alongside erosion, erythema, and edema of the proximal toenail fold (Figure 1). The left second toe pad was markedly tender to palpation with scant exudate expressed from underneath the nail bed. Two biopsies of the hallux were performed. The proximal nail fold specimen revealed mild epidermal hyperplasia, and the nail bed demonstrated a nonspecific ulcer that was negative for acid-fast bacilli and fungi.

Treatment over 2 months with cephalexin yielded improvement in both erythema and edema. Initial and repeat nail plate cultures grew ampicillin- and

penicillin-sensitive *Enterococcus faecalis*. Magnetic resonance imaging was performed to evaluate for osteomyelitis because of lack of resolution. Results demonstrated osteomyelitis of the distal tuft of the left hallux and the distal phalanx of the second toe (Figure 2). Vascular surgery evaluation revealed no evidence of large vessel arterial insufficiency. She was started on amoxicillin for superficial *Enterococcus* and

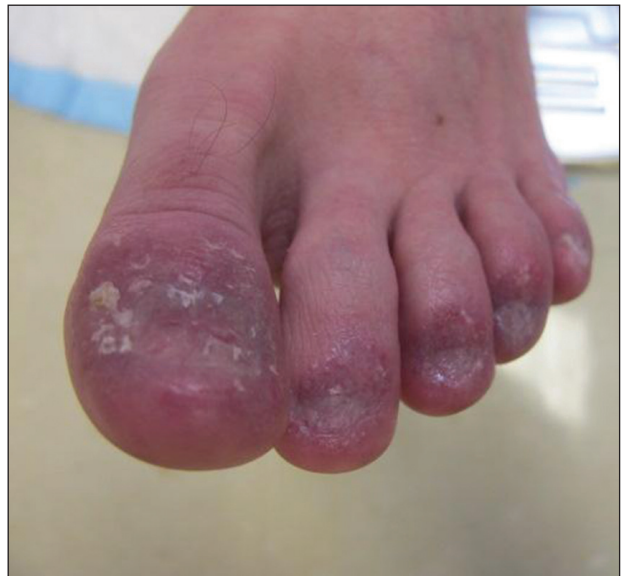

FIGURE 1. Left hallux with onycholysis, loss of the nail plate, and a yellow fibrinous base with concomitant erosion, erythema, and edema of the proximal toenail fold.

Dr. Kohli is from the Department of Medicine, University of Central Florida College of Medicine, Orlando. Dr. Gutierrez is from The Ronald O. Perleman Department of Dermatology, New York University School of Medicine, New York. Dr. Honda is from the Division of Dermatopathology, University Hospitals Medical Center, Department of Dermatology, Case Western Reserve University School of Medicine, Cleveland, Ohio. The authors report no conflict of interest.

Correspondence: Daniel Gutierrez, MD, The Ronald O. Perleman Department of Dermatology, New York University School of Medicine, 240 E 38th St, 11th Floor, New York, NY 10016 (Daniel.gutierrez@nyumc.org).

ciprofloxacin for underlying enteric bacilli. The persistence of infection was attributed to microvascular disease secondary to the patient's associated DM. Months later, due to suspected worsening of osteomyelitis, she underwent treatment with oral fluconazole to cover potential fungal co-infection and intravenous vancomycin and piperacillin-tazobactam for broad-spectrum antibacterial coverage. She was eventually transitioned to antimicrobial agents including amoxicillin-clavulanate potassium and topical mupirocin with improvement in periungual erythema and edema.

On subsequent dermatologic evaluation after 1 month, she presented with pterygium and loss of all nail plates on the left foot. The nail bed now had a violaceous color and was studded with milia. The clinical findings were suggestive of LP, consistent with her history of LP. In light of these new findings, both topical corticosteroids and retinoids were utilized for treatment without remarkable benefit. The patient declined further management with systemic medications.

We report a case of nail LP associated with underlying radiographic osteomyelitis. Erosive nail LP has been associated with underlying osteomyelitis of the phalanx.¹ Our patient developed these manifestations in the setting of Cushing disease, a unique finding given that many report improvement of LP with systemic corticosteroids.^{2,3} Tacrolimus, a calcineurin inhibitor, has been used in oral or topical formulations for lower extremity ulcers caused by LP as well as nail LP.^{1,4} Long-term prognosis of nail LP is poor, with high relapse rates and permanent damage to the nail unit.² It is important to be aware that LP of the nail unit may cause radiographic changes of osteomyelitis that are not infectious in nature.

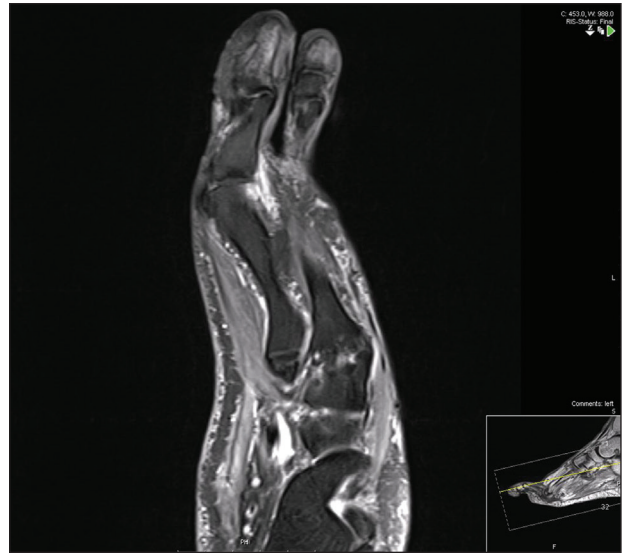


FIGURE 2. Magnetic resonance imaging of the left foot demonstrated osteomyelitis of the distal tuft of the left hallux and the distal phalanx of the second toe.

REFERENCES

1. Miller S. The effect of tacrolimus on lower extremity ulcers: a case study and review of the literature. *Ostomy Wound Manage.* 2008;54:36-42.
2. Goettmann S, Zarea I, Moulouguet I. Nail lichen planus: epidemiological, clinical, pathological, therapeutic and prognosis study of 67 cases. *Eur Acad Dermatol Venereol.* 2012;26:1304-1309.
3. Piraccini BM, Saccani E, Starace M, et al. Nail lichen planus: response to treatment and long term follow-up. *Eur J Dermatol.* 2010;20:489-496.
4. Ujiie H, Shibaki A, Akiyama M, et al. Successful treatment of nail lichen planus with topical tacrolimus. *Acta Derm Venereol.* 2010;90:218-219.