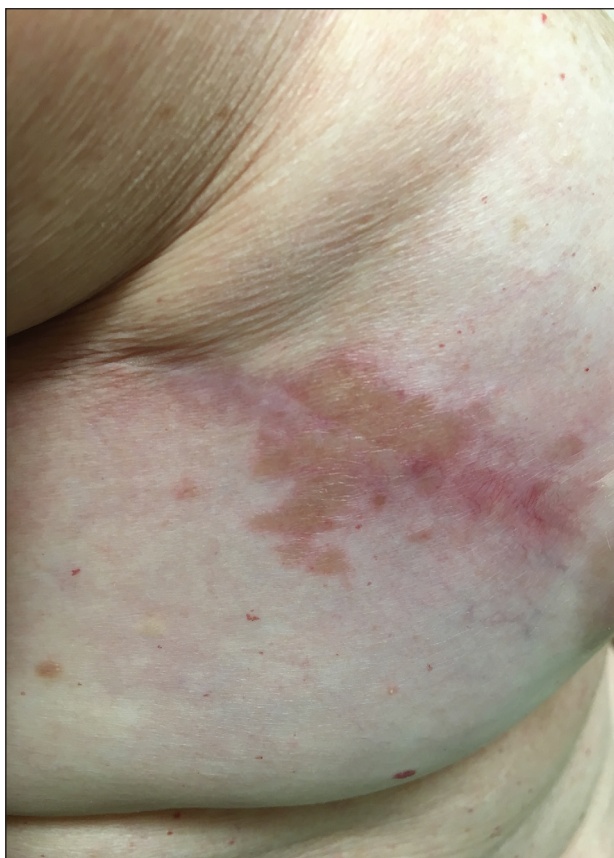


Coalescing Papules on Bilateral Mastectomy Scars

Brittany Blaise, MD; Ted Ryser, MD; Garth R. Fraga, MD; Ting Wang, MD



A 57-year-old woman with triple-negative ductal breast cancer presented with a mildly pruritic rash on bilateral mastectomy scars of 3 to 4 months' duration. More than a year prior to presentation, she was diagnosed with breast cancer and treated with a bilateral mastectomy and chemotherapy. On physical examination, faintly yellow, slightly indurated, coalescing papules with red rims were present on the bilateral mastectomy scars, with the scar on the left side appearing worse than the right. She previously had not sought treatment.

WHAT'S THE DIAGNOSIS?

- granulomatous dermatitis
- lichen sclerosus et atrophicus
- necrobiosis lipoidica diabetorum
- scar sarcoidosis
- xanthoma

PLEASE TURN TO **PAGE E31** FOR THE DIAGNOSIS

Dr. Blaise is from Southern Illinois University School of Medicine, Springfield. Drs. Ryser, Fraga, and Wang are from the University of Kansas Medical Center, Kansas City. Drs. Ryser and Wang are from the Division of Dermatology, Department of Internal Medicine, and Dr. Fraga is from the Department of Pathology and Laboratory Medicine.

The authors report no conflict of interest.

Correspondence: Ting Wang, MD, Division of Dermatology, Department of Internal Medicine, University of Kansas Medical Center, 3901 Rainbow Blvd, Kansas City, KS 66103 (twang@kumc.edu).

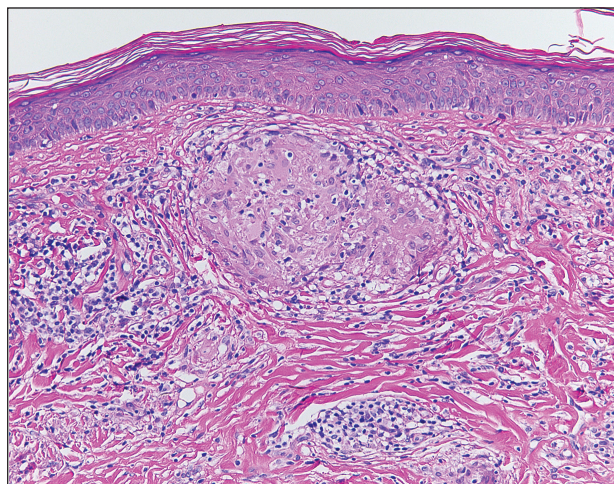
THE DIAGNOSIS: Scar Sarcoidosis

Although scars on both breasts were involved, the decision was made to biopsy the right breast because the patient reported more pain on the left breast. Biopsy showed noncaseating granulomas consistent with scar sarcoidosis (Figure). Additional screening tests were performed to evaluate for any systemic involvement of sarcoidosis, including a complete blood cell count, comprehensive metabolic panel, angiotensin-converting enzyme level, tuberculosis serology screening, electrocardiogram, chest radiograph, and pulmonary function tests. She also was referred to rheumatology and ophthalmology for consultation. The results of all screenings were within reference range, and no sign of systemic sarcoidosis was found. She was treated with hydrocortisone ointment 2.5% for several weeks without notable improvement. She elected not to pursue any additional treatment and to monitor the symptoms with close follow-up only. One year after the initial visit, the skin lesions spontaneously and notably improved.

Sarcoidosis is a systemic granulomatous disorder of unknown etiology that most commonly affects the lungs. It also can involve the lymph nodes, liver, spleen, bones, gastrointestinal tract, eyes, and skin. Cutaneous sarcoidosis has been documented in the literature since the late 1800s and occurs in up to one-third of sarcoid patients.¹ Cutaneous lesions developing within a preexisting scar is a well-known variant, occurring in 29% of patients with cutaneous sarcoidosis in one clinical study (N=818).² There have been many reports describing scar sarcoidosis, with its development at prior sites of surgery, trauma, acne, or venipuncture.³ Other case reports have described variants of scar sarcoidosis developing at sites of hyaluronic acid injection, laser surgery, ritual scarification, tattoos, and desensitization injections, as well as prior herpes zoster infections.⁴⁻⁹

Cutaneous sarcoidosis has a wide range of clinical presentations. Lesions can be described as specific or nonspecific. Specific lesions demonstrate the typical sarcoid granuloma on histology and more often are seen in chronic disease, while nonspecific lesions more often are seen in acute disease.^{3,10} Scar sarcoidosis is an example of a specific lesion in which old scars become infiltrated with noncaseating granulomas. The granulomas typically are in the superficial dermis but may involve the full thickness of the dermis, extending into the subcutaneous tissue.¹¹ The cause of granulomas developing in scars is unknown. Prior contamination of the scar with foreign material, possibly at the time of the trauma, is a possible underlying cause.¹²

Typical scar sarcoidosis presents as swollen, erythematous, indurated lesions with a purple-red hue that may



Biopsy of the right breast showed noncaseating granulomas consistent with scar sarcoidosis (H&E, original magnification $\times 100$).

become brown.^{3,12} Tenderness or pruritus also may be present.¹³ Interestingly, our patient's scar sarcoidosis presented with a yellow hue at both mastectomy sites.

Diagnosing scar sarcoidosis can be challenging. Patients are diagnosed with sarcoidosis when a compatible clinical or radiologic picture is present along with histologic evidence of a noncaseating granuloma and other potential causes are excluded.¹¹ The differential includes an infectious etiology, other types of granulomatous dermatitis, hypertrophic scar, keloid, or foreign body granuloma.

Scar sarcoidosis can be isolated in occurrence. It also can precede or occur concomitantly or during a relapse of systemic sarcoidosis.¹⁰ Most commonly, patients with scar sarcoidosis also have systemic manifestations of sarcoidosis, and changing scars may be an indicator of disease exacerbation or relapse.¹⁰ For patients who only demonstrate specific skin lesions of cutaneous sarcoidosis, approximately 30% develop systemic involvement later in life.³ For this reason, close monitoring and regular follow-up are necessary.

Treatment of scar sarcoidosis is dependent on the extent of the disease and presence of systemic sarcoidosis. Topical and systemic corticosteroids, hydroxychloroquine, chloroquine phosphate, and methotrexate all have been shown to be helpful in treating cutaneous sarcoidosis.³ For scar sarcoidosis that is limited to only the scar site, as seen in our case, monitoring and close follow-up is acceptable. Topical steroids can be prescribed for symptomatic relief. Scar sarcoidosis can resolve slowly and spontaneously over time.¹⁰

Our patient notably improved 1 year after the initial presentation without treatment.

Scar sarcoidosis is a well-documented variant of cutaneous sarcoidosis that can have important implications for diagnosing systemic sarcoidosis. Although there are typical lesions that represent scar sarcoidosis, it is important to have a high degree of suspicion with any changing scar. Once diagnosed through biopsy, a thorough investigation for systemic signs of sarcoidosis needs to be performed to guide treatment.

REFERENCES

1. Bologna JL, Jorizzo JL, Shaffer JV, eds. *Dermatology*. 3rd ed. Vol 2. Philadelphia, PA: Elsevier/Saunders; 2012.
2. Neville E, Walker AN, James DG. Prognostic factors predicting the outcome of sarcoidosis: an analysis of 818 patients. *Q J Med*. 1983; 52:525-533.
3. Mañá J, Marcoval J, Graells J, et al. Cutaneous involvement in sarcoidosis: relationship to systemic disease. *Arch Dermatol*. 1997;133:882-888.
4. Dal Sacco D, Cozzani E, Parodi A, et al. Scar sarcoidosis after hyaluronic acid injection. *Int J Dermatol*. 2005;44:411-412.
5. Kormeili T, Neel V, Moy RL. Cutaneous sarcoidosis at sites of previous laser surgery. *Cutis*. 2004;73:53-55.
6. Nayar M. Sarcoidosis on ritual scarification. *Int J Dermatol*. 1993; 32:116-118.
7. James WD, Elston DM, Berger TG, et al. *Andrews' Diseases of the Skin: Clinical Dermatology*. 11th ed. Philadelphia, PA: Elsevier/Saunders; 2011.
8. Healsmith MF, Hutchinson PE. The development of scar sarcoidosis at the site of desensitization injections. *Clin Exp Dermatol*. 1992; 17:369-370.
9. Singal A, Vij A, Pandhi D. Post herpes-zoster scar sarcoidosis with pulmonary involvement. *Indian Dermatol Online J*. 2014;5:77-79.
10. Chudomirova K, Velichkova L, Anavi B, et al. Recurrent sarcoidosis in skin scars accompanying systemic sarcoidosis. *J Eur Acad Dermatol Venereol*. 2003;17:360-361.
11. Selim A, Ehrsam E, Atassi MB, et al. Scar sarcoidosis: a case report and brief review. *Cutis*. 2006;78:418-422.
12. Singal A, Thami GP, Goraya JS. Scar sarcoidosis in childhood: case report and review of the literature. *Clin Exp Dermatol*. 2005;30:244-246.
13. Marchell RM, Judson MA. Chronic cutaneous lesions of sarcoidosis. *Clin Dermatol*. 2007;25:295-302.