

Topical Chemotherapy for Numerous Superficial Basal Cell Carcinomas Years After Isolated Limb Perfusion for Melanoma

Alexis B. Lyons, MD; Daniel A. Mitchell, BS; Ronald L. Moy, MD

Isolated limb perfusion (ILP) for the adjuvant treatment of melanoma involves isolating the blood flow of a limb from the rest of the body to allow for high concentrations of chemotherapeutic agents locally. Chemotherapy with nitrogen mustard is the preferred chemotherapeutic agent in ILP for the adjuvant treatment of locally advanced melanoma.¹ Systemic exposure to nitrogen mustard has shown to be carcinogenic, and its topical application has been associated with the development of actinic keratosis, basal cell carcinoma (BCC), and squamous cell carcinoma.^{2,3} However, the long-term effects of ILP with nitrogen mustard are not well defined. In 1998, one of the authors (R.L.M.) described a patient with melanoma of the left leg that was treated with ILP with nitrogen mustard who subsequently developed numerous BCCs on the same leg.⁴ This same patient has since been successfully managed with only topical chemotherapeutic agents for the last 21 years.

An 86-year-old man with a history of melanoma underwent wide resection, lymph node dissection, and adjuvant ILP with nitrogen mustard for the treatment of melanoma of the medial left thigh approximately 50 years ago. He denied any prior radiation treatment. He subsequently presented years later to our dermatology clinic with many biopsy-proven superficial and nodular BCCs of the left leg over the course of the last 30 years. On physical examination, the patient had several pink papules and macules on the left lower leg (Figure). The patient had previously undergone multiple invasive excisions with grafting for the treatment of BCCs by a plastic surgeon prior to presentation to our clinic but has since had many

years of control under our care with only topical chemotherapeutic agents. His current medication regimen consists of 5-fluorouracil twice daily, which he tolerates without serious side effects. He also has used imiquimod in the past.

Isolated limb perfusion was first described by Creech et al⁵ in 1958. Chemotherapy in ILP is designed to maximize limb perfusion while minimizing systemic absorption.¹ Metabolism of the drug is minimized by omitting the kidneys and liver from the circulation of the drug, allowing for high concentrations in the perfused limb.¹ Nitrogen mustard has been used for decades for the treatment of cancer but also has shown to be carcinogenic.^{2,3}

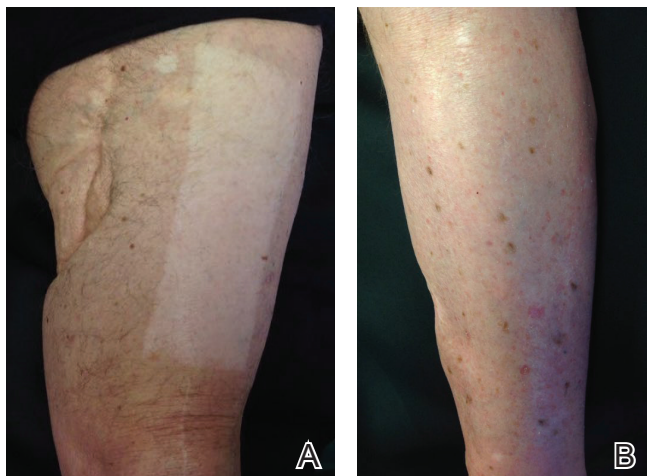
Topical use of nitrogen mustard has been linked to the development of nonmelanoma skin cancer (NMSC)^{2,3}; however, a 30-year population-based study found no significant increase in secondary malignancies, including NMSC or melanoma, following use of topical nitrogen mustard.⁶ There also have been reported cases of secondary cancers following ILP reported in the literature, including pleomorphic sarcoma and Merkel cell carcinoma.⁷ We hypothesize that our patient's exposure to nitrogen mustard during ILP led to the development of numerous BCCs, but further research is necessary to confirm this relationship.

Treatment modalities for NMSC include surgical excision with defined margins, Mohs micrographic surgery, radiotherapy, electrodesiccation and curettage, cryotherapy, photodynamic therapy, and topical therapy. Our patient experienced such a high volume of superficial BCCs that the decision was made to avoid frequent surgical procedures and to treat with topical

Dr. Lyons is from the Department of Dermatology, Henry Ford Hospital, Detroit, Michigan. Mr. Mitchell and Dr. Moy are from Moy, Fincher, Chipps Facial Plastics & Dermatology, Beverly Hills, California.

The authors report no conflict of interest.

Correspondence: Alexis Lyons, MD, 3031 W Grand Blvd, Ste 800, Detroit, MI 48202 (alexisblyons@gmail.com).



A, Excision site scar from melanoma on the proximal left anteromedial thigh with a split-thickness graft site. B, Multiple pink papules and macules on the left lower leg treated with topical chemotherapy.

chemotherapeutic agents. He had an excellent response to topical 5-fluorouracil, and the treatment has been well tolerated. This case is valuable for clinicians, as it demonstrates that topical chemotherapy can be a well-tolerated option for patients who present with frequent superficial BCCs to prevent numerous invasive surgical treatments.

REFERENCES

1. Benckhuijsen C, Kroon BB, van Geel AN, et al. Regional perfusion treatment with melphalan for melanoma in a limb: an evaluation of drug kinetics. *Eur J Surg Oncol*. 1988;14:157-163.
2. Abel EA, Sendagorta E, Hoppe RT. Cutaneous malignancies and metastatic squamous cell carcinoma following topical therapy for mycosis fungoides. *J Am Acad Dermatol*. 1986;14:1029-1038.
3. Lee LA, Fritz KA, Golitz L, et al. Second cutaneous malignancies in patients with mycosis fungoides treated with topical nitrogen mustard. *J Am Acad Dermatol*. 1982;7:590-598.
4. Lamb PM, Menaker GM, Moy RL. Multiple basal cell carcinomas of the limb after adjuvant treatment of melanoma with isolated limb perfusion. *J Am Acad Dermatol*. 1998;38:767-768.
5. Creech O Jr, Kremenz ET, Ryan RF, et al. Chemotherapy of cancer: regional perfusion utilizing an extracorporeal circuit. *Ann Surg*. 1958;148:616-632.
6. Lindahl L, Fenger-Grøn M, Iversen L. Secondary cancers, comorbidities and mortality associated with nitrogen mustard therapy in patients with mycosis fungoides: a 30-year population-based cohort study. *Br J Dermatol*. 2014;170:699-704.
7. Lenormand C, Pelletier C, Goeldel AL, et al. Second malignant neoplasm occurring years after hyperthermic isolated limb perfusion for melanoma. *Arch Dermatol*. 2010;146:319-321.