

# Idiopathic Bilateral Auricular Ossificans

David B. Harker, MD; Andrew P. Word, MD; Kevin Kia, MD

## PRACTICE POINTS

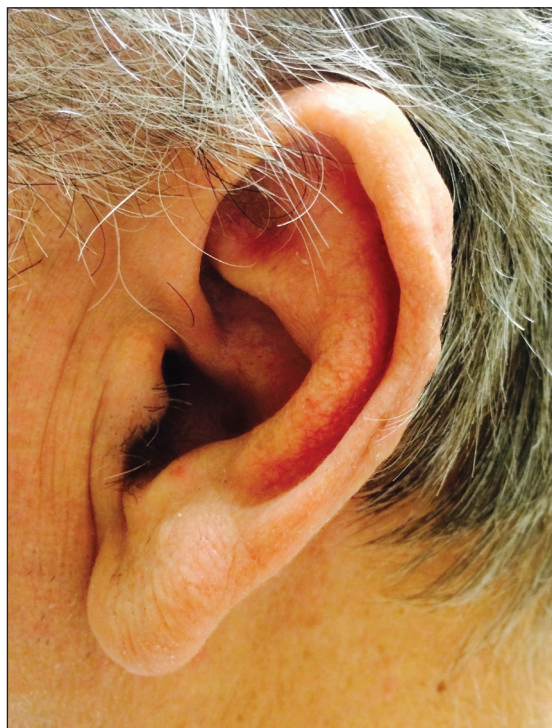- Auricular ossificans is a rare condition characterized by the replacement of external ear cartilage by bone.
- The majority of cases are asymptomatic at presentation with an insidious onset of the disease process over several years.
- Most patients present without pain or hearing abnormalities and do not require treatment.

## To the Editor:

A 60-year-old man with a history of basal cell carcinoma, rosacea, and seborrheic dermatitis presented for a routine skin examination. The patient mentioned incidentally that both of his ears were “rock hard” and had been so for the last 10 to 20 years. He was not experiencing hearing abnormalities and denied any history of external ear trauma, frostbite injury of the ears, or history of endocrinopathy. Physical examination revealed normal-appearing skin on the bilateral ears (Figure 1), and palpation confirmed a bonelike consistency of the auricles with sparing of the earlobes. The differential diagnosis included osteoma cutis, ectopic calcification, tophaceous gout, localized scleroderma, and relapsing polychondritis. Incisional biopsy of the left posterior auricle to the level of cartilage revealed a histologically normal epidermis and dermis, with small fragments of cartilage calcification and lacunar bone formation (Figure 2). A radiograph of the skull showed faint calcification of the auricular cartilage, but no other osseous abnormalities were observed (Figure 3). Further laboratory workup including a comprehensive metabolic panel; complete blood cell count; and thyroid stimulating hormone, parathyroid hormone, and cortisol levels were normal. Based on these findings, a diagnosis of bilateral idiopathic auricular

ossificans was made. Therapy was not pursued because the patient was asymptomatic, but referral to otolaryngology would have been considered if hearing impairment had occurred.

Auricular ossificans, which is characterized by the replacement of external ear cartilage by bone, is a rare condition with as few as 22 histologically proven cases documented in the literature.<sup>1,2</sup> One case was

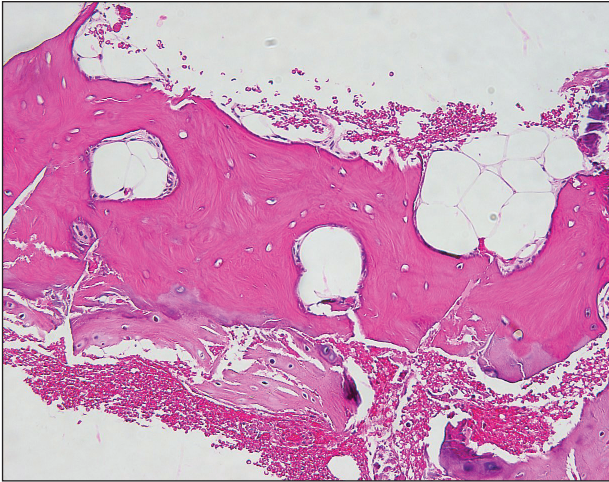


**FIGURE 1.** Normal-appearing skin on the left ear in a patient with auricular ossificans. Palpation of the auricle revealed a bonelike consistency.

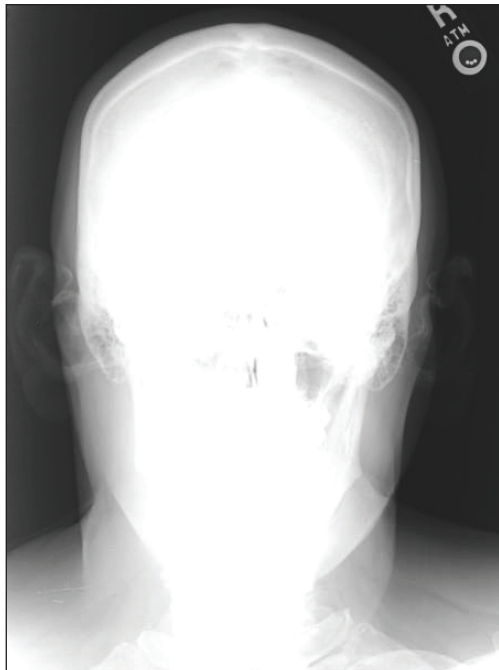
From the Department of Dermatology, University of Texas Southwestern Medical Center, Dallas.

The authors report no conflict of interest.

Correspondence: David Harker, MD, Department of Dermatology, UT Southwestern Medical Center, 5323 Harry Hines Blvd, Dallas, TX 75390 (David.harker@utsouthwestern.edu).



**FIGURE 2.** Incisional biopsy of the left posterior auricle to the level of cartilage revealed a histologically normal epidermis and dermis, with small fragments of cartilage calcification and visible lacunae (H&E, original magnification  $\times 400$ ).



**FIGURE 3.** Radiography of the skull revealed faint bilateral calcification of the bilateral auricles with no other osseous abnormalities.

reported in 2012 with consistent clinical and radiographic findings, but the patient declined biopsy.<sup>3</sup> Similar to our patient, many pathologically documented cases have been determined to be idiopathic after workup, with identifiable triggering factors including cold injury, trauma,

perichondritis, Addison disease, diabetes, and postpartum hypopituitarism.<sup>1</sup> The male-to-female ratio is 18 to 5, the average age at diagnosis is 57 years, and as many as 70% of cases have demonstrated bilateral involvement.<sup>1,2</sup>

The majority of cases of auricular ossificans are asymptomatic at presentation with an insidious onset of the disease process over several years. Physical examination of the ear generally reveals a petrified auricle with sparing of the lobule and an otherwise normal clinical appearance. Radiographs demonstrate calcification, sometimes exactly mimicking the pattern seen in normal bone. Biopsy and histologic analysis show not only calcified cartilage but also actual lamellar bone formation.<sup>4</sup> Depending on the precipitating factors, laboratory workup may uncover underlying metabolic abnormalities but often is unremarkable. Expert opinion generally recommends against extensive workup, which should be guided by the clinical presentation and the physician's judgement.<sup>5</sup> An insufficient number of patients with auricular ossificans have been definitively identified to provide clearer evidence-based recommendations.

Most patients present without pain or hearing abnormalities and do not require treatment. In one case, involvement of both the auricle and external ear canal resulted in intractable cerumen impaction that caused conductive hearing loss, eventually requiring resection of the ossified external ear cartilage and tragus.<sup>6</sup> The most common reason for treatment has been discomfort impairing sleep, with surgical intervention including conchal reduction or wedge resection.<sup>5</sup> A combined paucity of cases and poor understanding of the pathophysiologic mechanisms behind auricular ossificans limits current therapeutic options. Fortunately, this process appears to be benign in the majority of patients and generally represents a phenomenon that is much more interesting to the clinician than it is vexing to the patient.

**REFERENCES**

1. Calderon-Komaromy A, Cordoba S, Tardio JC, et al. Bilateral ossification of the auricular cartilage [published online November 28, 2014]. *Actas Dermosifiliogr*. 2015;106:433-435.
2. Chang KH, Kim DK, Kim JH, et al. Idiopathic acquired ectopic auricular ossification: a case report and review of the literature. *Ear Nose Throat J*. 2011;90:424-427.
3. Buikema KE, Adams EG. A rare case of petrified ear [published online October 15, 2012]. *Case Rep Dermatol Med*. 2012;2012:410601.
4. Mastronikolis NS, Zampakis P, Kalogeropoulou C, et al. Bilateral ossification of the auricles: an unusual entity and review of the literature. *Head Face Med*. 2009;5:17.
5. High WA, Larson MJ, Hoang MP. Idiopathic bilateral auricular ossificans: a case report and review of the literature. *Arch Pathol Lab Med*. 2004;128:1432-1434.
6. Manni JJ, Berénos-Riley LC. Ossification of the external ear: a case report and review of the literature [published online June 18, 2005]. *Eur Arch Otorhinolaryngol*. 2005;262:961-964.