

Psoriasiform Drug Eruption Secondary to Sorafenib: Case Series and Review of the Literature

Courtney J. Ensslin, MD; Pei-han Kao, MD; Ming-ying Wu, MD; Yao-yu Chang, MD; Tseng-tong Kuo, MD, PhD; Chia-hsun Hsieh, MD, MS; Sen-yung Hsieh, MD, PhD; Chih-hsun Yang, MD; Lloyd S. Miller, MD, PhD

PRACTICE POINTS

- The use of targeted anticancer agents continues to expand. With this expansion, the number and type of cutaneous adverse events continues to increase.
- Although sorafenib is known to cause various dermatologic side effects, there are few reports of psoriasiform dermatitis.
- Increased awareness of sorafenib-induced psoriasiform dermatitis and its management is vital to prevent discontinuation of potentially life-saving anticancer therapy.

The expanding use of novel targeted anticancer agents such as sorafenib has led to an increasing number of dermatologic adverse events. Although cutaneous adverse events are commonly described in patients taking sorafenib, there are few reports describing psoriasis secondary to this medication. In this report, we describe 3 patients with sorafenib-induced psoriasiform drug eruption and review the available literature of similar patient cases. Our findings highlight shared characteristics among affected patients and potential treatment options for patients in whom sorafenib cannot be discontinued. Increased awareness of such drug eruptions and management options is critical to prevent suboptimal dosing and decreased quality of life.

Cutis. 2019;104:E11-E15.

The expanded use of targeted anticancer agents such as sorafenib has revealed a growing spectrum of adverse cutaneous eruptions. We describe 3 patients with sorafenib-induced psoriasiform dermatitis and review the literature of only 10 other similar reported cases based on a search of PubMed, Web of Science, and American Society of Clinical Oncology abstracts using the terms *psoriasis* or *psoriasiform dermatitis* and *sorafenib*.¹⁻¹⁰ We seek to increase awareness of this particular drug eruption in response to sorafenib and to describe potential effective treatment options, especially when sorafenib cannot be discontinued.

Case Reports

Patient 1—A 68-year-old man with chronic hepatitis B infection and hepatocellular carcinoma (HCC) was started on sorafenib 400 mg daily. After 2 months of treatment, he developed painful hyperkeratotic lesions on the bilateral palms and soles with formation of calluses and superficial blisters on an erythematous base that was consistent with hand-foot skin reaction (HFSR). He also had numerous erythematous thin papules and plaques with adherent white scale and yellow crust on the bilateral thighs, lower legs, forearms, dorsal hands, abdomen, back, and buttocks (Figure 1). He had no personal or family history of psoriasis, and blood tests were unremarkable. Histologic analysis of punch biopsies from the buttocks and right leg revealed focal parakeratosis with neutrophils and serous

Drs. Ensslin and Miller are from the Department of Dermatology, Johns Hopkins University School of Medicine, Baltimore, Maryland. Drs. Kao, Wu, Chang, Kuo, C-h Hsieh, S-y Hsieh, and Yang are from Chang Gung Memorial Hospital, Taipei, Taiwan. Drs. Kao, Wu, Chang, Kuo, and Yang are from the Department of Dermatology, and Drs. C-h Hsieh and S-y Hsieh are from the Department of Gastroenterology and Hepatology. Drs. Kao, Chang, Kuo, and Yang also are from the University College of Medicine, Kwei Shan, Taoyuan, Taiwan.

The authors report no conflict of interest.

Correspondence: Courtney J. Ensslin, MD, Johns Hopkins Department of Dermatology, 1550 Orleans St, Cancer Research Bldg 2, Ste 209, Baltimore, MD 21231 (Courtney.ensslin@gmail.com).

crust, acanthosis, mild spongiosis, and lymphocytes at the dermoepidermal junction and surrounding dermal vessels, consistent with psoriasiform dermatitis (Figure 2). Sorafenib was discontinued and the eruption began to resolve within a week. A lower dose of sorafenib (200 mg daily) was attempted and the psoriasiform eruption recurred.

Patient 2—An 82-year-old man with chronic hepatitis B infection and HCC with lung metastasis was treated with sorafenib 400 mg daily. One week after treatment,

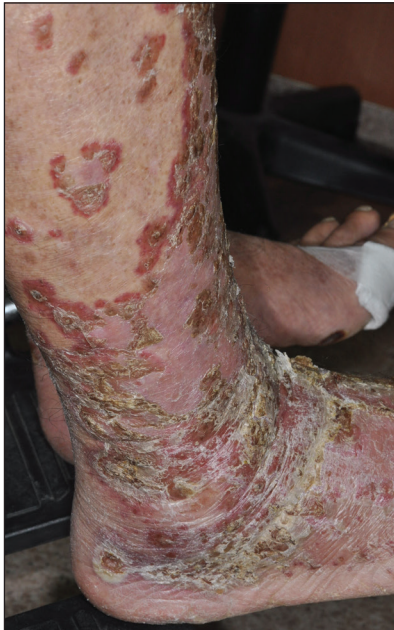

FIGURE 1. Sorafenib-induced plaque-type psoriasis. Erythematous thin papules and plaques with adherent white scale and yellow crust on the right lower leg (patient 1).

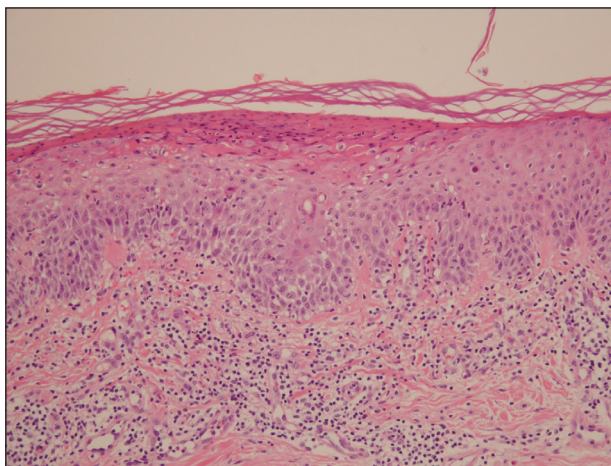


FIGURE 2. Microscopic findings of a lesion from patient 1 revealed psoriasiform hyperplasia with parakeratosis, mild spongiosis, and lymphocytes at the dermoepidermal junction and surrounding dermal vessels (H&E, original magnification $\times 100$).

he developed painful, thick, erythematous lesions on acral surfaces, consistent with HFSR. The sorafenib dose was decreased to 200 mg daily and HFSR resolved. Four months later, he developed well-demarcated, erythematous, scaly plaques with peripheral pustules on the right thigh (Figure 3) and right shin. He had no personal or family history of psoriasis, and blood tests were unremarkable. Samples from the pustules were taken for bacterial culture and fungal stain, but both were negative. Histologic analysis of a punch biopsy from the right thigh revealed necrotic parakeratosis, spongiform pustules, mild acanthosis, and a perivascular lymphocytic infiltrate with many neutrophils in the dermis. These findings suggested a diagnosis of pustular psoriasis, pustular drug eruption, or acute generalized exanthematous pustulosis. Treatment was initiated with mometasone cream. The patient subsequently developed hemoptysis and ascites from sorafenib. Sorafenib was discontinued and his skin eruption gradually resolved.

Patient 3—A 45-year-old woman with history of acute myeloid leukemia (AML) was started on sorafenib 200 mg twice daily as part of a clinical pilot study to maintain remission following an allogeneic bone marrow transplant. Four months after beginning sorafenib, the patient developed multiple well-defined, erythematous, thin papules and plaques with overlying flaky white scale on the bilateral upper extremities and trunk and scattered on the bilateral upper thighs (Figure 4) along with abdominal pain. Her other medical history, physical findings, and laboratory results were unremarkable, and there was no personal or family history of psoriasis. Her oncologist suspected that the eruption and symptoms were due to sorafenib and reduced the dose to 200 mg daily. Histologic analysis of a punch biopsy specimen revealed subcorneal neutrophilic collections with mild spongiosis and mild perivascular inflammatory infiltrate composed of lymphocytes and neutrophils (Figure 5). Direct immunofluorescence was

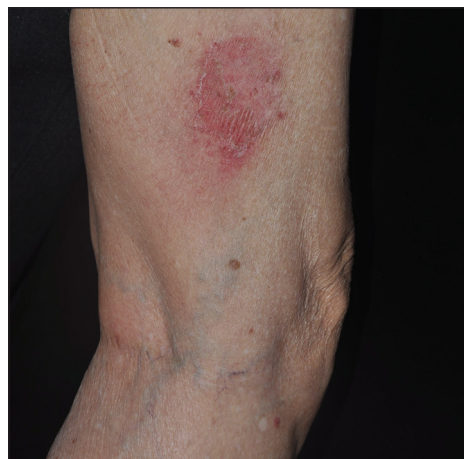

FIGURE 3. Sorafenib-induced pustular psoriasis. Erythematous scaly plaque with pustules along the periphery on the right lateral thigh (patient 2).

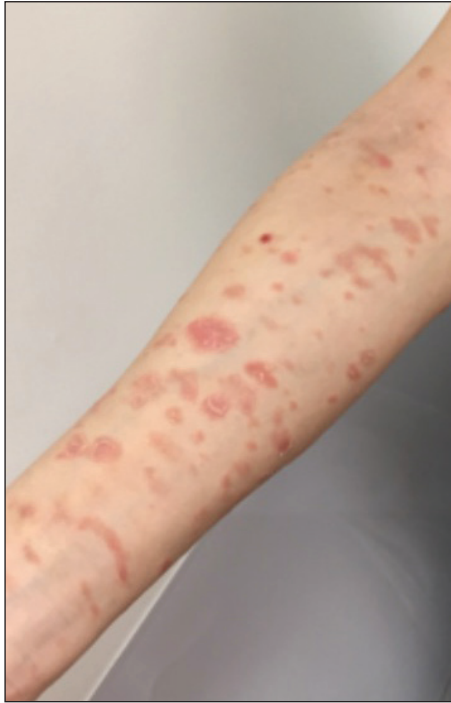

FIGURE 4. Sorafenib-induced psoriasiform drug eruption. Numerous erythematous scaly papules and plaques on the right ventral forearm (patient 3).

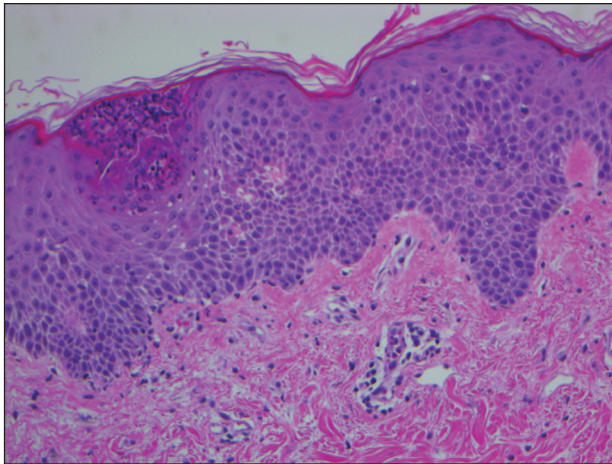


FIGURE 5. Microscopic findings of a lesion from patient 3 showed a subcorneal neutrophilic collection, acanthosis, mild spongiosis, and mild perivascular inflammatory infiltrate (H&E, original magnification $\times 200$).

negative for antibody or complement deposition. A bone marrow biopsy was negative for AML recurrence. The patient was continued on sorafenib to prevent AML recurrence, and she was started on triamcinolone cream 0.1% twice daily. Two weeks later, the eruption worsened and the patient was started on oral hydroxyzine for pruritus and narrowband UVB (NB-UVB) phototherapy 3 times a week. After 9 applications of NB-UVB phototherapy, there was complete resolution of the eruption.

Comment

Sorafenib is an oral tyrosine kinase inhibitor that blocks tumor cell proliferation and angiogenesis due to its activity against vascular endothelial growth factor (VEGF) receptor, platelet-derived growth factor receptor, stem cell growth factor receptor, and rapidly accelerated fibrosarcoma kinases.¹¹ It is primarily used for the treatment of solid tumors, such as advanced renal cell carcinoma, unresectable HCC, and thyroid carcinoma, and more recently has been expanded for treatment of AML due to potential inhibition of FMS-like tyrosine kinase 3 receptor. Although dermatologic toxicity is a common adverse event during treatment with sorafenib,¹¹ reports of psoriasiform drug eruptions are rare.

Review of Cases—Based on our literature search, there are 10 previously reported cases of psoriasiform drug eruption secondary to sorafenib. Of the 13 total cases (including the 3 patients in this report), 7 patients had a history of psoriasis; most were middle-aged men; and the treatment with sorafenib was for solid tumors, primarily HCC with the exception of patient 3 from the current report who was treated for AML (Table). In all cases, the dose of sorafenib ranged from 200 to 800 mg daily. In 5 cases, HFSR preceded (as with patient 2 in the current report) or presented concurrently (as with patient 1 in the current report) with the onset of psoriasiform rash.^{1,3,5}

Of the 13 total cases, patients with a history of psoriasis generally developed the eruption in a shorter period of time after starting sorafenib (eg, days to 2 months) compared to those without a history of psoriasis (eg, 2 to 9 months)(Table), suggesting that patients with preexisting psoriasis more rapidly developed the drug eruption than patients without a history. In these patients with a history of psoriasis, all had long-standing mild to moderate stable plaque psoriasis, with the exception of 1 case in which the type of psoriasis was not described (Table).⁷ The presentation of the drug eruption following sorafenib varied from psoriasiform drug eruption (5 patients, including patient 3),^{2,3,6,9} pustular psoriasis (5 patients, including patient 2),^{4,7,8,10} and plaque psoriasis (3 patients, including patient 1).^{1,5} Interestingly, 5 of 6 patients with a history of plaque psoriasis presented with pustular psoriasis or psoriasiform drug eruption after treatment with sorafenib.^{4-6,8-10} These results suggest a causal relationship between sorafenib and exacerbation of preexisting psoriasis.

In the 13 total cases, treatments included mid- to high-potency topical steroids (10 cases), UVB or NB-UVB phototherapy (7 cases), and discontinuation of sorafenib (10 cases)(Table). All of these treatments led to improvement of the eruption with the exception of 1 case in which hand involvement was recalcitrant to therapy.⁹ Of the 10 cases in which sorafenib was discontinued, rechallenge at a lower dose was performed in 6 cases (including patient 1)^{3,4,6,7,9} with recurrence of psoriasiform rash seen in 5 cases (including patient 1)(Table).^{4,6,7,9} These data strongly implicate sorafenib as the direct

Cases of Sorafenib-Associated Psoriasis

Patient Age, y/ Gender	Duration of Sorafenib Prior to Rash Onset	Dose of Sorafenib	Clinical Presentation	Treatment of Psoriasis	Sorafenib Discontinued	Clinical Response of Psoriasis
Cases of Sorafenib-Induced Psoriasis						
56/M ¹	3 mo	400 mg twice daily	Plaque-type psoriasis	NB-UVB phototherapy	No	Complete remission
59/M ²	4 mo	400 mg twice daily	Psoriasiform drug eruption	Topical steroids, NB-UVB phototherapy	No	Improved
63/M ³	9 mo	400 mg twice daily	Psoriasiform drug eruption	Triamcinolone cream	Yes; restarted at lower dose without rash recurrence	Improved
68/M (current report)	2 mo	400 mg daily	Plaque-type psoriasis	None	Yes; restarted at lower dose with rash recurrence	Improved
82/M (current report)	4 mo	400 mg daily, lowered to 200 mg daily	Pustular psoriasis	Mometasone cream	Yes	Improved
45/F (current report)	4 mo	200 mg twice daily, lowered to 200 mg daily	Psoriasiform drug eruption	Triamcinolone cream, NB-UVB phototherapy, oral hydroxyzine	No	Complete remission
Cases of Sorafenib-Exacerbated Psoriasis						
68/M ⁴	2 mo	200 mg daily	Pustular psoriasis	Topical steroid, topical vitamin D ₃ , NB-UVB phototherapy	Yes; restarted at lower dose with rash recurrence	Improved
61/M ⁵	Within days	400 mg daily	Plaque-type psoriasis	Potent topical steroid with vitamin D ₃ , UVB phototherapy	Yes	Complete remission
69/M ⁶	10 d	400 mg twice daily	Psoriasiform drug eruption	Clobetasol propionate ointment, NB-UVB phototherapy	Yes; restarted at lower dose with rash recurrence	Improved
75/M ⁷	3 wk	400 mg daily	Pustular psoriasis	Potent topical steroid with vitamin D ₃	Yes; restarted at lower dose with rash recurrence	Improved
59/M ⁸	6 d	200 mg daily	Annular pustular psoriasis	Potent topical steroid	Yes	Complete remission
56/M ⁹	1 mo	Unknown	Psoriasiform drug eruption	Mid-potency topical steroids, phototherapy	Yes; restarted at lower dose with rash recurrence	Partial improvement
73/M ¹⁰	7 d	400 mg daily	Pustular psoriasis	Topical steroids	Yes	Improved

Abbreviations: M, male; NB-UVB, narrowband UVB; F, female.

cause of these psoriasiform eruptions. In the 3 cases in which sorafenib was not discontinued (including patient 3), there was notable improvement of the eruption with NB-UVB phototherapy.^{1,2}

Vascular endothelial growth factor is overexpressed on psoriatic keratinocytes, contributes to epidermal hyperplasia, and induces angiogenesis in the dermis.¹² The development of psoriasiform eruptions in patients treated with sorafenib seems paradoxical, as this drug has been considered as potential therapy for psoriasis due to its ability to block VEGF receptor signaling. Indeed, an improvement of psoriasis has been reported in 1 case of a patient treated with sorafenib¹³ and in multiple patients with psoriasis treated with other VEGF antagonists (eg, bevacizumab).¹⁴ The underlying mechanisms by which sorafenib induced or exacerbated psoriasis are not entirely clear. Palmoplantar hyperkeratosis, keratosis pilaris-like eruption, multiple cysts, eruptive keratoacanthomas, and squamous cell carcinoma have been described in patients treated with sorafenib, supporting the hypothesis that treatment with sorafenib alters keratinocyte proliferation and differentiation.¹⁵ In addition, B-Raf inhibitors such as imatinib are known to induce or exacerbate psoriasiform dermatitis.¹⁶ The activity of sorafenib resulting in psoriasis may be specific to RAF kinase inhibition, as there are no reports in the literature that describe psoriasiform dermatitis with agents that preferentially block other sorafenib targets such as VEGF receptor, stem cell growth factor receptor, or platelet-derived growth factor receptor. Future studies are needed to fully elucidate the underlying mechanisms by which sorafenib induces or exacerbates psoriasiform dermatitis and whether the severity of the drug eruption correlates with the antitumor efficacy of sorafenib.

Conclusion

Although psoriasiform drug eruptions secondary to sorafenib are not life-threatening, they impact quality of life with associated pain, pruritus, infection, and limitation of daily activities. Dose reduction or discontinuation

of sorafenib resulted in resolution of the psoriasiform dermatitis; however, as demonstrated in 3 cases (including patient 3),^{1,2} psoriasiform dermatitis can be managed while maintaining the patient on sorafenib so that treatment of the malignancy is not compromised.

REFERENCES

- Hung CT, Chiang CP, Wu BY. Sorafenib-induced psoriasis and hand-foot skin reaction responded dramatically to systemic narrowband ultraviolet B phototherapy. *J Dermatol*. 2012;39:1076-1077.
- González-López M, Yáñez S, Val-Bernal JF, et al. Psoriasiform skin eruption associated with sorafenib therapy. *Indian J Dermatol Venereol Leprol*. 2011;77:614-615.
- Diamantis ML, Chon SY. Sorafenib-induced psoriasiform eruption in a patient with metastatic thyroid carcinoma. *J Drugs Dermatol*. 2010;9:169-171.
- Hsu MC, Chen CC. Psoriasis flare-ups following sorafenib therapy: a rare case. *Dermatologica Sin*. 2016;34:148-150.
- Yiu ZZ, Ali FR, Griffiths CE. Paradoxical exacerbation of chronic plaque psoriasis by sorafenib. *Clin Exp Dermatol*. 2016;41:407-409.
- İlknur T, Akarsu S, Çarsanbali S, et al. Sorafenib-associated psoriasiform eruption in a patient with hepatocellular carcinoma. *J Drugs Dermatol*. 2014;13:899-900.
- Maki N, Komine M, Takatsuka Y, et al. Pustular eruption induced by sorafenib in a case of psoriasis vulgaris. *J Dermatol*. 2013;40:299-300.
- Du-Thanh A, Girard C, Pageaux GP, et al. Sorafenib-induced annular pustular psoriasis (Milian-Katchoura type). *Eur J Dermatol*. 2013;23:900-901.
- Laquer V, Saedi N, Dann F, et al. Sorafenib-associated psoriasiform skin changes. *Cutis*. 2010;85:301-302.
- Ohashi T, Yamamoto T. Exacerbation of psoriasis with pustulation by sorafenib in a patient with metastatic hepatocellular carcinoma. *Indian J Dermatol*. 2019;64:75-77.
- Chu D, Lacouture ME, Fillos T, et al. Risk of hand-foot skin reaction with sorafenib: a systematic review and meta-analysis. *Acta Oncol (Madr)*. 2008;47:176-186.
- Canavese M, Altruda F, Ruzicka T, et al. Vascular endothelial growth factor (VEGF) in the pathogenesis of psoriasis--a possible target for novel therapies? *J Dermatol Sci*. 2010;58:171-176.
- Fournier C, Tisman G. Sorafenib-associated remission of psoriasis in hypernephroma: case report. *Dermatol Online J*. 2010;16:17.
- Akman A, Yilmaz E, Mutlu H, et al. Complete remission of psoriasis following bevacizumab therapy for colon cancer. *Clin Exp Dermatol*. 2009;34:E202-E204.
- Kong HH, Turner ML. Array of cutaneous adverse effects associated with sorafenib. *J Am Acad Dermatol*. 2009;61:360-361.
- Atalay F, Kızılkılıç E, Ada RS. Imatinib-induced psoriasis. *Turk J Haematol*. 2013;30:216-218.