

Pembrolizumab-Induced Lobular Panniculitis in the Setting of Metastatic Melanoma

Caitlin M. Peterman, MD; Leslie Robinson-Bostom, MD; So Yeon Paek, MD

PRACTICE POINTS

- Pembrolizumab may cause lobular panniculitis years after treatment initiation.
- Pembrolizumab-induced lobular panniculitis may self-resolve without discontinuing the medication.

To the Editor:

Pembrolizumab is an anti-programmed death receptor 1 humanized monoclonal antibody used for treating advanced or metastatic melanoma.¹ It is associated with several immune-related adverse events because it blocks a T-cell receptor checkpoint.² The most common dermatologic immune-related adverse event seen with anti-programmed death receptor 1 medications is a nonspecific morbilliform rash, usually seen after the second treatment cycle; however, pruritus, vitiligo, bullous disorders, and lichenoid reactions also have been reported.³ We report a case of pembrolizumab-induced, self-limited lobular panniculitis in a patient with metastatic melanoma.

A 37-year-old woman with malignant melanoma presented with tender, erythematous, subcutaneous nodules on the hips and legs of 2 weeks' duration (Figure 1). Twelve years prior to the current presentation, she was diagnosed with metastases to the cecum, lung, and brain. A review of systems was otherwise negative. She had been receiving pembrolizumab infusions (2 mg/kg every 3 weeks) for the last 2.7 years as second-line therapy after previously undergoing chemotherapy, radiation, and resection. She was not taking oral contraceptives or other hormone-based medications and did not report any new medications.

Laboratory testing was negative for infectious processes including Lyme disease, tuberculosis, and *Streptococcus* due to recent upper respiratory infection. Punch biopsy of a left shin lesion revealed a lobular panniculitis with lymphohistiocytic inflammation, a focal lymphocytic vasculitis, and small granulomas (Figure 2). Periodic acid-Schiff, Gram, and acid-fast bacilli stains were negative. After ruling out alternative causes, the etiology of the panniculitis was deemed to be a pembrolizumab side effect.

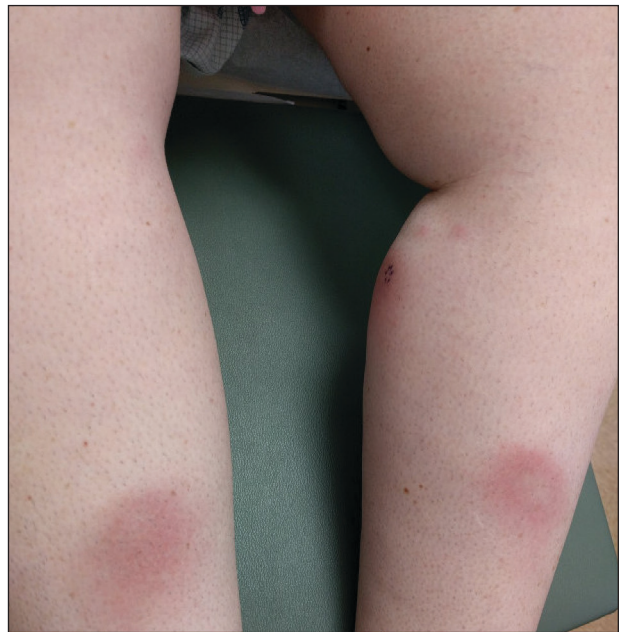

FIGURE 1. Pink-red subcutaneous nodules with central pallor ranging in size from 4.5 to 7 cm on the lower extremities.

Dr. Peterman is from the Department of Dermatology, University of California, Davis, Sacramento. Dr. Robinson-Bostom is from the Department of Dermatology, Warren Alpert Medical School of Brown University, Rhode Island Hospital, Providence. Dr. Paek is from the Department of Dermatology, Baylor Scott & White Health, Dallas, Texas.

The authors report no conflict of interest.

Correspondence: Caitlin M. Peterman, MD, University of California, Davis, 3301 C St, Ste 1400, Sacramento, CA 95816 (caitlin.peterman@tufts.edu).

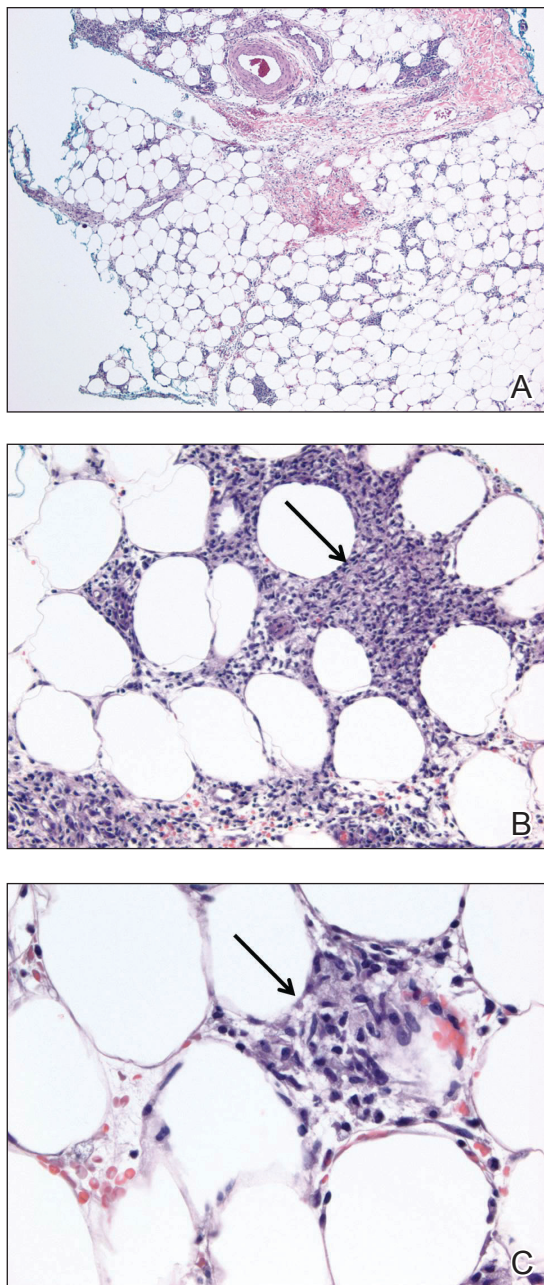


FIGURE 2. A, Punch biopsy of the left shin showed a lobular panniculitis with lymphohistiocytic infiltrate (H&E, original magnification $\times 40$). B and C, A small, ill-defined granuloma (arrows) (H&E, original magnifications $\times 200$ and $\times 400$).

The patient was treated conservatively with ibuprofen; pembrolizumab was not discontinued. Two weeks later, the panniculitis had resolved without additional treatment. She remains on pembrolizumab and is doing well.

Panniculitis is known to be associated with certain BRAF inhibitors used for the treatment of melanoma positive for the BRAF V600E mutation, including vemurafenib and dabrafenib.^{4,5} Reports of panniculitis in the setting of pembrolizumab are limited and are seen within the larger context of sarcoidosis. One patient on pembrolizumab for metastatic melanoma developed granulomatous lobular panniculitis with oligoarthritis, high fever, and hilar/mediastinal adenopathy, consistent with pembrolizumab-induced sarcoidosis. It developed after her second pembrolizumab infusion and resolved with prednisone and temporary pembrolizumab cessation.⁶ In another case, pembrolizumab triggered a flare of sarcoidosis with similar granulomatous subcutaneous nodules in a patient with stage IV lymphoma who was previously diagnosed with sarcoidosis but lacked cutaneous manifestations. The lesions resolved with prednisone therapy.⁷

Chest computed tomography was normal in our patient, and she reported no systemic symptoms. Additional laboratory studies to evaluate for sarcoidosis were not obtained. Furthermore, the lesions quickly resolved despite continued use of pembrolizumab. We report this case to highlight that pembrolizumab may induce an isolated, self-limited lobular panniculitis years after medication initiation.

REFERENCES

1. Poole RM. Pembrolizumab: first global approval. *Drugs*. 2014; 74:1973-1981.
2. Michot JM, Bigenwald C, Champiat S, et al. Immune-related adverse events with immune checkpoint blockade: a comprehensive review. *Eur J Cancer*. 2016;54:139-148.
3. Naidoo J, Page DB, Li BT, et al. Toxicities of the anti-PD-1 and anti-PD-L1 immune checkpoint antibodies. *Ann Oncol*. 2016;27:1362.
4. Boussemart L, Routier E, Mateus C, et al. Prospective study of cutaneous side-effects associated with the BRAF inhibitor vemurafenib: a study of 42 patients. *Ann Oncol*. 2013;24:1691-1697.
5. Ramani NS, Curry JL, Kapil J, et al. Panniculitis with necrotizing granulomata in a patient on BRAF inhibitor (dabrafenib) therapy for metastatic melanoma. *Am J Dermatopathol*. 2015;37:E96-E99.
6. Burillo-Martinez S, Morales-Raya C, Prieto-Barríos M, et al. Pembrolizumab-induced extensive panniculitis and nevus regression: two novel cutaneous manifestations of the post-immunotherapy granulomatous reactions spectrum. *JAMA Dermatol*. 2017;153:721-722.
7. Cotliar J, Querfeld C, Boswell WJ, et al. Pembrolizumab-associated sarcoidosis. *JAAD Case Rep*. 2016;2:290-293.