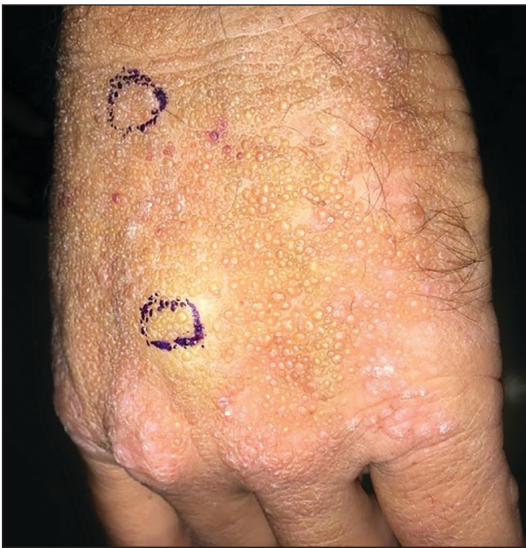

# Smooth Papules on the Left Hand

Cody Hanson, DO; Sarah Moore, MD; Garth Fraga, MD; Anand Rajpara, MD



A 41-year-old man presented to the outpatient dermatology clinic with multiple smooth papules on the left hand of 7 years' duration. The papules had been steadily increasing in number, and the patient reported that they were frequently symptomatic with a burning itching sensation. Physical examination revealed multiple 1- to 3-mm, dome-shaped, translucent to flesh-colored papules on the left hand with a few scattered bright red papules. No similar lesions were present on the right hand or elsewhere on the body. He had a history of hypertension but was otherwise healthy with no other chronic medical conditions.

## WHAT'S THE DIAGNOSIS?

- adult colloid milium
- lichen amyloidosis
- lipoid proteinosis
- molluscum contagiosum
- primary cutaneous amyloidosis

PLEASE TURN TO **PAGE E6** FOR THE DIAGNOSIS

Drs. Hanson, Fraga, and Rajpara are from the University of Kansas Medical Center, Kansas City. Drs. Hanson and Rajpara are from the Department of Dermatology, and Dr. Fraga is from the Department of Pathology. Dr. Moore is from Sacred Heart Medical Center, Spokane, Washington. The authors report no conflict of interest.

Correspondence: Cody Hanson, DO, 3901 Rainbow Blvd, Kansas City, KS 66160 (chanson5@kumc.edu).

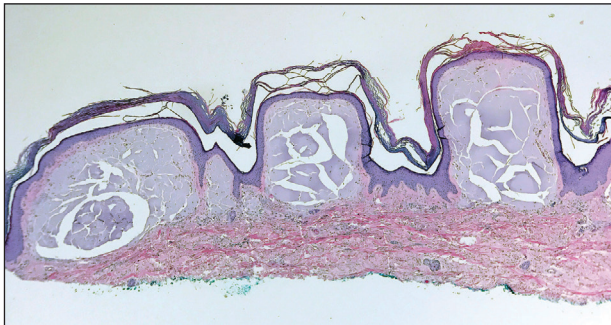
## THE DIAGNOSIS: Adult Colloid Milium

A 4-mm punch biopsy was performed and histopathologic evaluation revealed collections of amorphous eosinophilic material and fissures in the papillary dermis with sparing of the dermoepidermal junction, indicating adult colloid milium (Figure 1).

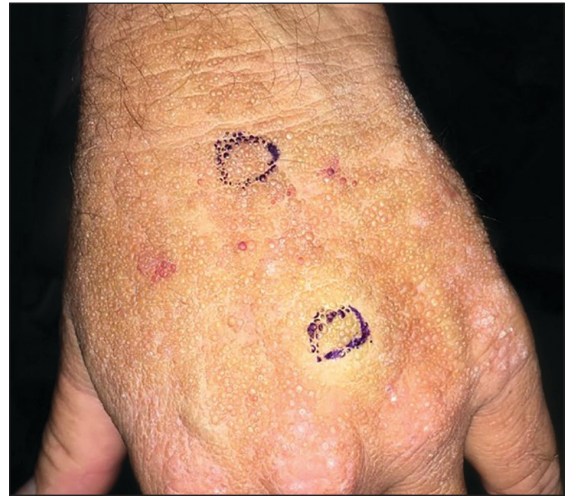Adult colloid milium is an uncommon condition with grouped translucent to whitish papules that present on sun-exposed skin on the hands, face, neck, or ears in middle-aged adults.<sup>1</sup> It has been associated with petrochemical exposure, tanning bed use, and excessive sun exposure. Our patient had a history of sun exposure, specifically to the left hand while driving. This condition is widely thought to be a result of photoinduced damage to elastic fibers and may potentially be a popular variant of severe solar elastosis.<sup>2</sup> Due to vascular fragility, trauma to these locations often will result in hemorrhage into individual lesions, as observed in our patient (Figure 2).

Adult colloid milium is diagnosed clinically and may mimic lichen or systemic amyloidosis, syringomas, lipoid proteinosis, molluscum contagiosum, steatocystoma multiplex, and sarcoidosis.<sup>2</sup>

Biopsy often is helpful in determining the diagnosis. Histopathology reveals amorphous eosinophilic deposits with fissures in the papillary dermis. These deposits are thought to be remnants of degenerated elastic fibers. Stains often are helpful, as the deposits are weakly



**FIGURE 1.** Histopathology revealed collections of amorphous eosinophilic material and fissures in the papillary dermis with sparing of the dermoepidermal junction (H&E, original magnification  $\times 40$ ).



**FIGURE 2.** Few hemorrhagic papules from mechanical trauma within a large collection of flesh-colored to translucent, dome-shaped papules on the left hand.

apple-green birefringent on Congo red stain and are periodic acid–Schiff and thioflavin T positive. Laminin and type IV collagen stains are negative with adult colloid milium but are positive with amyloidosis and lipoid proteinosis.<sup>3</sup> Electron microscopy also may help distinguish between amyloidosis and adult colloid milium, as these conditions may have a similar histologic appearance.

Treatment has not proven to be consistently helpful, as cryotherapy and dermabrasion have been the mainstay of treatment, often with disappointing results.<sup>4</sup> Laser treatment has been shown to be of some benefit in treating these lesions.<sup>2</sup>

### REFERENCES

1. Touart DM, Sau P. Cutaneous deposition diseases. part I. *J Am Acad Dermatol.* 1998;39(2, pt 1):149-171.
2. Pourrabbani S, Marra DE, Iwasaki J, et al. Colloid milium: a review and update. *J Drugs Dermatol.* 2007;6:293-296.
3. Calonje JE, Brenn T, Lazar A, et al. *McKee's Pathology of the Skin.* 4th ed. Philadelphia, PA: Saunders; 2012.
4. Netscher DT, Sharma S, Kinner BM, et al. Adult-type colloid milium of hands and face successfully treated with dermabrasion. *South Med J.* 1996;89:1004-1007.