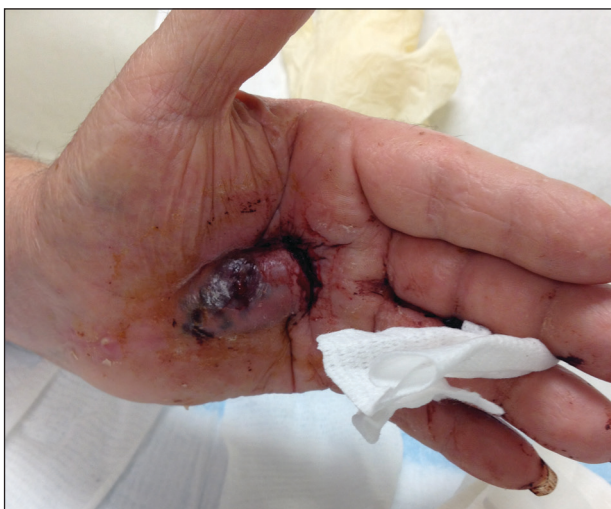

# Bleeding Hand Mass in an Older Man

Artem M. Sergeyenko, MD; Leigh Stone, MD; Marylee Braniecki, MD; Iris K. Aronson, MD



A 72-year-old man presented for evaluation of a mass on the left hand that continued to grow over the last few months and eventually bled. The patient first noticed a small firm lump on the palm approximately 1 year prior to presentation, and it was originally diagnosed as a Dupuytren contracture by his primary care physician. Months later, the lesion grew and began to bleed. Magnetic resonance imaging showed large hematomas of the hand with areas of nodular enhancement. The mass was located between the third and fourth proximal phalanges and abutted the extensor tendon. Complete excision yielded a definitive diagnosis.

## WHAT'S THE DIAGNOSIS?

- a. epithelioid angiosarcoma
- b. epithelioid hemangioendothelioma
- c. epithelioid sarcoma
- d. glomangiosarcoma
- e. melanoma

PLEASE TURN TO **PAGE E11** FOR THE DIAGNOSIS

From the University of Illinois at Chicago. Drs. Sergeyenko and Aronson are from the Department of Dermatology and Dr. Braniecki is from the Department of Pathology. Dr. Stone also is in private practice, Richmond, Indiana. The authors report no conflict of interest.

Correspondence: Artem M. Sergeyenko, MD, University of Illinois at Chicago, Department of Dermatology, M/C 624, 808 S Wood St, 380 CME, Chicago, IL 60612-7307 (a.serge04@gmail.com).

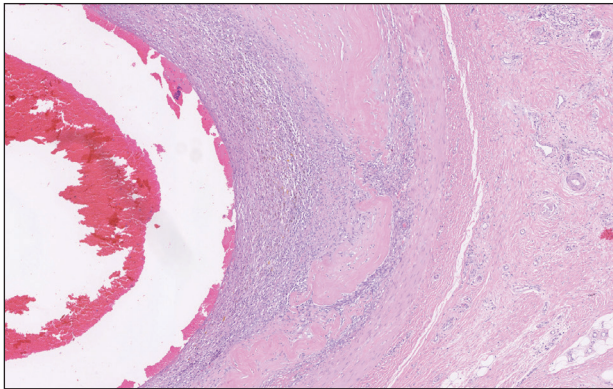
## THE DIAGNOSIS: Epithelioid Angiosarcoma

**H**istopathology showed a large soft-tissue neoplasm with extensive hemorrhage (Figure 1). The epithelioid angiosarcoma (EA) consisted mostly of irregular slit-shaped vessels lined by sheets of atypical endothelial cells (Figure 2). At higher-power magnification, the cellular atypia was prominent and diffuse (Figure 3). Immunostaining of the tumor cells showed positive uptake for CD31, confirming vascular origin (Figure 4). Other vascular markers, including CD34 and factor VIII, as well as nuclear positivity for the erythroblast transformation–specific transcription factor gene, *ERG*, can be demonstrated by EA. Irregular, smooth muscle actin–positive spindle cells are distributed around some of the vessels. The human herpesvirus 8 stain is negative.

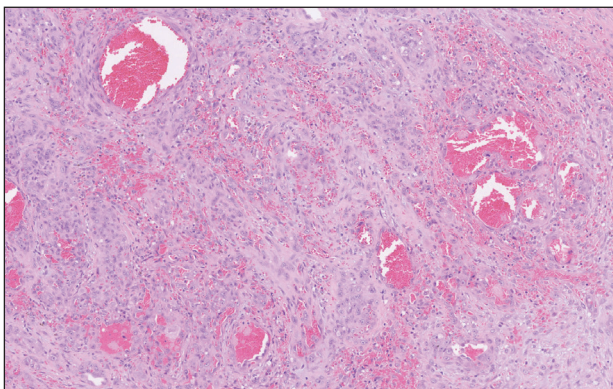
Compared to classic angiosarcomas, EAs have a predilection for the extremities rather than the head and scalp. Histopathologically, the cells are epithelioid and

are strongly positive for vimentin and CD31, in addition to factor VIII, friend leukemia integration 1 transcription factor, and CD34.<sup>1,2</sup> In contrast, epithelioid sarcomas more typically are seen in younger adults and less likely to be CD31 positive.<sup>3</sup> An epithelioid hemangioendothelioma is more focal in cellular atypia and forms small nests and trabeculae rather than sheets of atypical cells. Melanoma cells stain positive for human melanoma black 45, Melan-A, and S-100 but not for CD31.<sup>3</sup> Glomangiosarcomas typically stain positive for smooth muscle actin and muscle-specific actin.<sup>4</sup>

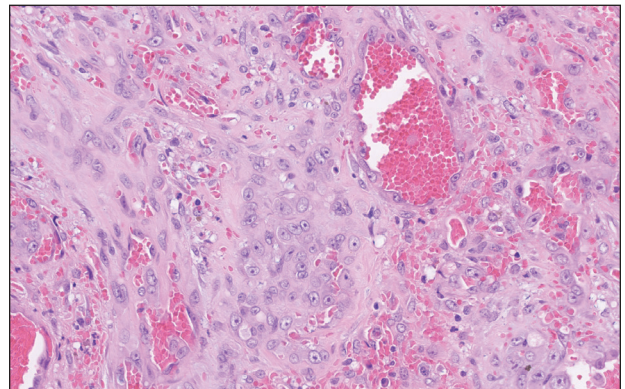
Epithelioid angiosarcomas are rare and aggressive malignancies of endothelial origin.<sup>3</sup> They are more prevalent in men and have a peak incidence in the seventh decade of life. They most commonly occur in the deep soft tissues of the extremities but have been reported to form in a variety of primary sites, including the skin, bones, thyroid, and adrenal glands.<sup>3</sup>



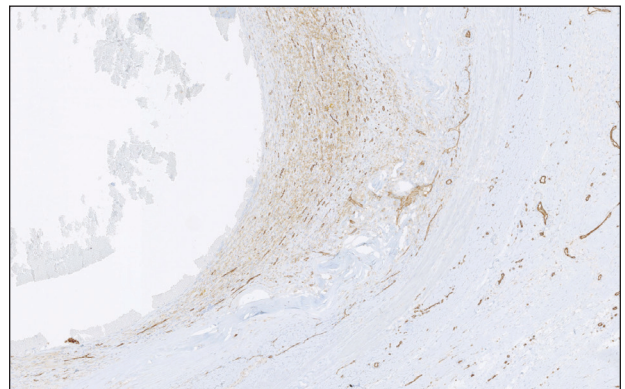
**FIGURE 1.** A large soft-tissue neoplasm with extensive hemorrhage (H&E, original magnification  $\times 5$ ).



**FIGURE 2.** The tumor consisted of a sheet of cells and focal areas of irregular slit-shaped vessel formation (H&E, original magnification  $\times 10$ ).



**FIGURE 3.** Cells were atypical and polygonal with eccentric nuclei, prominent nucleoli, and abundant eosinophilic cytoplasm, consistent with epithelioid cells (H&E, original magnification  $\times 30$ ).



**FIGURE 4.** Immunostaining of the epithelioid cells was focally positive for CD31 (original magnification  $\times 5$ ).

Tumors tend to be highly aggressive and demonstrate early nodal and solid organ metastases.<sup>3</sup> Our case demonstrated the aggressive nature of this high-grade malignancy by showing neoplastic invasion through a vascular wall. Within 2 to 3 years of diagnosis, 50% of patients die of the disease, and the 5-year survival rate is estimated to be 12% to 20%.<sup>3,5</sup> The etiology remains unknown, but EA has been linked to prior exposure to toxic chemicals, irradiation, or Thorotrast contrast media, and it may arise in the setting of arteriovenous fistulae and chronic lymphedema.<sup>6</sup>

Although radiation therapy often is utilized, surgery is the primary treatment modality.<sup>5</sup> Even with wide excision, local recurrence is common. Tumor size is one of the most important prognostic features, with a worse prognosis for tumors larger than 5 cm. Evidence suggests that paclitaxel-based chemotherapeutic regimens may improve survival, and a combination of paclitaxel and sorafenib has been reported to induce remission in metastatic angiosarcoma of parietal EA.<sup>5</sup> Currently, no standardized treatment regimen for this condition exists.

*Acknowledgment*—The authors thank Amanda Marsch, MD (Chicago, Illinois), for obtaining outside pathology consultation.

#### REFERENCES

1. Suchak R, Thway K, Zelger B, et al. Primary cutaneous epithelioid angiosarcoma: a clinicopathologic study of 13 cases of a rare neoplasm occurring outside the setting of conventional angiosarcomas and with predilection for the limbs. *Am J Surg Pathol*. 2011;35:60-69.
2. Prescott RJ, Banerjee SS, Eyden BP, et al. Cutaneous epithelioid angiosarcoma: a clinicopathological study of four cases. *Histopathology*. 1994;25:421-429.
3. Hart J, Mandavilli S. Epithelioid angiosarcoma: a brief diagnostic review and differential diagnosis. *Arch Pathol Lab Med*. 2011; 135:268-272.
4. Maselli AM, Jambhekar AV, Hunter JG. Glomangiosarcoma arising from a prior biopsy site. *Plast Reconstr Surg Glob Open*. 2017;5:e1219.
5. Donghi D, Dummer R, Cozzio A. Complete remission in a patient with multifocal metastatic cutaneous angiosarcoma with a combination of paclitaxel and sorafenib. *Br J Dermatol*. 2010;162:697-699.
6. Wu J, Li X, Liu X. Epithelioid angiosarcoma: a clinicopathological study of 16 Chinese cases. *Int J Clin Exp Pathol*. 2015;8:3901-3909.