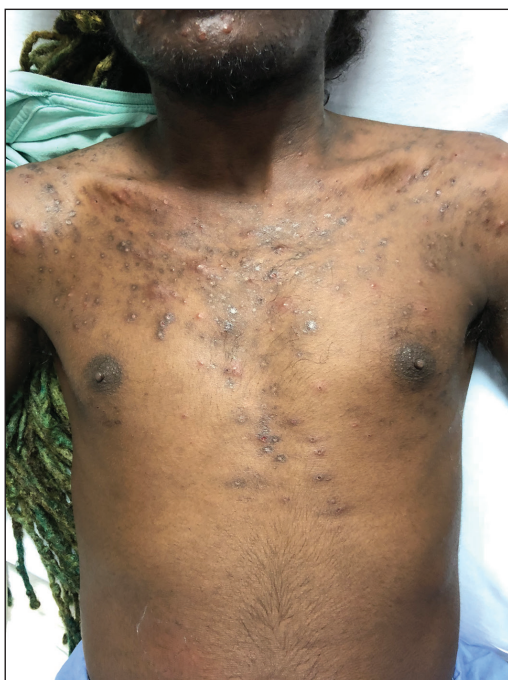
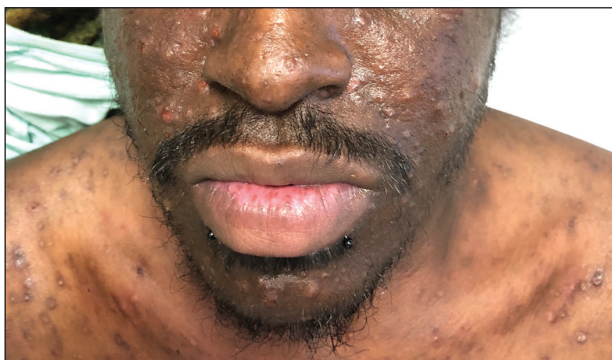
Pruritic Papules on the Face and Chest

Gabrielle E. Bailey, MD; Adnan Kurtović, MD; Daniel J. Aires, MD; Anand Rajpara, MD



A 31-year-old man presented with a severely pruritic rash of 2 weeks' duration. Physical examination revealed numerous urticarial papules and rare erythematous pustules over the face (top), upper chest (bottom), and proximal arms; most lesions were excoriated. Additionally, there were numerous hyperpigmented papules with central hypopigmentation on the upper chest and arms. The lower half of the body was spared. His medical history was notable for human immunodeficiency virus/AIDS with a prior episode of *Pneumocystis* pneumonia. He had been noncompliant with antiretroviral therapy for the last 2 years but restarted therapy 3 weeks prior to presentation. Laboratory test results revealed a CD4 cell count of 13 cells/mm³ (reference range, 500–1500 cells/mm³) with a viral load of 179 copies/mL (reference range, undetectable).

WHAT'S THE DIAGNOSIS?

- acne vulgaris
- disseminated fungal infection
- eosinophilic folliculitis
- nodular scabies
- papular urticaria

PLEASE TURN TO **PAGE E17** FOR THE DIAGNOSIS

From the University of Kansas, Kansas City. Dr. Bailey is from the School of Medicine. Drs. Kurtović, Aires, and Rajpara are from the Department of Dermatology.

The authors report no conflict of interest.

Correspondence: Adnan Kurtović, MD, Department of Dermatology, University of Kansas, 3901 Rainbow Blvd, Kansas City, KS 66160 (kurtovic.beban.adnan@gmail.com).

THE DIAGNOSIS: Eosinophilic Folliculitis

A shave biopsy specimen of an intact pustule on the left side of the chest was obtained. Histopathologic examination revealed follicular inflammation with copious eosinophils (Figure, A and B). Based on the histopathology and clinical presentation, a diagnosis of human immunodeficiency virus (HIV)-associated eosinophilic folliculitis (EF) was made.

The patient was started on triamcinolone ointment 0.1% twice daily to active lesions, oral cetirizine 10 mg in the morning, and oral hydroxyzine 25 mg at bedtime. Laboratory evaluation at the time of diagnosis showed eosinophilia with a peripheral blood eosinophil count of 0.5 K/ μ L (reference range, 0.03–0.48 K/ μ L).

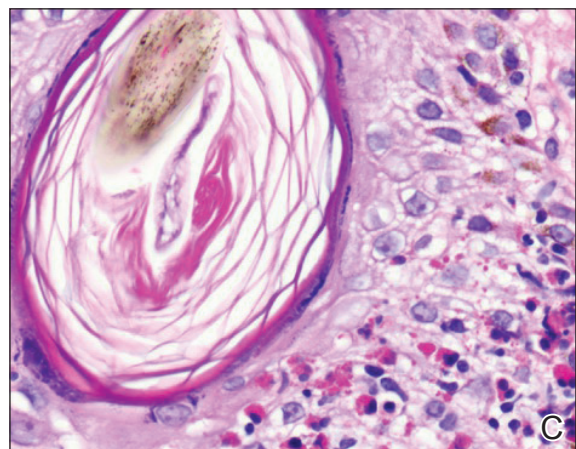
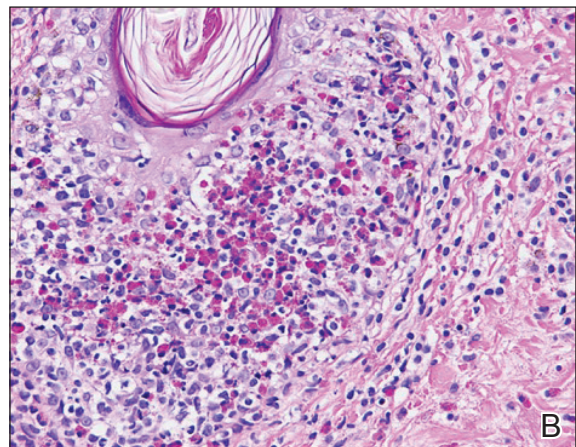
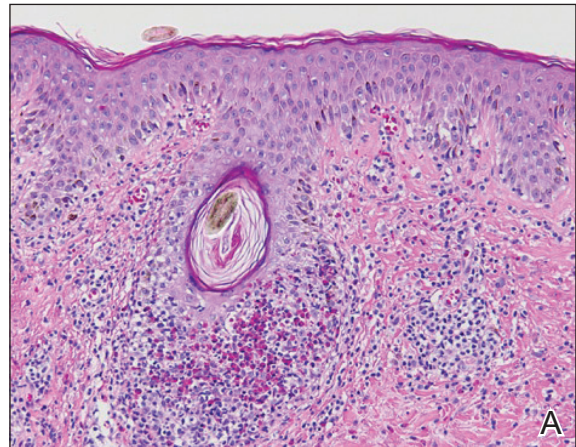
Human immunodeficiency virus-associated EF is a pruritic follicular eruption that occurs in HIV-positive individuals with advanced disease. Clinically, it is characterized by intermittent, urticarial, red or flesh-colored, 2- to 5-mm papules with sparse pustules involving the head, neck, arms, and upper trunk.^{1,2} The cardinal clinical feature of the disorder is intense pruritus, with overlying crusts and excoriations present on physical examination.³

Patients usually have a CD4 count of less than 250 cells/mm³.^{2,3} Patients with HIV can develop an exacerbation of EF in the first 3 to 6 months after initiating antiretroviral therapy. This clinical pattern is believed to be due to the reconstituted immune system and increased circulation of inflammatory cells.⁴ Peripheral eosinophilia and elevated serum IgE levels are found in 25% to 50% of patients with HIV-associated EF.^{2,3}

Clinically, the differential diagnosis of intensely pruritic papules with excoriations should include scabies.³ Other diagnoses to consider include opportunistic infections and papular urticaria.⁵ Acne vulgaris and *Demodex* folliculitis also may present with lesions similar to HIV-associated EF; however, these lesions tend not to be as intensely pruritic.^{1,5}

The etiology of HIV-associated EF is unknown.³ One proposed mechanism involves a hypersensitivity reaction to *Pityrosporum* or *Demodex* mite fragments, as evidenced by studies that found fragments of these microorganisms in biopsied lesions of HIV-associated EF.^{3,6} In our patient's histopathology, it was noted that the afflicted hair follicle held a single *Demodex* mite (Figure, C).

The histopathology is characterized by a perifollicular inflammatory infiltrate of eosinophils and CD8⁺ lymphocytes with areas of sebaceous lysis.^{3,6} Spongiosis of the follicular epithelium is seen in early lesions of HIV-associated EF.⁶



A, Follicular inflammation with copious eosinophils (H&E, original magnification $\times 100$). B, Eosinophils infiltrated the lower segment of the follicular infundibulum (H&E, original magnification $\times 200$). C, A pigmented hair fiber and a *Demodex* mite in the follicular canal (H&E, original magnification $\times 400$).

The first-line treatment of HIV-associated EF includes antiretroviral therapy with topical steroids and antihistamines. Human immunodeficiency virus-associated EF improves as CD4 helper T-cell counts rise above 250 cells/mm³ with continued antiretroviral therapy, though it initially can cause a flare of the condition.⁴ High-potency steroids and antihistamines are added during this period to treat the severe pruritus.^{1,7} In particular, daily cetirizine has been shown to be effective, which may be due to its ability to block eosinophil migration in addition to H₁-receptor antagonist properties.^{3,7}

Various alternative therapies have been described in case reports and case series; however, there have been no controlled studies comparing therapies. Phototherapy with UVB light 3 times weekly for 3 to 6 weeks has been effective and curative in recalcitrant cases.⁷ Other frequently used treatments include oral metronidazole, oral itraconazole, and permethrin cream 5%. The effectiveness of the latter 2 treatments is believed to be related to the proposed role of *Pityrosporum* and *Demodex* in the pathogenesis.³

Acknowledgment—The authors thank Garth Fraga, MD (Kansas City, Kansas), for his help compiling the histopathological images and their diagnostic descriptions.

REFERENCES

1. Parker SR, Parker DC, McCall CO. Eosinophilic folliculitis in HIV-infected women: case series and review. *Am J Clin Dermatol*. 2006;7:193-200.
2. Rosenthal D, LeBoit PE, Klumpp L, et al. Human immunodeficiency virus-associated eosinophilic folliculitis: a unique dermatosis associated with advanced human immunodeficiency virus infection. *Arch Dermatol*. 1991;127:206-209.
3. Fearfield LA, Rowe A, Francis N, et al. Itchy folliculitis and human immunodeficiency virus infection: clinicopathological and immunological features, pathogenesis, and treatment. *Br J Dermatol*. 1999;141:3-11.
4. Rajendran PM, Dolev JC, Heaphy MR, et al. Eosinophilic folliculitis: before and after the introduction of antiretroviral therapy. *Arch Dermatol*. 2005;141:1227-1231.
5. Nervi SJ, Schwartz RA, Dmochowski M. Eosinophilic pustular folliculitis: a 40 year retrospect. *J Am Acad Dermatol*. 2006;55:285-289.
6. McCalmont TH, Altemus D, Maurer T, et al. Eosinophilic folliculitis: the histological spectrum. *Am J Dermatopathol*. 1995;17:439-446.
7. Ellis E, Scheinfeld N. Eosinophilic pustular folliculitis: a comprehensive review of treatment options. *Am J Clin Dermatol*. 2004;5:189-197.