

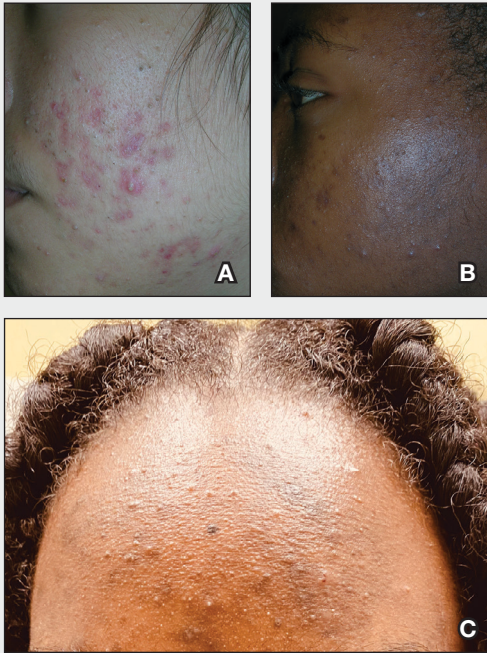
Dx ACROSS THE SKIN COLOR SPECTRUM



Candrice R. Heath, MD
Assistant Professor, Department of Dermatology
Lewis Katz School of Medicine
Temple University
Philadelphia, Pennsylvania



Richard P. Usatine, MD
Professor, Family and Community Medicine
Professor, Dermatology and Cutaneous Surgery
University of Texas Health
San Antonio



Photographs courtesy of Richard P. Usatine, MD.

THE COMPARISON

- A** A 27-year-old Hispanic woman with comedonal and inflammatory acne. Erythema is prominent around the inflammatory lesions. Note the pustule on the cheek surrounded by pink color.
- B** A teenaged Black boy with acne papules and pustules on the face. There are comedones, hyperpigmented macules, and pustules on the cheek.
- C** A teenaged Black girl with pomade acne. The patient used various hair care products, which obstructed the pilosebaceous units on the forehead.

The authors report no conflict of interest.
doi:10.12788/cutis.0339

Simultaneously published in *Cutis* and *The Journal of Family Practice*.

Acne Vulgaris

Epidemiology

Acne is a leading dermatologic condition in individuals with skin of color in the United States.¹

Key clinical features in people with darker skin tones include:

- erythematous or hyperpigmented papules or comedones
- hyperpigmented macules and postinflammatory hyperpigmentation (PIH)
- increased risk for keloidal scars.²

Worth noting

- Patients with darker skin tones may be more concerned with the dark marks (also referred to as scars or *manchas* in Spanish) than the acne itself. This PIH may be viewed by patients as the major problem.
- Acne medications such as azelaic acid and some retinoids (when applied appropriately) can treat both acne and PIH.³
- Irritation from topical acne medications, including retinoid dermatitis, may lead to more PIH. Using noncomedogenic moisturizers and applying medication appropriately (ie, a pea-sized amount of topical retinoid per application) may help limit irritation.^{4,5}
- One type of acne seen more commonly, although not exclusively, in Black patients is pomade acne, which principally appears on the forehead and is associated with use of hair care and styling products (Figure, C).

Health disparity highlight

Disparities in access to health care exist for those with dermatologic concerns. According to one study, African American (28.5%) and Hispanic patients (23.9%) were less likely to be seen by a dermatologist solely for the diagnosis of a dermatologic condition compared to Asian and Pacific Islander patients (36.7%) or White patients (43.2%).¹

Noting that isotretinoin is the most potent systemic therapy for severe cystic acne vulgaris, Bell et al⁶ reported that Black patients had lower odds of receiving isotretinoin compared to White patients. Hispanic patients had lower odds of receiving a topical retinoid, tretinoin, than non-Hispanic patients.⁶

REFERENCES

1. Davis SA, Narahari S, Feldman SR, et al. Top dermatologic conditions in patients of color: an analysis of nationally representative data. *J Drugs Dermatol*. 2012;11:466-473.
2. Alexis AF, Woolery-Lloyd H, Williams K, et al. Racial/ethnic variations in acne: implications for treatment and skin care recommendations for acne patients with skin of color. *J Drugs Dermatol*. 2021;20:716-725.
3. Woolery-Lloyd HC, Keri J, Doig S. Retinoids and azelaic acid to treat acne and hyperpigmentation in skin of color. *J Drugs Dermatol*. 2013;12:434-437.
4. Grayson C, Heath C. Tips for addressing common conditions affecting pediatric and adolescent patients with skin of color [published online March 2, 2021]. *Pediatr Dermatol*. doi:10.1111/pde.14525
5. Alexis AD, Harper JC, Stein Gold L, et al. Treating acne in patients with skin of color. *Semin Cutan Med Surg*. 2018;37(suppl 3):S71-S73.
6. Bell MA, Whang KA, Thomas J, et al. Racial and ethnic disparities in access to emerging and frontline therapies in common dermatological conditions: a cross-sectional study. *J Natl Med Assoc*. 2020;112:650-653.