

Intralymphatic Histiocytosis Treated With Intralesional Triamcinolone Acetonide and Pressure Bandage

Jonathan M. Soh, MD; Glynis A. Scott, MD; Theodore I. Hirokawa, MD; Lindsey B. Dolohanty, MD

PRACTICE POINTS

- Intralymphatic histiocytosis is a rare disorder often associated with rheumatic arthritis and joint prostheses.
- The diagnosis is made by histopathology as well as D2-40 and CD68 immunostaining.
- While there is no gold standard of treatment for intralymphatic histiocytosis, intralesional triamcinolone proved efficacious in this case with prolonged results.

Intralymphatic histiocytosis is a rare disorder associated with a variety of inflammatory conditions. We report the case of an 89-year-old woman with a history of a right knee replacement and a ruptured popliteal cyst who developed an erythematous indurated plaque over the surgical scar. Histopathology revealed fibrosis, chronic inflammation, and histiocytes within the lymphatics consistent with intralymphatic histiocytosis. The plaque flattened following intralesional injection of triamcinolone acetonide 10 mg/cc × 1.6 cc once monthly for 2 consecutive months and application of a pressure bandage, with no recurrence after 4 months. This treatment may be useful for recalcitrant disease.

Cutis. 2018;101:E1-E4.

Intralymphatic histiocytosis was first described in 1994.¹ To date, at least 70 cases have been reported in the English-language literature, the majority being associated with systemic or local inflammatory conditions such as rheumatoid arthritis (RA), malignancy, and metal prostheses. The remaining cases arose independent of any detectable disease process.² The clinical lesion localizes to areas around surgical scars or inflamed joints and generally presents with erythematous livedoid papules and plaques. Because of its rarity, pathologists and clinicians may be unfamiliar with this entity, leading to delayed or missed diagnoses.

Although the pathogenesis of intralymphatic histiocytosis remains unclear, it may be related to dysregulated immune signaling. The condition follows a chronic, relapsing-remitting course that has shown variable response to topical and systemic treatments. We present a rare case of intralymphatic histiocytosis associated with joint replacement/metal prosthesis³⁻¹⁴ that was responsive to a novel treatment with intralesional steroid injection and pressure bandage.

Case Report

An 89-year-old woman presented with a relapsing and remitting rash on the right calf and popliteal fossa of 11 months' duration. It was becoming more painful over time and recently began to hurt when walking. Her medical history was remarkable for deep vein thromboses of the bilateral legs, Factor V Leiden deficiency, osteoarthritis, and a popliteal (Baker) cyst on the right leg that ruptured 22 months prior to presentation. Her surgical history included bilateral knee replacements (10 years and 2 years prior to the current presentation for the right and left knees, respectively). Her international normalized ratio (2.0) was therapeutic on warfarin.

Initially, swelling, pain, and redness developed in the right calf, and recurrent right-leg deep venous thrombosis was ruled out by Doppler ultrasound. The findings were considered to be secondary to inflammation from a popliteal cyst. Symptoms persisted despite application of warm compresses, leg elevation, and compression stockings. Treatment with doxycycline prescribed by the patient's primary care physician 9 months prior for presumed cellulitis produced little improvement. Physical examination revealed a well-healed vertical scar on the right calf from an incisional biopsy within an 8-cm, tender, erythematous, indurated, sclerotic plaque with erythematous streaks radiating from the center of the plaque (Figure 1). There also was red-brown, indurated discoloration on the right shin.

From the University of Rochester School of Medicine and Dentistry, New York. Drs. Soh, Scott, and Dolohanty are from the Department of Dermatology. Dr. Scott also is from the Department of Pathology. Dr. Hirokawa is from the Department of Surgery.

The authors report no conflict of interest.

Correspondence: Lindsey B. Dolohanty, MD, 990 South Ave, Ste 206, Rochester, NY 14642 (Lindsey_dolohanty@urmc.rochester.edu).

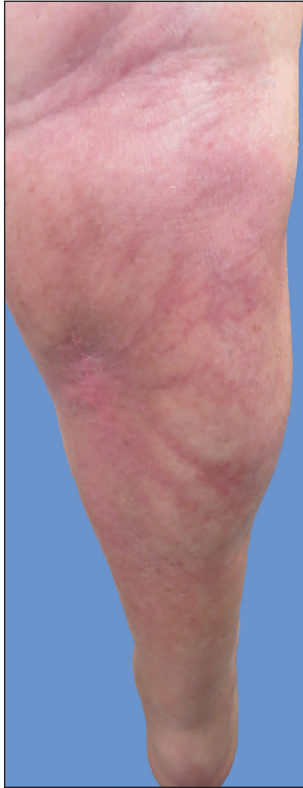

FIGURE 1. Well-healed vertical scar with 8-cm plaque of radiating erythema, induration, and sclerosis on the right calf, characteristic of intralymphatic histiocytosis.

Fine-needle aspiration of the lesion revealed red blood cells and histiocytes. Laboratory studies showed an elevated erythrocyte sedimentation rate of 74 mm/h (reference range, 0–30 mm/h) and a C-reactive protein level of 39 mg/L (reference range, 0–10 mg/L). An incisional biopsy including the muscular fascia showed dense dermal fibrosis with chronic inflammation and scarring. A dermatopathologist (G. A. S.) reviewed the case and confirmed variable fibrosis and chronic inflammation associated with edema in the dermis and epidermal acanthosis. Inspection of vessels in the mid to upper dermis in one area revealed stellate, thin-walled, vascular structures that contained bland epithelioid cells lining the lumen as well as packed within the vessels. The epithelioid cells did not show atypia or mitotic figures, and they did not show intracytoplasmic vacuoles (Figure 2). Immunocytochemical staining for D2-40 was strongly positive in cells lining the vessels, consistent with lymphatics (Figure 3). CD68 immunohistochemistry for histiocytes stained the cells within the lymphatics (Figure 4). A diagnosis of intralymphatic histiocytosis was made.

Intralesional triamcinolone acetonide 10 mg/cc×1.6 cc was injected into the plaque once monthly for 2 consecutive months, and daily compression with a pressure bandage of the right lower leg was initiated. Four months after the first treatment with this regimen, the plaque

was smaller and no longer sclerotic or painful, and the erythema was markedly reduced (Figure 5). Clinical and symptomatic improvement continued at 1-year follow-up.

Comment

Intralymphatic histiocytosis is a rare cutaneous disorder defined histologically by histiocytes within the lumina of lymphatics. In addition to the current case, our review of PubMed articles indexed for MEDLINE using the search term *intralymphatic histiocytosis* yielded more than 70 total cases. The condition has a slight female predominance and typically is seen in individuals over the age of 60 years (age range, 16–89 years).¹² Many cases are associated with RA/elevated rheumatoid factor.^{2,4,8,15–30} At least 9 cases of intralymphatic histiocytosis were associated with pre-malignant or malignant conditions (ie, adenocarcinoma of the breasts, lungs, and colon; Merkel cell carcinoma; melanoma; melanoma in situ; Mullerian carcinoma,

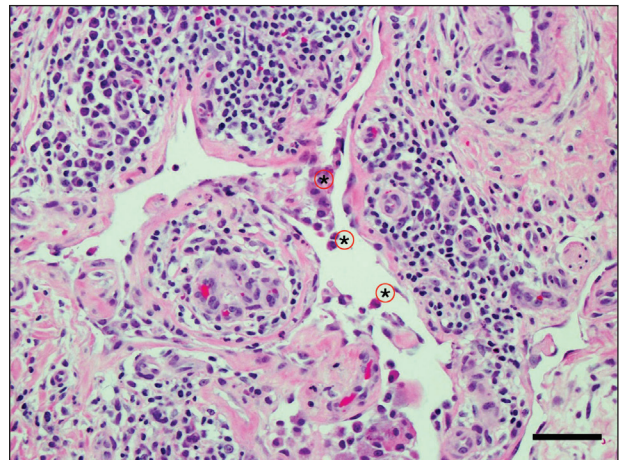


FIGURE 2. Excisional specimen from the right leg with thin-walled vessels packed with bland cells consistent with histiocytes (asterisks) (reference bar, ~40 μM)(H&E, original magnification ×200).

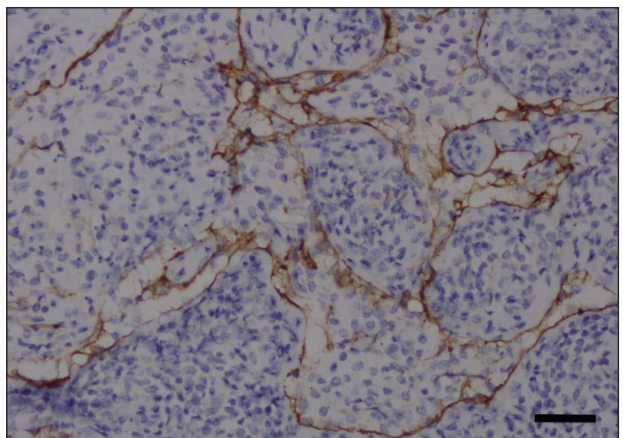


FIGURE 3. The cells lining the vascular spaces stained positively for D2-40, consistent with lymphatics (reference bar, ~40 μM)(original magnification ×200).

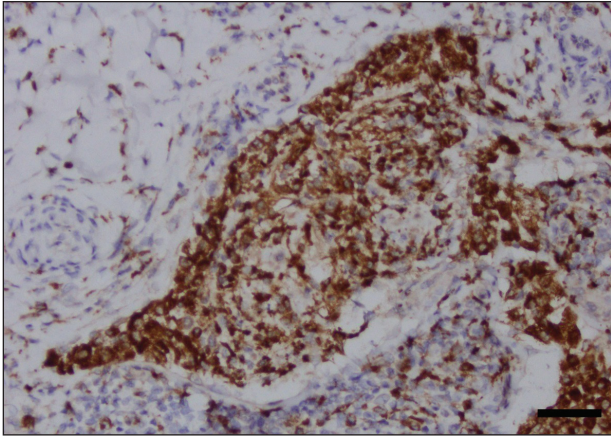


FIGURE 4. Histiocytes within the lumen of the lymphatics stained positively for CD68 (reference bar, ~40 μ M)(original magnification \times 200).

gammopathy).^{4,15,31-34} Primary disease, defined as occurring in patients who are otherwise healthy, was noted in at least 10 cases.^{1,2,4,12,35,36} Finally, intralymphatic histiocytosis was identified in areas adjacent to metal implants and joint replacements or exploration in approximately 15 cases (including the current case).^{3-14,29,37}

The condition presents with papules, plaques, and nodules in the setting of characteristic livedoid discoloration; however, some patients present with nonspecific nodules or plaques. Lesions may be symptomatic (eg, pruritic, tender) or asymptomatic. The histologic features of intralymphatic histiocytosis are distinctive but may be focal, as in our case, and the diagnosis is easily missed. The histologic differential diagnosis includes diseases in which intravascular accumulations of cells may be seen, including intravascular B-cell lymphoma, which can be excluded with stains that detect B cells (CD20/CD79a), and reactive angioendotheliomatosis, a benign proliferation of endothelial cells, which may be excluded with stains against endothelial markers (CD31/CD34). The course typically is chronic, and treatment with topical steroids,^{3,9,15,22,26} cyclophosphamide,¹⁵ local radiation,¹ thalidomide,³⁵ pentoxifylline,⁷ and RA medications (eg, prednisolone, methotrexate, nonsteroidal anti-inflammatory drugs, hydroxychloroquine) generally are ineffective.^{2,16,20,25} Symptoms may improve with joint replacement,⁴ excision of the involved lesion, treatment of an associated malignancy/infection,^{33,36,38,39} nonsteroidal anti-inflammatory drugs, intra-articular steroid injection,¹⁸ amoxicillin and aspirin,¹⁹ infliximab,²⁵ pressure bandage application,²⁶ steroid-containing adhesive application,¹⁸ arthrocentesis,^{3,27} oral pentoxifylline,²¹ tacrolimus,²⁹ CO₂ laser,⁴⁰ prednisolone,⁴¹ and tocilizumab.²⁸ Treatment of associated RA is beneficial in rare cases.^{2,15,20,25,26}

The pathogenesis of intralymphatic histiocytosis has not been elucidated with certainty but may represent an abnormal proliferative response of histiocytes and vessels in response to chronic systemic or local inflammation.

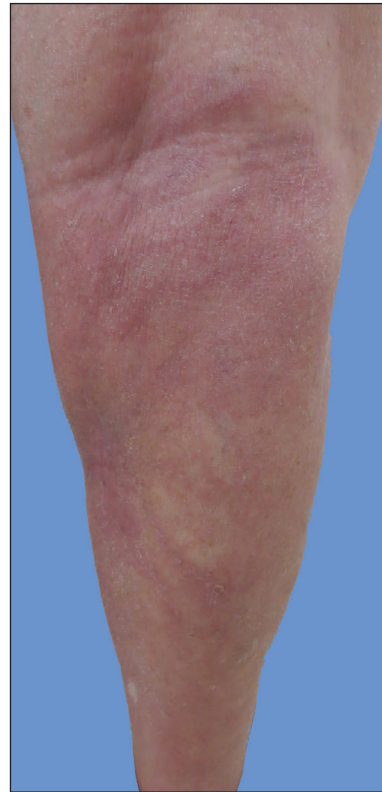


FIGURE 5. Site of the lesion 1 month after treatment with intralesional triamcinolone acetonide 10 mg/cc and daily pressure bandage wrapping for 2 months.

Lymphangiectasis caused by lymphatic obstruction secondary to trauma, surgical manipulation, or chronic inflammation can promote lymphostasis and slowed clearance of antigens producing an accumulation of histiocytes and subsequent local immunologic reactions, thus an “immunocompromised district” is formed.⁴² It also is thought that rheumatic or prosthetic joints produce inflammatory mediator-rich (namely tumor necrosis factor α) synovial fluid that drains and collects within the dilated lymphatics, creating a nidus for histiocytes.^{1,5} In one case, treatment with an anti-tumor necrosis factor antibody (infliximab) improved the skin presentation and rheumatoid joint pain.²⁵ Bakr et al² noted an association with increased intralymphatic macrophage HLA-DR expression. This T-cell surface receptor typically is upregulated in cases of chronic antigen stimulation and autoimmune conditions.

Conclusion

Our patient had a history of a joint prosthesis and a popliteal cyst, which could have altered lymphatic drainage promoting abnormal immune cell trafficking contributing to the development of intralymphatic histiocytosis. The response to intralesional steroids supports this pathogenic hypothesis. Specifically, direct injection of the area suppressed the immune dysregulation, while

compression lessened the degree of lymphostasis. In light of previously reported cases of intralymphatic histiocytosis in association with metal implants,³⁻⁹ we suggest that the condition should be considered in patients with chronic painful livedoid nodules or plaques around an affected joint, even in the absence of RA. The dermatopathologist should be warned to search carefully for the subtle but distinctive histologic features of the disease that confirm the diagnosis. Treatment with intralesional triamcinolone acetonide with an overlying pressure wrap has minimal side effects and can work quickly with sustained benefits.

REFERENCES

- O'Grady JT, Shahidullah H, Doherty VR, et al. Intravascular histiocytosis. *Histopathology*. 1994;24:265-268.
- Bakr F, Webber N, Fassihi H, et al. Primary and secondary intralymphatic histiocytosis [published online January 17, 2014]. *J Am Acad Dermatol*. 2014;70:927-933.
- Watanabe T, Yamada N, Yoshida Y, et al. Intralymphatic histiocytosis with granuloma formation associated with orthopaedic metal implants [published online November 10, 2007]. *Br J Dermatol*. 2008;158:402-404.
- Requena L, El-Shabrawi-Caelen L, Walsh SN, et al. Intralymphatic histiocytosis. a clinicopathologic study of 16 cases. *Am J Dermatopathol*. 2009;31:140-151.
- Grekin S, Mesfin M, Kang S, et al. Intralymphatic histiocytosis following placement of a metal implant. *J Cutan Pathol*. 2011;38:351-353.
- Rossari S, Scatena C, Gori A, et al. Intralymphatic histiocytosis: cutaneous nodules and metal implants [published online March 6, 2011]. *J Cutan Pathol*. 2011;38:534-535.
- de Unamuno Bustos B, García Rabasco A, Ballester Sánchez R, et al. Erythematous indurated plaque on the right upper limb. intralymphatic histiocytosis (IH) associated with orthopedic metal implant. *Int J Dermatol*. 2013;52:547-549.
- Chiu YE, Maloney JE, Bengana C. Erythematous patch overlying a swollen knee—quiz case. intralymphatic histiocytosis. *Arch Dermatol*. 2010;146:1037-1042.
- Saggar S, Lee B, Krivo J, et al. Intralymphatic histiocytosis associated with orthopedic implants. *J Drugs Dermatol*. 2011;10:1208-1209.
- Bidier M, Hamsch C, Kutzner H, et al. Two cases of intralymphatic histiocytosis following hip replacement [published online June 9, 2015]. *J Dtsch Dermatol Ges*. 2015;13:700-702.
- Darling MD, Akin R, Tarbox MB, et al. Intralymphatic histiocytosis overlying hip implantation treated with pentoxifylline. *J Biol Regul Homeost Agents*. 2015;29(1 suppl):117-121.
- Demirkesen C, Kran T, Leblebici C, et al. Intravascular/intralymphatic histiocytosis: a report of 3 cases. *Am J Dermatopathol*. 2015;37:783-789.
- Gómez-Sánchez ME, Azaña-Defez JM, Martínez-Martínez ML, et al. Intralymphatic histiocytosis: a report of 2 cases. *Actas Dermosifiliogr*. 2018;109:E1-E5.
- Haitz KA, Chapman MS, Seidel GD. Intralymphatic histiocytosis associated with an orthopedic metal implant. *Cutis*. 2016;97:E12-E14.
- Rieger E, Soyer HP, Leboit PE, et al. Reactive angioendotheliomatosis or intravascular histiocytosis? an immunohistochemical and ultrastructural study in two cases of intravascular histiocytic cell proliferation. *Br J Dermatol*. 1999;140:497-504.
- Pruim B, Strutton G, Congdon S, et al. Cutaneous histiocytic lymphangitis: an unusual manifestation of rheumatoid arthritis. *Australas J Dermatol*. 2000;41:101-105.
- Magro CM, Crowson AN. The spectrum of cutaneous lesions in rheumatoid arthritis: a clinical and pathological study of 43 patients. *J Cutan Pathol*. 2003;30:1-10.
- Takiwaki H, Adachi A, Kohno H, et al. Intravascular or intralymphatic histiocytosis associated with rheumatoid arthritis: a report of 4 cases. *J Am Acad Dermatol*. 2004;50:585-590.
- Mensing CH, Krengel S, Tronnier M, et al. Reactive angioendotheliomatosis: is it "intravascular histiocytosis"? *J Eur Acad Dermatol Venereol*. 2005;19:216-219.
- Okazaki A, Asada H, Niizeki H, et al. Intravascular histiocytosis associated with rheumatoid arthritis: report of a case with lymphatic endothelial proliferation. *Br J Dermatol*. 2005;152:1385-1387.
- Catalina-Fernández I, Álvarez AC, Martín FC, et al. Cutaneous intralymphatic histiocytosis associated with rheumatoid arthritis: report of a case and review of the literature. *Am J Dermatopathol*. 2007;29:165-168.
- Nishie W, Sawamura D, Iitoyo M, et al. Intravascular histiocytosis associated with rheumatoid arthritis. *Dermatology*. 2008;217:144-145.
- Okamoto N, Tanioka M, Yamamoto T, et al. Intralymphatic histiocytosis associated with rheumatoid arthritis. *Clin Exp Dermatol*. 2008;33:516-518.
- Huang H-Y, Liang C-W, Hu S-L, et al. Cutaneous intravascular histiocytosis associated with rheumatoid arthritis: a case report and review of the literature. *Clin Exp Dermatol*. 2009;34:E302-E303.
- Sakaguchi M, Nagai H, Tsuji G, et al. Effectiveness of infliximab for intralymphatic histiocytosis with rheumatoid arthritis. *Arch Dermatol*. 2011;147:131-133.
- Washio K, Nakata K, Nakamura A, et al. Pressure bandage as an effective treatment for intralymphatic histiocytosis associated with rheumatoid arthritis. *Dermatology*. 2011;223:20-24.
- Kaneko T, Takeuchi S, Nakano H, et al. Intralymphatic histiocytosis with rheumatoid arthritis: possible association with the joint involvement. *Case Reports Clin Med*. 2014;3:149-152.
- Nakajima T, Kawabata D, Nakabo S, et al. Successful treatment with tocilizumab in a case of intralymphatic histiocytosis associated with rheumatoid arthritis. *Intern Med*. 2014;53:2255-2258.
- Tsujiwaki M, Hata H, Miyauchi T, et al. Warty intralymphatic histiocytosis successfully treated with topical tacrolimus. *J Eur Acad Dermatol Venereol*. 2015;29:2267-2269.
- Tanaka M, Funasaka Y, Tsuruta K, et al. Intralymphatic histiocytosis with massive interstitial granulomatous foci in a patient with rheumatoid arthritis. *Ann Dermatol*. 2017;29:237-238.
- Cornejo KM, Cosar EF, O'Donnell P. Cutaneous intralymphatic histiocytosis associated with lung adenocarcinoma. *Am J Dermatopathol*. 2016;38:568-570.
- Tran TAN, Tran Q, Carlson JA. Intralymphatic histiocytosis of the appendix and fallopian tube associated with primary peritoneal high-grade, poorly differentiated adenocarcinoma of Müllerian origin. *Int J Surg Pathol*. 2017;25:357-364.
- Echeverría-García B, Botella-Estrada R, Requena C, et al. Intralymphatic histiocytosis and cancer of the colon [in Spanish]. *Actas Dermosifiliogr*. 2010;101:257-262.
- Ergen EN, Zwerner JP. Cover image: intralymphatic histiocytosis with giant blanching violaceous plaques. *Br J Dermatol*. 2017;177:325-326.
- Wang Y, Yang H, Tu P. Upper facial swelling: an uncommon manifestation of intralymphatic histiocytosis. *Eur J Dermatol*. 2012;22:814-815.
- Rhee D-Y, Lee D-W, Chang S-E, et al. Intravascular histiocytosis without rheumatoid arthritis. *J Dermatol*. 2008;35:691-693.
- Gilchrist BA, Eller MS, Geller AC, et al. The pathogenesis of melanoma induced by ultraviolet radiation. *N Engl J Med*. 1999;340:1341-1348.
- Asagoe K, Torigoe R, Ofuji R, et al. Reactive intravascular histiocytosis associated with tonsillitis. *Br J Dermatol*. 2006;154:560-563.
- Pouryazdanparast P, Yu L, Dalton VK, et al. Intravascular histiocytosis presenting with extensive vulvar necrosis. *J Cutan Pathol*. 2009; (36 suppl 1):1-7.
- Reznitsky M, Daugaard S, Charabi BW. Two rare cases of laryngeal intralymphatic histiocytosis. *Eur Arch Otorhinolaryngol*. 2016;273:783-788.
- Fujimoto N, Nakanishi G, Manabe T, et al. Intralymphatic histiocytosis comprises M2 macrophages in superficial dermal lymphatics with or without smooth muscles. *J Cutan Pathol*. 2016;43:898-902.
- Piccolo V, Ruocco E, Russo T, et al. A possible relationship between metal implant-induced intralymphatic histiocytosis and the concept of the immunocompromised district. *Int J Dermatol*. 2014;53:E365.