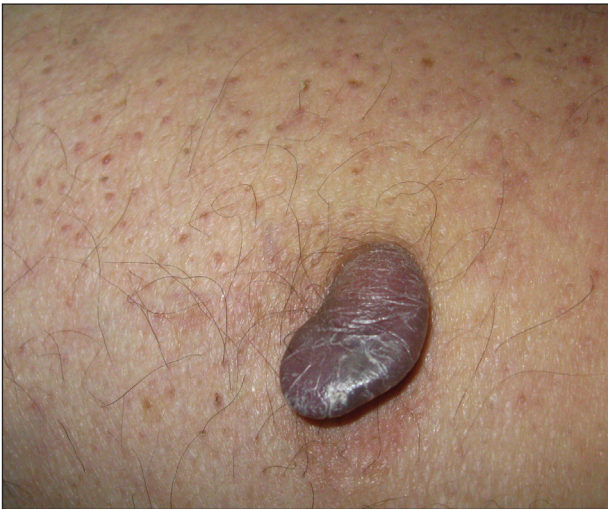

# Pigmented Peduncule on the Leg

Laura Catalina Arango Duque, MD; Africa Juárez Martín, MD; Beatriz Torio Sánchez, MD; María García Sánchez, MD; Cristina Bajo del Pozo, MD



A 68-year-old man with a history of type 2 diabetes mellitus and hypercholesterolemia presented to the dermatology department with a cutaneous lesion on the posterior aspect of the right thigh of 2 years' duration. The lesion had become larger during the 4 months prior to presentation and was mostly asymptomatic but became tender when subjected to trauma. Physical examination revealed a firm, 2-cm, slightly pigmented peduncule on the posterior right thigh. No lymphadenopathies were noted. The lesion was completely excised for histologic examination.

## WHAT'S THE DIAGNOSIS?

- a. acquired fibrokeratoma
- b. cutaneous leiomyoma
- c. fibroma
- d. polypoid dermatofibroma
- e. sclerotic fibroma

PLEASE TURN TO **PAGE E10** FOR THE DIAGNOSIS

From the Complejo Asistencial Universitario de Palencia, Spain. Drs. Arango Duque, Juárez Martín, García Sánchez, and Bajo del Pozo are from the Dermatology Department. Dr. Torio Sánchez is from the Pathology Department.

The authors report no conflict of interest.

Correspondence: Laura Catalina Arango Duque, MD, Avenida de los Donantes de Sangre s/n, 34005, Palencia, Spain (lauraarango9@hotmail.com).

## THE DIAGNOSIS: Polypoid Dermatofibroma

**H**istologic examination revealed a poorly demarcated lesion localized in the dermis that was composed of an admixture of fibroblastlike cells, histiocytes, siderophages, multinucleated giant cells, and hemorrhage (Figure). Based on these findings, a diagnosis of polypoid dermatofibroma (DF) was made. No further treatment was necessary because the lesion was completely excised.

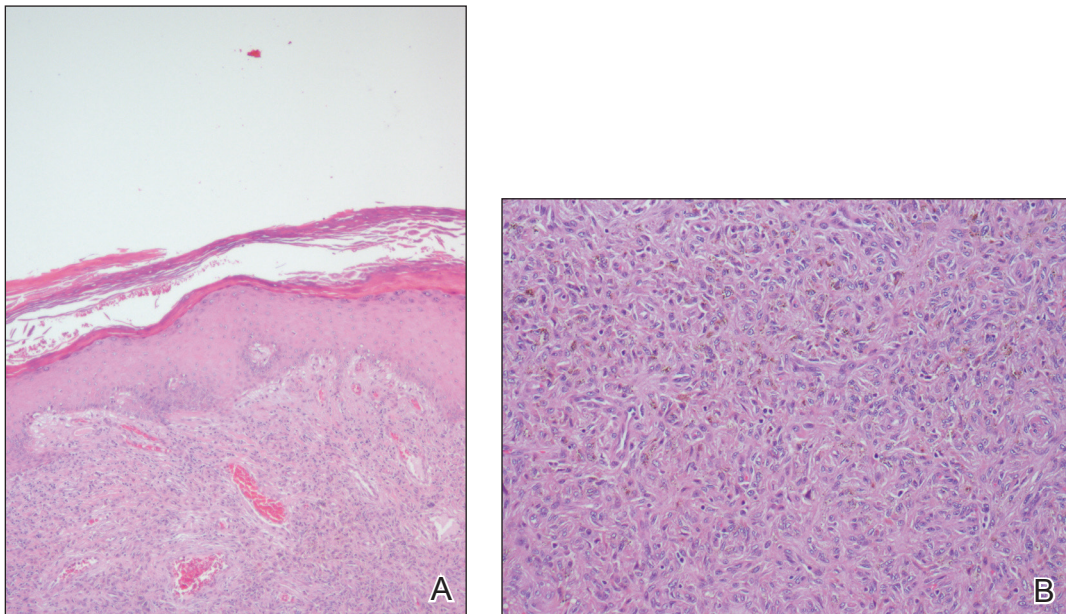
Dermatofibromas, also known as benign fibrous histiocytomas, are common, benign, mesenchymal, fibrosing tumors of the skin that appear predominantly on the legs in women, but any part of the body in either sex can be affected. Clinically, DFs show the dimple sign when laterally squeezed and can be painful spontaneously or when rubbed. Histologically, DFs are poorly demarcated lesions composed of a variable admixture of fibroblastlike cells, histiocytes (some of which may be xanthomatous or multinucleated), and blood vessels. The etiology still remains unclear. Most investigators consider DF to be a reactive process, but some think that it is a benign mesenchymal tumor.<sup>1,2</sup>

Many subtypes of DF have been described based on their unique architectural, cellular, stromal, and clinical features.<sup>2,3</sup> Polypoid DF is a rare variant that comprises only 3% of reported cases<sup>4</sup> and tends to be larger than

other DF subtypes. Requena et al<sup>5</sup> reported 12 cases of giant DF, another clinical subtype, that were larger than 5 cm in diameter, most of which had a polypoid appearance.

Moreover, 3 distinct variants of DF with unique histologic features tend to show polypoid morphology.<sup>3,4</sup> In epithelioid fibrous histiocytoma, also known as epithelioid cell histiocytoma, at least 50% of the lesion is composed of rounded or polygonal epithelioid cells with abundant eosinophilic cytoplasm and round to oval nuclei containing small eosinophilic nucleoli.<sup>4</sup> A grenz zone generally is lacking and numerous small blood vessels are a constant feature of epithelioid fibrous histiocytoma. The other variant of DF that also tends to have a polypoid appearance is lipidized fibrous histiocytoma, or ankle-type fibrous histiocytoma, which usually arises below the knee, especially around the ankle, and often becomes larger than common DF.<sup>4</sup> Lastly, atypical polypoid DF is a benign, polyp-shaped lesion that shows hypercellularity with striking nuclear atypism and scattered mitotic figures in addition to the ordinary histologic features of DF.<sup>3</sup>

Acquired fibrokeratomas manifest as solitary dome-shaped, flesh-colored protrusions usually located on the feet and hands. Sclerotic fibroma is a rare cutaneous neoplasm



Polypoid dermatofibroma presenting as a poorly demarcated lesion localized in the dermis composed of an admixture of fibroblastlike cells, histiocytes, siderophages, and multinucleated giant cells (A and B)(both H&E, original magnifications  $\times 4$  and  $\times 10$ ).

that presents as a solitary, translucent or waxy nodule or as multiple nodules when it is part of Cowden disease. Fibromas, also known as skin tags, are common cutaneous tumors that appear in intertriginous areas and frequently adopt a pedunculated morphology. Although clinically some of these lesions may resemble polypoid DF, the differential diagnosis is made by histologic examination.

Dermatofibroma is a common cutaneous tumor that follows a benign course. It can adopt multiple morphologies. Awareness of this rare variant may aid in its appropriate diagnosis and management. Dermatofibromas are benign neoplasms, and therefore they usually do not require treatment. If they become symptomatic or are

bothersome to the patient, the treatment of choice is surgical removal.

#### REFERENCES

1. Luzar B, Calonje E. Cutaneous fibrohistiocytic tumours—an update. *Histopathology*. 2010;56:148-165.
2. Santos-Briz A, Llamas-Velasco M, Arango L, et al. Cutaneous adenomatofibroma: report of 2 cases. *Am J Dermatopathol*. 2013;35:E103-E105.
3. Sogabe Y, Takahashi A, Tamura A, et al. A case of polypoid dermatofibroma. *J Dermatol*. 2002;29:786-789.
4. Kai H, Fujita H, Yamamoto M, et al. Polypoid dermatofibroma with a slim pedicle: a case report. *Dermatol Online J*. 2012;18:16.
5. Requena L, Farina K, Fuente C, et al. Giant dermatofibroma. a little known clinical variant of dermatofibroma. *J Am Acad Dermatol*. 1994;30:714-718.