

# Gone Fishing: A Unique Histologic Pattern in Cutaneous Angiosarcoma

Ashley P. Schmidt, BA; B. Joel Tjarks, MD; Douglas W. Lynch, MD

## PRACTICE POINTS

- The histologic finding of “fish in the creek” is characterized by free-floating or tufted pleomorphic spindle cells within the vascular lumen.
- Fish in the creek has only been demonstrated in cutaneous angiosarcoma when compared to histologic findings of other similar vascular malignancies.
- The fish-in-the-creek finding may be an additional diagnostic tool in cases of cutaneous angiosarcoma.

Cutaneous angiosarcoma is a rare but aggressive vascular malignancy that can present a diagnostic challenge due to a wide variety of clinical appearances and histologic features. Final diagnosis traditionally is yielded by corroborating the histologic and immunohistochemical findings with the clinical presentation; however, a histologic feature known as “fish in the creek,” which consists of free-floating or tufted pleomorphic spindle cells within the vascular lumen, may be an additional diagnostic clue. In this study, we aimed to determine the diagnostic utility of this finding in cutaneous angiosarcoma. Our results suggest that “fish in the creek” has the potential to be an additional useful diagnostic tool for an otherwise challenging and deceptive malignancy.

*Cutis*. 2018;101:270-272.

Cutaneous angiosarcoma is a rare malignant tumor of vascular endothelial cells that has the propensity to arise in various clinical settings. This tumor predominantly occurs in the head and neck region in elderly patients, but it also has been reported to develop postradiotherapy or in the setting of chronic lymphedema in the extremities.<sup>1-3</sup> In all settings, the diagnosis carries a very poor prognosis with a high likelihood of local recurrence and rapid dissemination. The mortality rate typically is 80% or higher.<sup>2,4-6</sup>

Making the correct clinical diagnosis of cutaneous angiosarcoma may be difficult given the variety of patient

symptoms and clinical appearances that can be demonstrated on presentation. Lesions can appear as bluish or violaceous plaques, macules, or nodules, and ulceration may be present in some advanced cases.<sup>5,7</sup> Clinical misdiagnosis is common, as cutaneous angiosarcomas may be mistaken for infectious processes, benign vascular malformations, and other cutaneous malignancies.<sup>1</sup> Biopsy often is delayed given the initial benign appearance of the lesions, and this frequently results in aggressive and extensive disease at the time of diagnosis, which is unfortunate given that small tumor size has been shown to be one of the only favorable prognostic indicators in cutaneous angiosarcoma.<sup>1,2,6,8</sup>

Microscopically, diagnosis of cutaneous angiosarcoma can present a challenge, as the histology varies between a well-differentiated vascular neoplasm and a considerably anaplastic and poorly differentiated malignancy. On low power, some areas may appear as benign hemangiomas with other areas showing frank sarcomatous features.<sup>9</sup> As a result, these tumors can be mistaken for a variety of other diseases including melanomas, carcinomas, or other vascular tumors.<sup>6,8,9</sup> Previously, electron microscopy has been utilized on undifferentiated tumors to help distinguish cutaneous angiosarcomas from other potential diagnoses. The atypical tumor cells of cutaneous angiosarcoma display common features of endothelial cells (eg, pinocytotic vesicles, tubulated bodies).<sup>7</sup> Historically, it has been noted that the histologic findings and tumor grade provide little evidence regarding the aggressiveness of the tumor, and all cutaneous angiosarcoma diagnoses receive a poor prognosis.<sup>6,8</sup>

Classically, the histologic findings of cutaneous angiosarcoma include a highly infiltrative neoplasm forming irregular vascular channels that penetrate through the cutaneous soft tissues and frequently extend into the subcutaneous fat. The vascular spaces are lined by hyperchromatic endothelial cells with varying degrees of atypia.<sup>1,2,4,6,7,10</sup> Occasionally, prominent endothelial

From the University of South Dakota Sanford School of Medicine, Vermillion.

The authors report no conflict of interest.

Correspondence: Ashley P. Schmidt, BA, 1400 W 22nd St, Sioux Falls, SD 57105 (Ashley.P.Schmidt@coyotes.usd.edu).

cells lining a papillary structure within the lumen of the neoformed vessel may also be observed. Currently, immunohistochemical staining for MYC, Ki-67, D2-40, and various other markers complement the histologic findings to aid in the diagnosis of cutaneous angiosarcoma.<sup>11,12</sup> An additional diagnostic clue that has been described in cases of postirradiation cutaneous angiosarcoma shows free-floating or tufted pleomorphic spindle cells within the vascular lumen (Figure). This finding has been described as “fish in the creek.”<sup>11</sup> In this study, we aimed to determine the frequency and subsequent diagnostic utility of the fish-in-the-creek finding in cases of cutaneous angiosarcoma.

## Methods

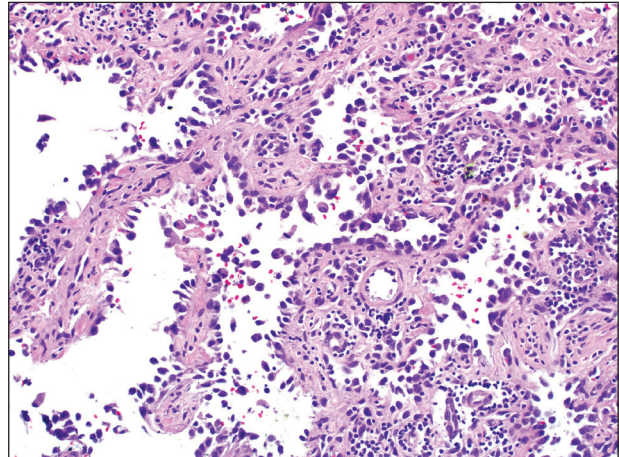
A natural language search of our institutional archives over a 20-year period (1997–2017) using the term *angiosarcoma* was performed. Fifteen cases of cutaneous angiosarcoma were identified. Fifteen additional benign and malignant vascular tumors with cutaneous angiosarcoma in the histologic differential diagnosis were selected from the archives over a similar time frame. The additional lesions included Kaposi sarcoma (n=3), atypical vascular lesion (n=6), atypical hemangioma (n=1), tufted angioma (n=1), epithelioid hemangioma (n=1), epithelioid hemangioendothelioma (n=1), sinusoidal hemangioma (n=1), and angiofibroma (n=1). The pathologists were blinded to the original diagnosis of each case and were instructed to evaluate the histology slides for the sole feature of free-floating intraluminal spindle cells or spindle cells tufting off the endothelium. Epithelial cells lining papillae found within the vessel lumen were not counted as a positive finding, as they do not fit the criteria described for the histologic pattern of fish in the creek. Following microscopic evaluation, the original diagnoses were reassigned to their respective cases to evaluate the diagnostic utility of this feature.

## Results

The histologic pattern of fish in the creek was identified in all 15 cases of cutaneous angiosarcoma and was absent in the other 15 malignancies examined in this study. This finding shows the potential for the fish-in-the-creek pattern to be used as an additional diagnostic tool for dermatopathologists.

## Comment

Cutaneous angiosarcoma is a rare but aggressive malignancy that proves difficult to diagnose both clinically and histologically as well as to treat effectively.<sup>1,5-8</sup> Our results indicate that fish in the creek may be a useful and salient histologic feature in cutaneous angiosarcoma. It is important to recognize, however, that this finding should not be the sole feature upon which a diagnosis of cutaneous angiosarcoma is made, as it requires corroboration with positivity of MYC and D2-40 as well as a high Ki-67 proliferation index (>20%).<sup>11,12</sup> Finding a fish-in-the-creek



Characteristic finding of spindled, atypical endothelial cells projecting into the vascular lumen in a cutaneous angiosarcoma, which has been likened to “fish in the creek” (H&E, original magnification  $\times 100$ ).

pattern should prompt dermatopathologists to consider a diagnosis of cutaneous angiosarcoma in the appropriate clinical and histologic settings.

The chief limitation of this study was the small sample size, with only 15 cases of cutaneous angiosarcoma available in the last 20 years at our institution. The limited sample size did not allow us to make claims on sensitivity and specificity regarding this histologic feature; however, with a larger sample size, the true diagnostic potential could be elucidated. Although the pathologists were blinded to the original diagnoses as they examined it for fish in the creek, it is possible they were able to make the correct diagnosis based on other histopathologic clues and therefore were biased.

Although the fish-in-the-creek pattern is present in cutaneous angiosarcoma, there may be other mimickers to consider. Intraluminal papillary projections lined by endothelial cells may be sectioned in a manner imitating this finding.<sup>3</sup> In such a case, these endothelial cells must be differentiated from the free-floating or tufted spindle cells in order to have a positive finding for fish in the creek. There can be confusion if the biopsy cuts through a section of spindled cells, resulting in difficulty differentiating cutaneous angiosarcoma from other spindle tumors such as spindle cell melanoma or spindle cell squamous cell carcinoma.<sup>6</sup> In such cases, immunohistochemistry may be helpful, as spindle cell melanoma would stain positive for S100 and SOX10 and spindle cell squamous cell carcinoma would stain positive for p63 and cytokeratin.

Various treatment strategies for cutaneous angiosarcoma have been employed, with the majority still resulting in poor outcomes.<sup>2,4-6</sup> The recommended treatment is radical surgical excision of the primary tumor with lymph node clearance if possible. Following excision, the patient should undergo high-dose, wide-field radiotherapy to the

region.<sup>5,8</sup> Cutaneous angiosarcomas also have the ability to spread extensively through the dermis and can result in subclinical or clinically obvious widespread disease with multifocal or satellite lesions present. Distant metastases occur most frequently in the cervical lymph nodes and lungs.<sup>7</sup> In cases where the disease is too extensive for surgery, palliative radiation monotherapy can be used.<sup>5,6</sup>

As atypical vascular lesions are considered to be a precursor to cutaneous angiosarcoma, it is important to note that the fish-in-the-creek feature was absent in all 6 of the atypical vascular lesions observed in the study. The differentiation generally is made based on MYC, which is present in cutaneous angiosarcomas and absent in atypical vascular lesions.<sup>10</sup> The feature of fish in the creek may now be an additional clue for dermatopathologists to differentiate between angiosarcomas and other similar-appearing tumors.

## Conclusion

Our study aimed to highlight an important histologic feature of cutaneous angiosarcomas that can aid in the diagnosis of this deceptive malignancy. Our findings warrant further study of the fish-in-the-creek histologic pattern in a larger sample size to determine its success as a diagnostic tool for cutaneous angiosarcomas. As noted previously, tumor grade does not impact survival outcome, but small tumor size has been one of the only features found to result in a more favorable prognosis.<sup>1,6,8</sup> Future studies to identify a correlation between the histologic finding of fish in the creek and disease outcome in cutaneous angiosarcoma may be helpful to determine if these histologic findings provide prognostic significance in cases of cutaneous angiosarcoma.

## REFERENCES

1. Aust MR, Olsen KD, Lewis JE, et al. Angiosarcomas of the head and neck: clinical and pathologic characteristics. *Ann Otol Rhinol Laryngol*. 1997;106:943-951.
2. Holden CA, Spittle MF, Jones EW. Angiosarcoma of the face and scalp, prognosis and treatment. *Cancer*. 1987;59:1046-1057.
3. Woodward AH, Ivins JC, Soule EH. Lymphangiosarcoma arising in chronic lymphedematous extremities. *Cancer*. 1972;30:562-572.
4. Calonje E, Brenn T, McKee PH, et al. *McKee's Pathology of the Skin*. 4th ed. Edinburgh, Scotland: Elsevier Saunders; 2012.
5. Morrison WH, Byers RM, Garden AS, et al. Cutaneous angiosarcoma of the head and neck. a therapeutic dilemma. *Cancer*. 1995;76:319-327.
6. Hodgkinson DJ, Soule EH, Woods JE. Cutaneous angiosarcoma of the head and neck. *Cancer*. 1979;44:1106-1113.
7. Rosai J, Sumner HW, Kostianovsky M, et al. Angiosarcoma of the skin: a clinicopathologic and fine structural study. *Hum Pathol*. 1976;7:83-109.
8. Pawlik TM, Paulino AF, McGinn CJ, et al. Cutaneous angiosarcoma of the scalp: a multidisciplinary approach. *Cancer*. 2003;98:1716-1726.
9. Hausteil UF. Angiosarcoma of the face and scalp. *Int J Dermatol*. 1991;30:851-856.
10. Elston DM, Ferringer T, Ko C, et al. *Dermatopathology*. 2nd ed. Edinburgh, Scotland: Saunders Elsevier; 2014.
11. Requena L, Kutzner H. *Cutaneous Soft Tissue Tumors*. Philadelphia, PA: Wolters Kluwer; 2015.
12. Cuda J, Mirzamani N, Kantipudi R, et al. Diagnostic utility of Fli-1 and D2-40 in distinguishing atypical fibroxanthoma from angiosarcoma. *Am J Dermatopathol*. 2013;35:316-318.