

Percutaneous Release of Trigger Digits

Noah D. Weiss, MD, and Madeline B. Richter, BS

Abstract

Stenosing flexor tenosynovitis, or trigger finger, has been treated with open, endoscopic, and percutaneous tendon sheath incisions. A comparison of techniques highlights increased cost, procedure time, and postoperative recovery associated with open surgical treatment.

We conducted a study of the efficacy of percutaneous tendon sheath incision as a treatment for trigger digit. Using percutaneous tendon sheath incisions, a single surgeon treated 596 trigger digits (429 patients) over a 10-year period. Successful release was defined as symptom relief on follow-up, or patient request for no further treatment. There were 537 successful releases (90.1%). Of the 59 failures, 17 underwent another percutaneous procedure (15 successful) and 40 underwent open surgical release (100% successful); 2 patients requested no further treatment. There were no significant differences in digit success rates and no complications. The success rate of this method was comparable to rates reported for open surgical procedures, but there were no instances of infection, chronic pain, or tendon or neurovascular damage. Percutaneous release is a safe, effective, and economical treatment option for trigger digits.

Trigger finger, or stenosing flexor tenosynovitis, is a condition characterized by clicking or locking during finger movement, sometimes resulting in the freezing of a digit in flexion or extension¹ (**Figure 1**). Tendon inflammation is thought to cause constriction of the tendon sheath and

bunching of the fibrous bundles of the first annular (A1) pulley, often creating a palpable nodule at the base of the digit.^{2,3} Many patients experience intermittent joint pain and swelling, which may progress to triggering or complete locking of the digit.¹ One of the most common conditions treated by hand surgeons, trigger finger is most often reported in the dominant hand of women in their sixth decade of life and has been associated with several conditions, including diabetes and rheumatoid arthritis.⁴⁻⁶ Other researchers have indicated the thumb and ring finger are most commonly affected, though all fingers can potentially trigger.^{7,8}

Initial treatment often involves injecting corticosteroid into the flexor tendon sheath, at or proximal to the annular pulley system, to reduce inflammation and the fibrous nodule.³ Another injection study found an initial success rate of 57% with a single injection, and 86% with a second injection, but patients were monitored for only 6 months, a period that may have been too short for symptom recurrence.⁷

On failure of steroid injections, patients typically are treated with open tendon sheath incision.⁹ This procedure, usually performed in a hospital or outpatient surgery setting, requires postoperative wound care, including dressing changes, suture removal, possible hand therapy, and follow-up physician visits. Operative treatment involves making a 1-cm to 2-cm incision, releasing the A1 pulley, and skin suturing.^{7,8,10} The most common postoperative complaint is incisional tenderness, though long-term scar pain, infection, nerve injury, and disease recurrence have been

Take-Home Points

- The author had a 90% success rate with no complications in treating almost 600 trigger digits.
- All digits can be safely treated, including multiple fingers on one hand, all in an office setting.
- Percutaneous trigger release appears to be a safe and reliable alternative to open surgery.
- Success rate, discomfort, and cost may make a percutaneous trigger release preferable to even a trial of a corticosteroid injection.
- A failed percutaneous release can be successfully treated with an open release, if needed.

Authors' Disclosure Statement: The authors report no actual or potential conflict of interest in relation to this article.

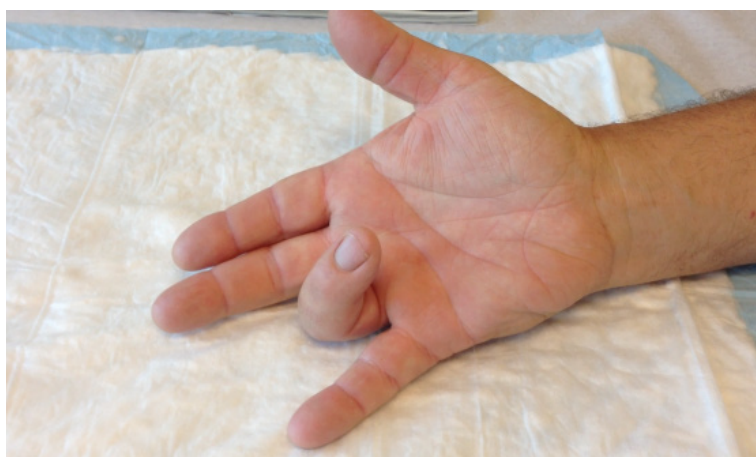

Figure 1. Trigger digit locked in flexion.

reported.⁸ Overall, the procedure is very successful, providing up to 100% symptom relief.^{7,8,10}

Endoscopic release of trigger finger has also been described as an effective operative treatment. This technique involves passing a small cannula through a palmar incision—using an endoscope and retrograde knife within this 2.7-mm tunnel.¹⁰ With this treatment, reduced visibility may increase the risk of nerve injury.¹⁰ Although generally successful, endoscopic release requires anesthesia and expensive instruments and has a significant learning curve.^{8,10}

More recently, percutaneous release of trigger finger has been described as a definitive, in-office treatment.^{5,6,11,12} Percutaneous release has the obvious advantages of no open incision, less scarring, less discomfort, and shorter recovery. Several studies have found comparable success rates for open and percutaneous procedures but consistently shorter recovery with the percutaneous technique.^{7,8,12} Given its lower recurrence rate (vs steroid injections) and shorter recovery and lower cost (vs a surgical procedure), percutaneous treatment of stenosing tenosynovitis appears to be a safe, highly successful, and minimally invasive treatment method.⁸ This study represents a single surgeon's experience with percutaneous tendon sheath incision over a 10-year period.

Methods

Patients presented with symptoms of stenosing flexor tenosynovitis with severity ranging from intermittent triggering to frank locking of the digit. Most patients underwent prior conservative treatment, including corticosteroid injections and hand therapy. With each patient, the senior author discussed the pathophysiology of trigger digit; treatment options, including observation, hand therapy, corticosteroid injection, percutaneous release, and open release; and potential risks and complications. The treatment path—initial corticosteroid injection, percutaneous release, or open release—was left up to the patient. The only exclusion criterion was prior surgery to the involved digit, and there was no discrimination by finger, symptomatic period, or severity. Each released digit was recorded independently. In no case was anticoagulant therapy discontinued. A complete medical history was obtained for each patient.

Over a 10-year period (March 2003-December 2013), percutaneous release was performed on 596 trigger fingers in 429 patients, 18 years old or older. Of these patients, 279 were female. Mean age was 62 years (range, 26-97 years). Of the 531 releases with handedness recorded, 56.3% were performed on trigger digits on dominant hands (**Table 1**). Mean duration of symptoms before percutaneous release was 9.7 months (range, 0.5-132 months). Of the 596 digits, 69 were reported to have previously sustained trauma, and 161 had been unsuccessfully treated with one or more cortisone injections before undergoing release. Of the suspected comorbidities examined, carpal tunnel syndrome was previously diagnosed in 79 patients and diabetes in 56 patients.¹

Of the 429 patients, 313 had a single digit released and 116 had multiple digits released. Of the 116 patients in the multiple-release group, 80 had 2 fingers released, 24 had 3 released, 7 had 4 released, and 5 had 5 released. The 596 released trigger fingers consisted of 188 thumbs, 41 index fingers, 185 middle fingers, 140 ring fingers, and 42 small fingers.

Table 1. Relationship Between Hand Dominance and Likelihood of Trigger Digit

Right-Hand Dominant: 504		Left-Hand Dominant: 27	
Right-hand digit	Left-hand digit	Right-hand digit	Left-hand digit
286	218	14	13

Surgical Technique

In-office percutaneous trigger finger releases were performed with a local anesthetic. One milliliter of lidocaine 1% injection was used to anesthetize the skin, the subcutaneous tissues, and the flexor tendon sheath at the level of the A1 pulley. As described by Pandey and colleagues,⁶ the proper location of the pulley was confirmed using specific surface landmarks on each digit. After waiting several minutes to allow the anesthetic to take effect, the surgeon inserted an 18-gauge needle into the center of the pulley with the digit held in extension (**Figure 2**). The needle was carefully moved longitudinally along the length of the pulley with the bevel of the needle parallel to the tendon. A grating sensation was felt as the fibers of the pulley were cut. Several needle passes were made until the pulley was felt to have been released. Complete release was determined by loss of the grating sensation, along with complete relief of any further symptoms of triggering. The puncture site was cleaned and covered with a light sterile dressing (watch the **Video** online at www.amjorthopedics.com). There was no postoperative immobilization, and patients were encouraged to immediately return to normal use of the digit. Hand therapy was not prescribed, and pain medications were not dispensed. A 1-week follow-up appointment was scheduled, and patients were advised to return for evaluation in the event of any recurring symptoms (eg, triggering, swelling, stiffness, pain).

Results

Ninety percent (537/596) of the trigger digits were successfully released with 1 percutaneous procedure (recurrence or failure rate, 9.9%). The thumb was the digit most reliably released (success rate, 94.7%) (**Table 2**). Patients with recurrent or unresolved symptoms were given the options of a second percutaneous release or an open surgical procedure. Of the 59 digits unsuccessfully released, as identified by persistent triggering or locking of the digit, 17 were treated with a second percutaneous release (15 were successful), and 40 underwent open tendon sheath incision as a second procedure (success rate, 100%); triggering persisted in the remaining 2 digits, and these were considered failures (the 2 patients did not pursue further treatment).

There were no complications: infection; nerve, artery, or tendon injury; or chronic pain. Some patients had mild stiffness, swelling, or pain for a few days after the procedure, and these effects

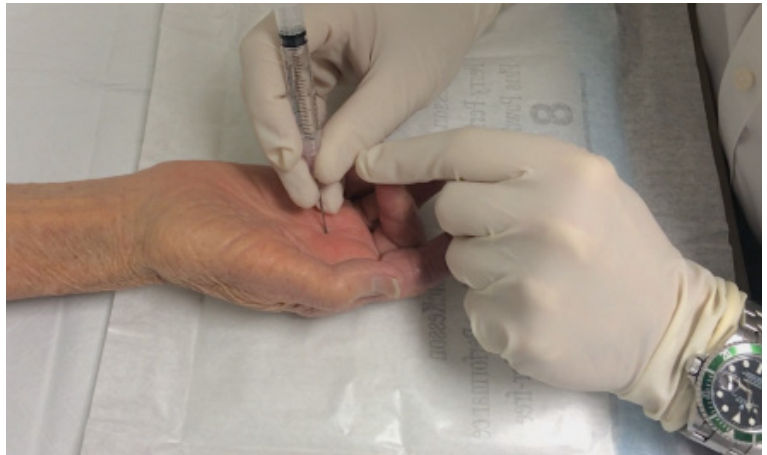

Figure 2. Percutaneous release of trigger digit with an 18-gauge needle.

Table 2. Success Rate of Percutaneous Release by Individual Digit

Digit	Releases, n	Failed Releases, n	Success Rate, %
Thumb	188	10	94.7
Index	41	4	90.2
Middle	185	24	87.0
Ring	140	15	89.3
Little	42	6	85.7

typically resolved without treatment. In 29 digits, persistent pain or swelling without triggering was successfully treated with a corticosteroid injection.

Discussion

Over a 10-year period, 596 percutaneous trigger finger releases were sequentially performed by a single surgeon. The 90% success rate compares favorably with rates found in other studies (**Table 3**).^{5-9,12-14} The surgeon's success rates for individual years vary and demonstrate no clear trend or learning curve with the procedure (**Figure 3**). There were no significant complications. Patient satisfaction with the procedure was high.

There were no injuries to digital nerves, arteries, or flexor tendons, either early or late, and no reports of infections or long-term pain or loss of motion. Although it is quite probable that in some procedures the longitudinal passes of the 18-gauge needle may have also slightly cut into the flexor tendon after passing through the A1 pulley, the direction of the needle passes was in line with the direction of the collagen fibers of the tendon, and thus any inadvertent superficial abrasion would not

Table 3. Comparison of Studies That Used Percutaneous Release Methods

Study	Year	Fingers, n	Mean Age, y	Excluding Factors	Instrument Used	Complete Release, %
Schramm et al ^{12,a}	2008	30	N/A	None	18-gauge needle	93
Paulius & Maguina ^{13,a}	2009	18	N/A	None	18-gauge needle	17
Habbu et al ^{5,a}	2012	54	N/A	Thumb	No. 15 blade	72
Cihantimur et al ¹⁴	1998	34	58	Symptoms originating <4 months prior, no palpable nodule in palm	21-gauge needle	100
Tanaka ⁹	1999	95	49.6	None	Small scalpel	93.7
Dierks et al ⁸	2008	16	62	Thumb, multiple trigger fingers, previous upper extremity operation, diabetes, rheumatoid arthritis, joint extension lag, age <18 years or >80 years	No. 15 blade	100
Pandey et al ⁶	2010	58	52	No active triggering or locking	18-gauge needle	97
Sato et al ⁷	2012	50	No data	Previous treatment, age <15 years	40 × 12 needle	100
Present study	2013	596	62	Prior surgery on digit	18-gauge needle	90.1

^aCadaver study.
Abbreviation: N/A, not available.

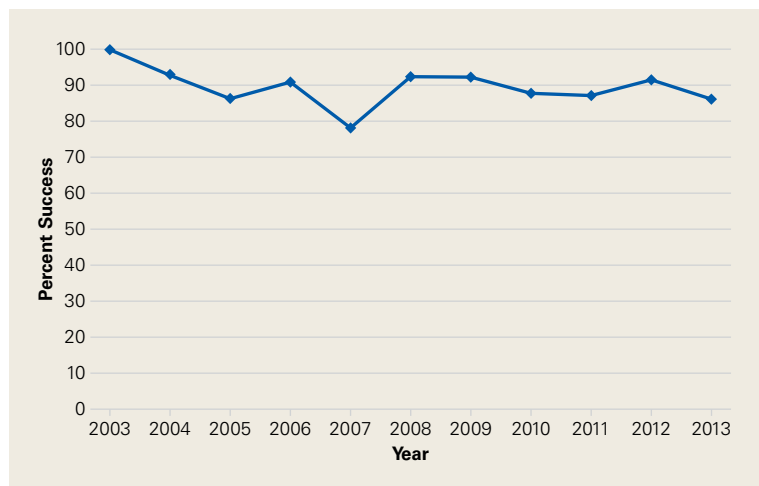


Figure 3. Percutaneous trigger-finger release success rate over 10 years.

have structurally weakened the tendon. Of the 40 digits that underwent open release after incomplete or failed percutaneous release, none showed significant longitudinal lacerations of the superficialis tendon. During these revision surgeries, the typical intraoperative finding was incomplete release of the A1 pulley, usually at the distal end. Although loss of the grating sensation or relief of further triggering symptoms was considered adequate evidence of a successful release in this study, small tendon attachments could remain and potentially could lead to recurrent triggering. Given

the high success rate achieved with the large sample, however, these 2 factors are considered appropriate indicators of successful release.

It is unclear why there was a relatively consistent 10% failure rate and why it did not decrease over the 10-year study period. Although the technique used does not have a significant learning curve, it appears that digits are not actively triggering at time of procedure have a higher failure rate. When a patient's digit is actively triggering, assessment of the success of the procedure is relatively straightforward, whereas when a digit intermittently triggers and locks and is not symptomatic in the office, success cannot be immediately determined.

No specific digit was significantly more prone to failed releases, though the small finger had the lowest success rate (85.7%). Given that only 56.4% of patients experienced triggering on the dominant hand, there is not enough evidence to suggest a significant relationship between likelihood of a trigger digit and a patient's hand dominance. Similarly, there was no correlation between the duration of symptoms and the success of the percutaneous procedure.

Investigation of the relationship between the previously suggested comorbidities of carpal tunnel syndrome and diabetes was also inconclusive. Only 79 (18%) of 429 patients reported having carpal tunnel syndrome, and even fewer, 56 (13.0%), reported having diabetes. Only 69 of the 596 treat-



ed digits reportedly had sustained trauma before developing triggering symptoms, and only 12 of the 69 were unsuccessfully released. In addition, of the 161 digits in which one or more steroid injections failed to resolve triggering symptoms, 158 (87.3%) were successfully released with 1 percutaneous procedure. Collectively, these data show percutaneous release can effectively eliminate triggering symptoms in a digit that has sustained injury or that has been unsuccessfully treated with nonoperative methods. Failed percutaneous release subsequently can be reliably treated with an open procedure, and results are excellent.

This study had several limitations. It was retrospective, nonblinded, and did not compare outcomes of percutaneous release with those of an open procedure. Data are presented to support the efficacy and safety of percutaneous release as a treatment option. Another limitation is that pre-release treatment was not controlled. Patients had been treated with a variety of nonoperative methods, including use of anti-inflammatory medication, hand therapy, splinting, and one or more corticosteroid injections, both at our office and elsewhere.

Percutaneous release appears to have an advantage in terms of pain relief, but the study did not evaluate or control for procedure discomfort. However, patients who had been treated with a corticosteroid injection before percutaneous release consistently refused corticosteroid injections for subsequent trigger digits, citing the dramatic pain reduction achieved with release relative to injection. Similarly, all patients who had a trigger digit treated with open tendon sheath incision in the past indicated a strong preference for the percutaneous release.

Follow-up on this patient population was inconsistent and incomplete. Many patients did not return, presumably because they considered the procedure a success and thought follow-up was unnecessary. However, some patients may have had a recurrence or an incomplete release and gone elsewhere for treatment.

The results of this study, to date the largest study on percutaneous release of trigger finger, provide more evidence of the safety and efficacy of this procedure as a treatment option. The success rate of percutaneous release is high, surpasses that of nonoperative treatments such as steroid injections, and approaches that of open and endoscopic surgical alternatives. Some of the obvious advantages of percutaneous release are less visible scarring, fewer incision-related com-

plications, and shorter rehabilitation.¹⁰ In addition, post-procedure pain is possibly reduced, symptom relief is comparable, operative time is significantly shorter,⁹ and percutaneous release is easily performed in the office setting.

Percutaneous release is a viable treatment option for stenosing flexor tenosynovitis, regardless of previously used nonoperative treatment methods, duration or severity of symptoms, or trigger digit treated.

Dr. Weiss is an Orthopedic Surgeon practicing in Sonoma and Marin, California. Ms. Richter is a Medical Student, Arizona College of Medicine, Phoenix, Arizona.

Address correspondence to: Noah D. Weiss, MD, Weiss Orthopaedics, 462 W. Napa St., Sonoma, CA 95476 (tel, 707-935-5603; fax, 707-935-5606; email, nweiss@weissortho.com).

Am J Orthop. 2017;46(4):E263-E267. Copyright Frontline Medical Communications Inc. 2017. All rights reserved.

References

1. Makkouk AH, Oetgen ME, Swigart CR, Dodds SD. Trigger finger: etiology, evaluation, and treatment. *Curr Rev Musculoskelet Med.* 2008;1(2):92-96.
2. Fahey JJ, Bollinger JA. Trigger-finger in adults and children. *J Bone Joint Surg Am.* 1954;36(6):1200-1218.
3. Marks MR, Gunther SF. Efficacy of cortisone injection in treatment of trigger fingers and thumbs. *J Hand Surg Am.* 1989;14(4):722-727.
4. Chammas M, Bousquet P, Renard E, Poirier JL, Jaffiol C, Allieu Y. Dupuytren's disease, carpal tunnel syndrome, trigger finger, and diabetes mellitus. *J Hand Surg Am.* 1995;20(1):109-114.
5. Habbu R, Putman MD, Adams JE. Percutaneous release of the A1 pulley: a cadaver study. *J Hand Surg Am.* 2012;37(11):2273-2277.
6. Pandey BK, Sharma S, Manandhar RR, Pradhan RL, Lakhey S, Rijal KP. Percutaneous trigger finger release. *Nepal Orthop Assoc J.* 2010;1(1):1-5.
7. Sato ES, Gomes dos Santos JB, Belloti JC, Albertoni WM, Faloppa F. Treatment of trigger finger: randomized clinical trial comparing the methods of corticosteroid injection, percutaneous release and open surgery. *Rheumatology.* 2012;51(1):93-99.
8. Dierks U, Hoffmann R, Meek MF. Open versus percutaneous release of the A1-pulley for stenosing tendovaginitis: a prospective randomized trial. *Tech Hand Up Extrem Surg.* 2008;12(3):183-187.
9. Tanaka J. Percutaneous trigger finger release. *Tech Hand Up Extrem Surg.* 1999;3(1):52-57.
10. Pegoli L, Cavalli E, Cortese P, Parolo C, Pajardi G. A comparison of endoscopic and open trigger finger release. *Hand Surg.* 2008;13(3):147-151.
11. Ryzewicz M, Wolf JM. Trigger digits: principles, management, and complications. *J Hand Surg Am.* 2006;31(1):135-146.
12. Schramm JM, Nguyen M, Wongworawat MD. The safety of percutaneous trigger finger release. *Hand.* 2008;3(1):44-46.
13. Paulius KL, Maguina P. Ultrasound-assisted percutaneous trigger finger release: is it safe? *Hand.* 2009;4(1):35-37.
14. Cihantimur B, Akin S, Ozcan M. Percutaneous treatment of trigger finger. 34 fingers followed 0.5-2 years. *Acta Orthop Scand.* 1998;69(2):167-168.