



LEARNING OBJECTIVE: Readers will recognize and manage malpositioning of cardiac implantable electronic device leads

RICHARD G. TROHMAN, MD, MBA
Electrophysiology, Arrhythmia, and Pacemaker
Section, Division of Cardiology, Department of
Internal Medicine, Rush University Medical Center,
Chicago, IL

PARIKSHIT S. SHARMA, MD, MPH
Electrophysiology, Arrhythmia, and Pacemaker
Section, Division of Cardiology, Department of
Internal Medicine, Rush University Medical Center,
Chicago, IL

Detecting and managing device leads inadvertently placed in the left ventricle

ABSTRACT

Inadvertent malpositioning of a cardiac implantable electronic device lead into the left ventricle is a rare complication of transvenous pacing and defibrillation. Rapid identification of lead position is critical during implantation and just after the procedure, with immediate correction required if malpositioning is detected. If lead misplacement is discovered late after implantation, the lead should be surgically removed or chronic anticoagulation with warfarin should be instituted.

KEY POINTS

During device implantation, fluoroscopy in progressively lateral left anterior oblique views should be used to ensure correct lead position.

After implantation, malposition can almost always be detected promptly by examining a 12-lead electrocardiogram for the paced QRS morphology and by lateral chest radiography.

Echocardiography and computed tomography may enhance diagnostic accuracy and clarify equivocal findings.

Late surgical correction of a malpositioned lead is best done when a patient is undergoing cardiac surgery for other reasons.

Long-term warfarin therapy is recommended to prevent thromboembolism if malpositioning cannot be corrected.

Dr. Trohman has disclosed commercial relationships (consulting, salary support, teaching and speaking, or research funding) with Biosense Webster, Boston Scientific, Daiichi Sankyo, Medtronic/Vitatron, St. Jude Medical, and Wyeth Ayerst Laboratories.

Dr. Sharma has disclosed a commercial relationship (teaching and speaking) with Medtronic.

doi:10.3949/ccjm.85a.17012

ALTHOUGH RARE, inadvertent placement of a pacemaker or defibrillator lead in the left ventricle can have serious consequences, including arterial thromboembolism and aortic or mitral valve damage or infection.¹⁻⁴

This article discusses situations in which lead malpositioning is likely to occur, how to prevent it, how to detect and correct it immediately, and how to manage cases discovered long after implantation.

■ RARE, BUT LIKELY UNDERREPORTED

In 2011, Rodriguez et al¹ reviewed 56 reported cases in which an endocardial lead had been mistakenly placed in the left ventricle. A few more cases have been reported since then, but some cases are not reported, so how often this occurs is unknown.

A large single-center retrospective study² reported a 3.4% incidence of inadvertent lead placement in the left side of the heart, including the cardiac veins.

■ HOW LEADS CAN END UP IN THE WRONG PLACE

Risk factors for lead malpositioning include abnormal thoracic anatomy, underlying congenital heart disease, and operator inexperience.²

Normally, in single- and double-lead systems, leads are inserted into a cephalic, subclavian, or axillary vein and advanced into the right atrium, right ventricle, or both. However, pacing, sensing, and defibrillation leads have inadvertently been placed in the left ventricular endocardium and even on the epicardial surface.

Leads can end up inside the left ventricle by passing through an unrecognized atrial septal defect, patent foramen ovale, or ventricular

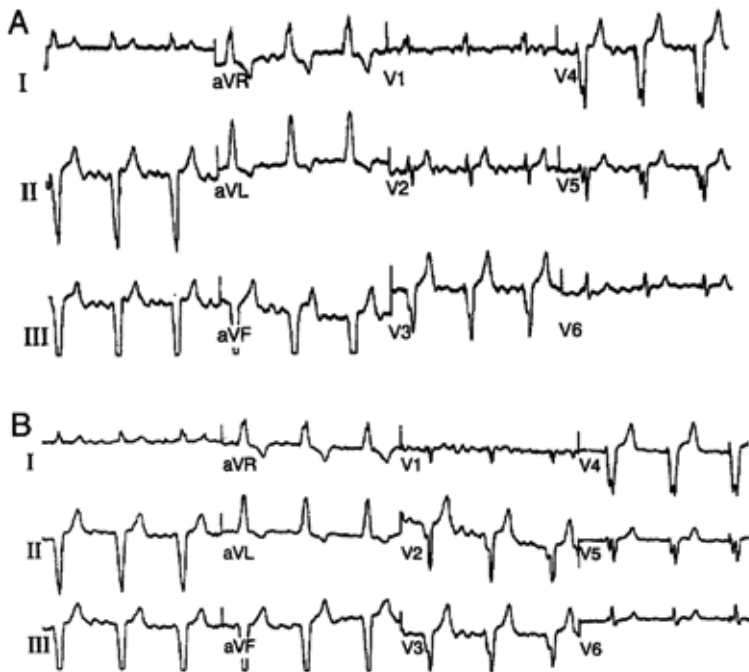

Figure 1. Typical 12-lead electrocardiogram showing right bundle branch block morphology from the right ventricular apex with (A) standard V_1 and V_2 lead positions and (B) return to left bundle branch block morphology after V_1 and V_2 are moved 1 interspace lower than standard.

Reprinted from reference 6 with permission.

septal defect, or by perforating the interventricular septum. Another route into the left ventricle is by gaining vascular access through the axillary or subclavian artery and advancing the lead retrograde across the aortic valve.

Epicardial lead placement may result from perforating the right ventricle⁵ or inadvertent positioning within the main coronary sinus or in a cardiac vein.

■ PREVENTION IS THE BEST MANAGEMENT

The best way to manage lead malpositioning is to prevent it in the first place.

Make sure you are in a vein, not an artery! If you are working from the patient's left side, you should see the guidewire cross the midline on fluoroscopy. Working from either the left or the right side, you can ensure that the guidewire is in the venous system by advancing it into the inferior vena cava and then all the way below the diaphragm (best seen on anteroposterior views). These observations help avoid lead placement in the left

ventricle by an inadvertent retrograde aortic approach.

Suspect that you are taking the wrong route to the heart (ie, through the arterial system) if, in the anteroposterior view, the guidewire bends as it approaches the left spinal border. This sign suggests that you are going backwards through the ascending aorta and bumping up against the aortic cusps. Occasionally, the wire may pass through the aortic valve without resistance and bending. Additional advancement toward the left chest wall will make contact with the left ventricular endocardium and may result in ventricular ectopy. Placement in the left ventricle is best seen in the left anterior oblique projection; the lead will cross the spine or its distal end will point toward the spine in progressive projections from farther to the left.

Make sure you are in the right ventricle. Even if you have gone through the venous system, you are not home free. Advancing the lead into the right ventricular outflow tract (best seen in the right anterior oblique projection) is a key step in avoiding lead misplacement. In the right ventricular outflow tract, the lead tip should move freely; if it does not, it may be in the coronary sinus or middle cardiac vein.

If a lead passes through a patent foramen ovale or septal defect to the left atrium, a left anterior oblique view should also demonstrate movement toward or beyond the spine. If the lead passes beyond the left heart border, a position in a pulmonary vein is possible. This is often associated with loss of a recordable intracardiac electrogram. A position in a right pulmonary vein is possible but very, very unlikely. If a lead passes through a patent foramen ovale or septal defect to the left ventricle, it will point toward the spine in left anterior oblique projections. (See "Postoperative detection by chest radiography.")

Ventricular paced QRS complexes should show a left bundle branch pattern on electrocardiography (ECG), not a right bundle branch pattern (more about this below). However, when inserting a pacemaker, the sterile field includes the front of the chest and therefore lead V_1 is usually omitted, depriving the operator of valuable information.

Fortunately, operators may fluoroscopically

TABLE 1

Electrocardiographic localization of leads that exhibit right bundle branch block morphologies during pacing

Frontal axis	Precordial transition	Location	Sensitivity (%)	Specificity (%)	Positive predictive value (%)
0° to -90°	By V ₃	RV septum or apex	86	99	95
	By V ₄	RV septum or apex	100	92	64
	By V ₄	Posterior LV or coronary vein	26	83	36
	After V ₄	Posterior LV or coronary vein	72	100	100
-90° to -180°	By V ₃	LV apex and distal anterior LV	85	100	100
90° to 180°		Proximal anterior and anterolateral LV	100	97	90

LV = left ventricular; RV = right ventricular

Reprinted from reference 6 with permission.

view leads intended for the right ventricle in left anterior oblique projections. We recommend beginning at 40° left anterior oblique. In this view, septally positioned right ventricular leads may appear to abut the spine. A right ventricular position is confirmed in a steeper left anterior oblique projection, where the lead should be seen to be away from the spine.⁴

■ POSTOPERATIVE DETECTION BY ECG

Careful evaluation of the 12-lead electrocardiogram during ventricular pacing is important for confirming correct lead placement. If ventricular pacing is absent, eg, if the device fires only if the natural heart rate drops below a set number and the heart happens to be firing on its own when you happen to be looking at it, programming the device to pace the right ventricle 10 beats per minute faster than the intrinsic heart rate usually suffices. Temporarily disabling atrial pacing and cardiac venous pacing in biventricular devices facilitates interpretation of the paced QRS complex.

Bundle branch block patterns

The typical morphology for paced events originating from the right ventricle has a left bundle branch block pattern, ie, a dominant S wave in leads V₁ and V₂. Nevertheless, many

patients with a safely placed lead in the right ventricle can also demonstrate right bundle branch morphology during pacing,⁶ ie, a dominant R wave in leads V₁ and V₂.

Klein et al⁷ reported on 8 patients who had features of right bundle branch block in leads V₁ and V₂ and noted that placing these leads 1 interspace lower eliminated the right bundle branch block appearance. The utility of this maneuver is demonstrated in **Figure 1**.

Almehairi et al⁸ demonstrated transition to a left bundle branch block-like pattern in V₁ in 14 of 26 patients after leads V₁ and V₂ were moved to the fifth intercostal space. Moving these leads to the sixth intercostal space produced a left bundle branch block-like pattern in all the remaining patients. Additional study is needed to validate this precordial mapping technique.⁹

Coman and Trohman⁶ developed an algorithm using Klein's technique and simple biaxial data (**Table 1**). They excluded left ventricular pacing from the proximal and mid-septum. The 2 criteria of a frontal axis of 0° to -90° and precordial transition from a predominantly positive to a predominantly negative paced QRS complex by V₃ separated right ventricular septal pacing from all other forms of left ventricular pacing, including from the cardiac veins (sensitivity 86%, specificity 99%

A malpositioned lead can cause arterial thromboemboli, and aortic or mitral valve damage or infection

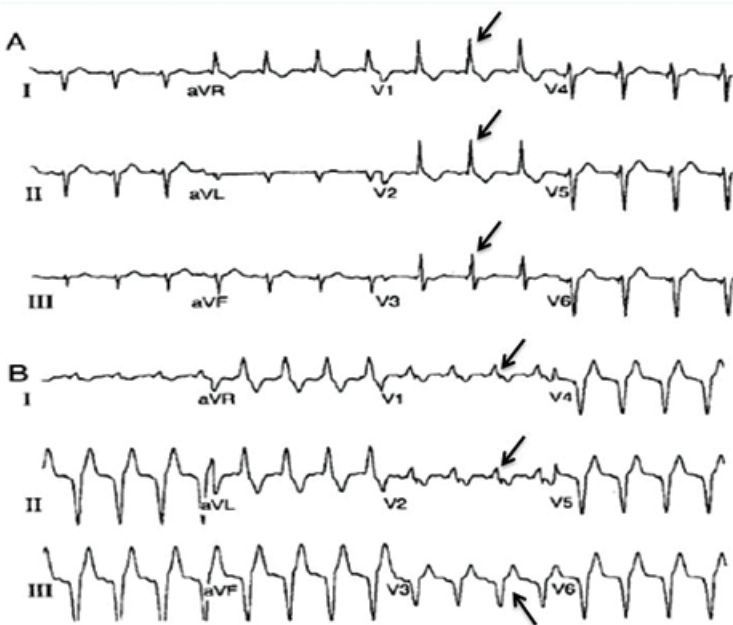


Figure 2. (A) Electrocardiogram from a patient with known left ventricular lead position through a patent foramen ovale. Arrows point to dominant R waves in leads V_1 , V_2 , and V_3 , compatible with left ventricular pacing. (B) The same patient after revision and placement in the right ventricle. Arrows point to dominant R waves in leads V_1 and V_2 , with a precordial transition to a dominant S wave occurring at lead V_3 .

Reprinted from reference 6 and reference 14 with permission.

specificity, and positive predictive value 95%). A precordial transition at or before lead V_3 essentially ruled out inadvertent left ventricular pacing (Figure 2).⁹ In addition, criteria were established to distinguish 4 major areas of left ventricular endocardial pacing.⁶

Although the Coman and Trohman algorithm suggests that a frontal plane axis of -90° to -180° is specific for left ventricular pacing,⁶ other reports have identified this axis in the presence of true right ventricular pacing.^{6,9-12} Therefore, Barold and Giudici⁹ argue that a frontal plane axis in the right superior quadrant has limited diagnostic value.

POSTOPERATIVE DETECTION BY CHEST RADIOGRAPHY

The postoperative chest radiograph is important for identifying complications such as pneumothorax and hemothorax. It is also extremely valuable for identifying lead dislodgment or malposition.

A lead in the left ventricle may be a subtle

finding on an anteroposterior or posteroanterior chest radiograph. The definitive view is the lateral projection, which is also true during intraoperative fluoroscopy.¹³⁻¹⁵ The tip of a malpositioned left-ventricular lead is characteristically seen farther posterior (toward the spine) in the cardiac silhouette on the lateral view (Figure 3).² If the lead is properly positioned, the general direction of the middle to distal portion should be away from the spine.

ECHOCARDIOGRAPHY TO CONFIRM

Although an electrocardiogram and a lateral chest radiograph should suffice to detect inadvertent left ventricular lead placement, it is common to confirm the diagnosis with a 2-dimensional transthoracic or transesophageal echocardiogram (Figure 4).¹⁶

Two-dimensional echocardiography can help to confirm left ventricular placement via an atrial septal defect, patent foramen ovale, or perforation of the interventricular septum.^{16,17}

Three-dimensional echocardiography can facilitate cardiac venous lead placement and assess the impact of right ventricular lead placement on tricuspid valve function.^{18,19} In one case report, 3-dimensional echocardiography provided a definitive diagnosis of interventricular septal perforation when findings on computed tomography (CT) were indeterminate.²⁰

CT AND MRI: LIMITED ROLES

When echocardiographic findings are equivocal, CT can help diagnose lead perforation. Electrocardiogram-triggered cardiac CT can help visualize lead positions and potential lead perforation. Unfortunately, the precise location of the lead tip (and the diagnosis) can be missed due to streaking (“star”) artifacts and acoustic shadowing from the metallic lead.²¹⁻²⁶ Because of these limitations, as well as radiation exposure and high costs, CT should be used sparingly, if at all, for diagnosing lead malposition.

Technological advances and the increasing use of magnetic resonance imaging (MRI) in clinical practice have led to the development of “MRI-conditional” cardiac implantable elec-

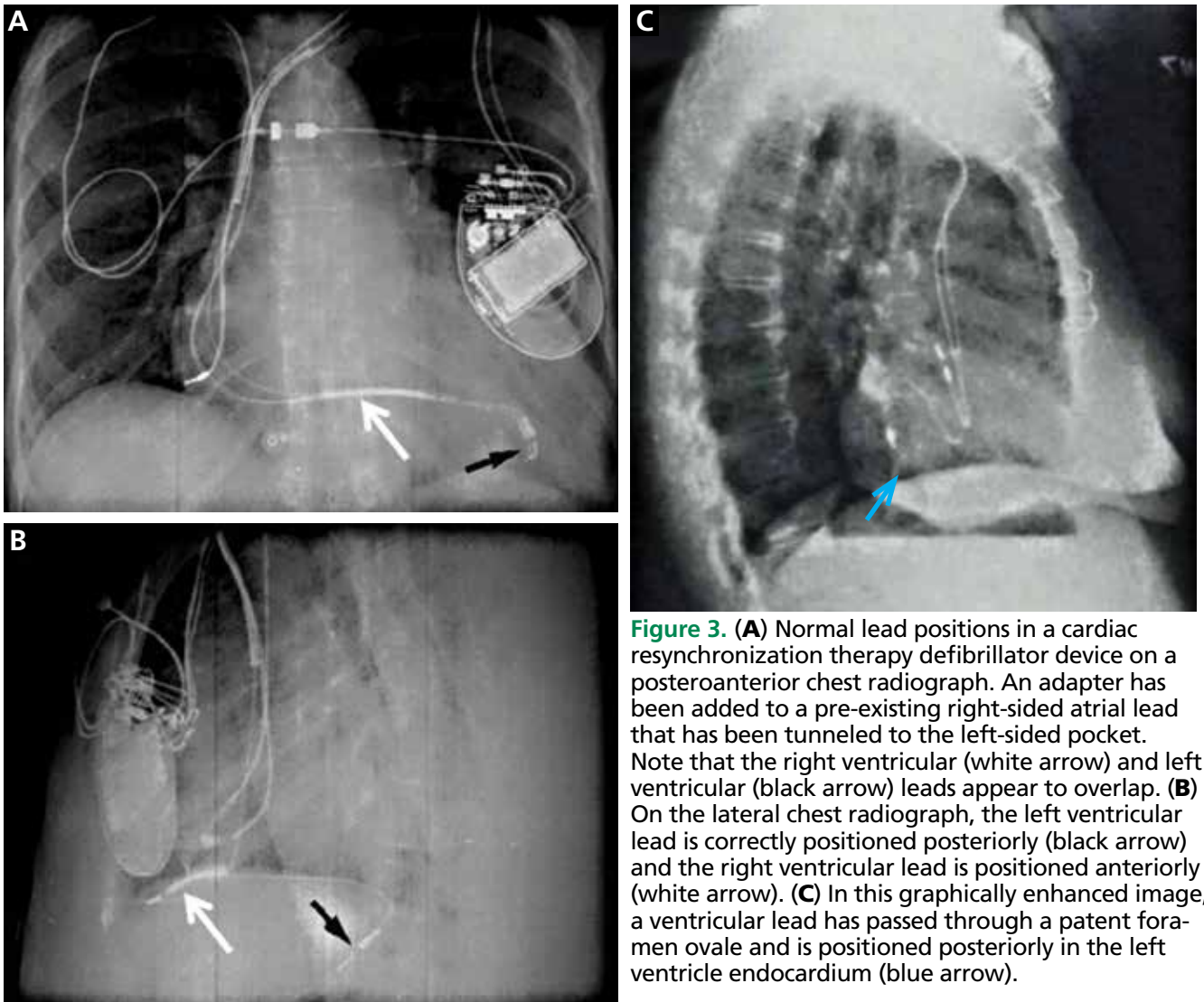


Figure 3. (A) Normal lead positions in a cardiac resynchronization therapy defibrillator device on a posteroanterior chest radiograph. An adapter has been added to a pre-existing right-sided atrial lead that has been tunneled to the left-sided pocket. Note that the right ventricular (white arrow) and left ventricular (black arrow) leads appear to overlap. (B) On the lateral chest radiograph, the left ventricular lead is correctly positioned posteriorly (black arrow) and the right ventricular lead is positioned anteriorly (white arrow). (C) In this graphically enhanced image, a ventricular lead has passed through a patent foramen ovale and is positioned posteriorly in the left ventricle endocardium (blue arrow).

Adapted with permission from references 14 and 15.

tronic devices (ie, safe for undergoing MRI), as well as more lenient regulation of MRI in patients with nonconditional devices.^{27,28} Although the widely held opinion that patients with a pacemaker or implantable cardioverter defibrillator are not eligible to undergo MRI has largely been abandoned, it seems unlikely that cardiac MRI will become a pivotal tool in assessing lead malposition.

MANAGING MALPOSITIONED LEADS

Inadvertent left ventricular lead placement provides a nidus for thrombus formation. When inadvertent left ventricular lead mal-

position is identified acutely, correction of the lead position should be performed immediately by an experienced electrophysiologist.

Treatment of left ventricular lead misplacement discovered late after implantation includes lead removal or chronic anticoagulation with warfarin to prevent thromboemboli.

Long-term anticoagulation

No thromboembolic events have been reported² in patients with lead malposition who take warfarin and maintain an international normalized ratio of 2.5 to 3.5.

Antiplatelet agents are not enough by themselves.¹⁶

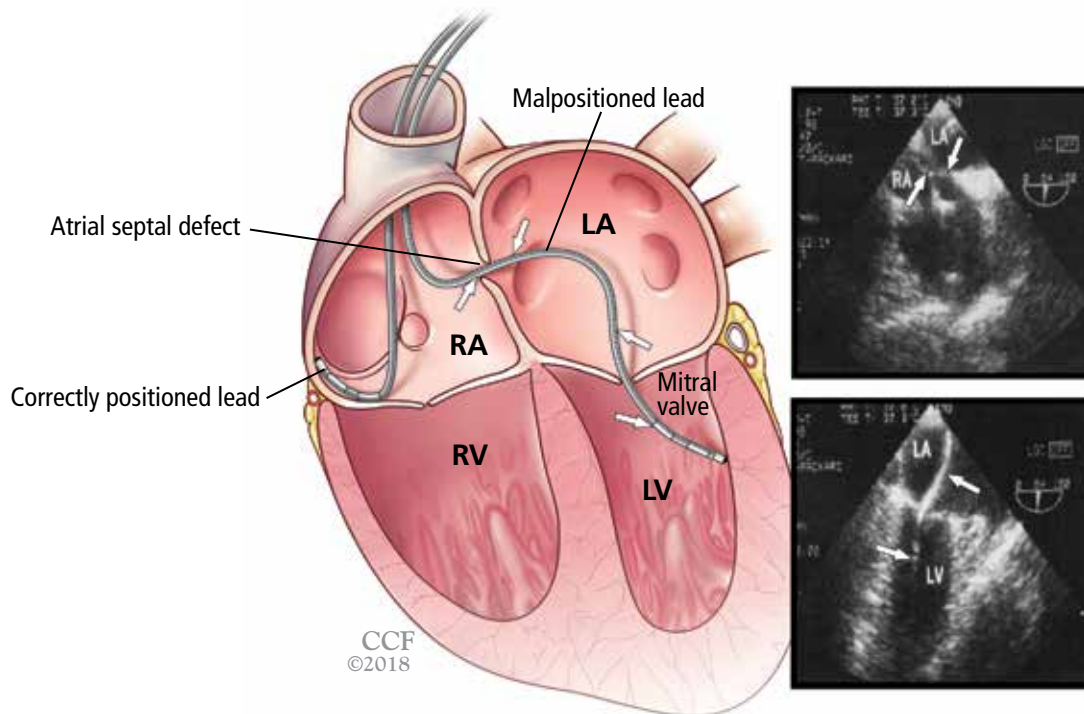


Figure 4. Left, correctly positioned and malpositioned leads. As shown in the transesophageal echocardiogram (right), the malpositioned lead passed through an atrial septal defect (top) through the mitral valve into the left ventricle (bottom).

Echocardiograms adapted with permission from reference 16; medical illustration by Joseph Pangrace.

Long-term warfarin is recommended if malpositioning cannot be corrected

The use of direct oral anticoagulants has not been explored in this setting. Use of dabigatran in patients with mechanical heart valves was associated with increased rates of thromboembolic and bleeding complications compared with warfarin.²⁹ Based on these results and an overall lack of evidence, we do not recommend substituting a direct oral anticoagulant for warfarin in the setting of malpositioned left ventricular leads.

Late percutaneous removal

Late lead removal is most appropriate if cardiac surgery is planned for other reasons. Although percutaneous extraction of a malpositioned left ventricular lead was first described over 25 years ago,¹³ the safety of this procedure remains uncertain.

Kosmidou et al¹⁷ reported two cases of percutaneous removal of inadvertent transarterial leads employing standard interventional cardiology methods for cerebral embolic protection. Distal embolic filter wires were deployed in the left and right internal carotid arteries. A covered stent was deployed at the arterial entry site simultaneously with lead removal, providing immediate and effective hemostasis. Similar protection should be considered during transvenous access and extraction via an atrial septal or patent foramen ovale.

Nevertheless, not even transesophageal echocardiography can reliably exclude adhered thrombi, and the risk of embolization of fibrous adhesions or thrombi has been cited as a pivotal contraindication to percutaneous lead extraction regardless of modality.¹⁶ ■

REFERENCES

- Rodriguez Y, Baltodano P, Tower A, Martinez C, Carrillo R. Management of symptomatic inadvertently placed endocardial leads in the left ventricle. *Pacing Clin Electrophysiol* 2011; 34:1192–1200.
- Ohlow MA, Roos M, Lauer B, Von Korn H, Geller JC. Incidence, predictors, and outcome of inadvertent malposition of transvenous pacing or defibrillation lead in the left heart. *Europace* 2016; 18:1049–1054.
- Madias C, Trohman RG. Cardiac resynchronization therapy: the state of the art. *Expert Rev Cardiovasc Ther* 2014; 12:573–587.
- Trohman RG. To the editor—comment on six uneventful years with a pacing lead in the left ventricle. *Heart Rhythm* 2013; 10:e81.
- Cossú SF. Unusual placement of a coronary sinus lead for resynchronization therapy resulting in late lead fracture. *J Innovations Cardiac Rhythm Manage* 2013; 4:1148–1153.
- Coman JA, Trohman RG. Incidence and electrocardiographic localization of safe right bundle branch block configurations during permanent ventricular pacing. *Am J Cardiol* 1995; 76:781–784.
- Klein HO, Beker B, Sareli P, DiSegni E, Dean H, Kaplinsky E. Unusual QRS morphology associated with transvenous pacemakers. The pseudo RBBB pattern. *Chest* 1985; 87:517–521.
- Almehairi M, Enriquez A, Redfearn D, et al. Right bundle branch block-like pattern during ventricular pacing: a surface electrocardiographic mapping technique to locate the ventricular lead. *Can J Cardiol* 2015; 31:1019–1024.
- Barold SS, Giudici MC. Renewed interest in the significance of the tall R wave in ECG lead V1 during right ventricular pacing. *Expert Rev Med Devices* 2016; 13:611–613.
- Almehairi M, Ali FS, Enriquez A, et al. Electrocardiographic algorithms to predict true right ventricular pacing in the presence of right bundle branch block-like pattern. *Int J Cardiol* 2014; 172:e403–e405.
- Tzeis S, Andrikopoulos G, Weigand S, et al. Right bundle branch block-like pattern during uncomplicated right ventricular pacing and the effect of pacing site. *Am J Cardiol* 2016; 117:935–939.
- Hemminger EJ, Criley JM. Right ventricular enlargement mimicking electrocardiographic left ventricular pacing. *J Electrocardiol* 2006; 39:180–182.
- Furman S. Chest PA and lateral. *Pacing Clin Electrophysiol* 1993; 16:953.
- Trohman RG, Wilkoff BL, Byrne T, Cook S. Successful percutaneous extraction of a chronic left ventricular pacing lead. *Pacing Clin Electrophysiol* 1991; 14:1448–1451.
- Trohman RG, Kim MH, Pinski SL. Cardiac pacing: the state of the art. *Lancet* 2004; 364:1701–1719.
- Van Gelder BM, Bracke FA, Oto A, et al. Diagnosis and management of inadvertently placed pacing and ICD leads in the left ventricle: a multicenter experience and review of the literature. *Pacing Clin Electrophysiol* 2000; 23:877–883.
- Kosmidou I, Karpaliotis D, Kandzari DE, Dan D. Inadvertent trans-arterial lead placement in the left ventricle and aortic cusp: percutaneous lead removal with carotid embolic protection and stent graft placement. *Indian Pacing Electrophysiol J* 2012; 12:269–273.
- Villanueva FS, Heinsimer JA, Burkman MH, Fananapazir L, Halvorsen RA Jr, Chen JT. Echocardiographic detection of perforation of the cardiac ventricular septum by a permanent pacemaker lead. *Am J Cardiol* 1987; 59:370–371.
- Döring M, Braunschweig F, Eitel C, et al. Individually tailored left ventricular lead placement: lessons from multimodality integration between three-dimensional echocardiography and coronary sinus angiogram. *Europace* 2013; 15:718–727.
- Mediratta A, Addetia K, Yamat M, et al. 3D echocardiographic location of implantable device leads and mechanism of associated tricuspid regurgitation. *JACC Cardiovasc Imaging* 2014; 7:337–347.
- Daher IN, Saeed M, Schwarz ER, Agoston I, Rahman MA, Ahmad M. Live three-dimensional echocardiography in diagnosis of interventricular septal perforation by pacemaker lead. *Echocardiography* 2006; 23:428–429.
- Mak GS, Truong QA. Cardiac CT: imaging of and through cardiac devices. *Curr Cardiovasc Imaging Rep* 2012; 5:328–336.
- Henrikson CA, Leng CT, Yuh DD, Brinker JA. Computed tomography to assess possible cardiac lead perforation. *Pacing Clin Electrophysiol* 2006; 29:509–511.
- Hirschl DA, Jain VR, Spindola-Franco H, Gross JN, Haramati LB. Prevalence and characterization of asymptomatic pacemaker and ICD lead perforation on CT. *Pacing Clin Electrophysiol* 2007; 30:28–32.
- Pang BJ, Lui EH, Joshi SB, et al. Pacing and implantable cardioverter defibrillator lead perforation as assessed by multiplanar reformatted ECG-gated cardiac computed tomography and clinical correlates. *Pacing Clin Electrophysiol* 2014; 37:537–545.
- Lanzman RS, Winter J, Blondin D, et al. Where does it lead? Imaging features of cardiovascular implantable electronic devices on chest radiograph and CT. *Korean J Radiol* 2011; 12:611–619.
- van der Graaf AV, Bhagirath P, Götte MJ. MRI and cardiac implantable electronic devices; current status and required safety conditions. *Neth Heart J* 2014; 22:269–276.
- European Society of Cardiology (ESC), European Heart Rhythm Association (EHRA); Brignole M, Auricchio A, Baron-Esquivias G, et al. 2013 ESC guidelines on cardiac pacing and cardiac resynchronization therapy: the Task Force on cardiac pacing and resynchronization therapy of the European Society of Cardiology (ESC). Developed in collaboration with the European Heart Rhythm Association (EHRA). *Europace* 2013; 15:1070–1118.
- Eikelboom JW, Connolly SJ, Brueckmann M, et al; RE-ALIGN Investigators. Dabigatran versus warfarin in patients with mechanical heart valves. *N Engl J Med* 2013; 369:1206–1214.

ADDRESS: Richard G. Trohman, MD, MBA, Department of Internal Medicine, Rush University Medical Center, 1717 West Congress Parkway, Room 301 Kellogg, Chicago IL 60610; rtrohman@rush.edu