



Persistent rash on feet

The diagnosis hid in the shadows until we turned on an ultraviolet light.

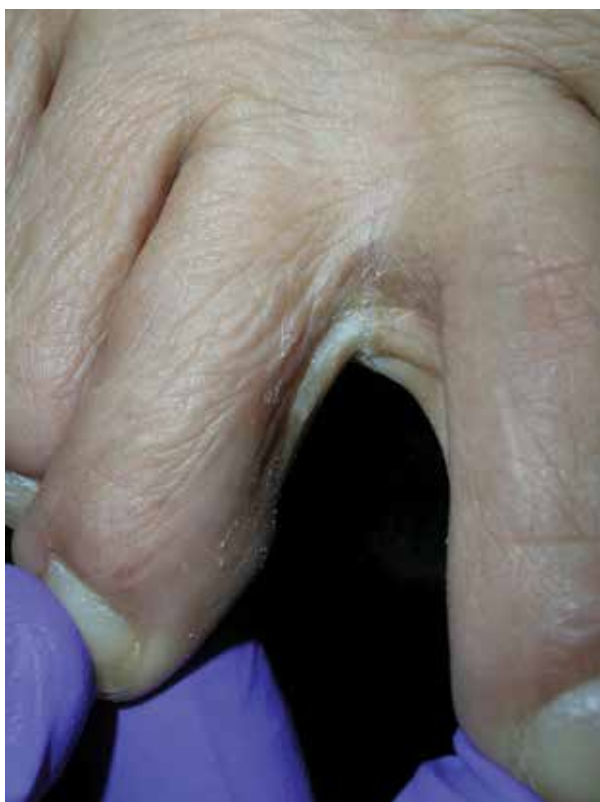A 49-YEAR-OLD HISPANIC WOMAN presented with a 4-month history of scaling and a macerated rash localized between her toes (FIGURE 1). The rash was malodorous, mildly erythematous, and sometimes associated with pruritus. The patient had no relevant medical history. Potassium hydroxide (KOH) testing was performed and found to be negative. So

a Wood's lamp was used to examine the patient's toes—and it revealed the diagnosis.

- WHAT IS YOUR DIAGNOSIS?
- HOW WOULD YOU TREAT THIS PATIENT?

FIGURE 1

Interdigital scaling and a macerated rash



IMAGES COURTESY OF: RICHARD P. USATINE, MD

Theresa Vo, MD; Richard P. Usatine, MD
University of Texas Health at San Antonio

Usatine@uthscsa.edu

DEPARTMENT EDITOR
Richard P. Usatine, MD
University of Texas Health at San Antonio

The authors reported no potential conflict of interest relevant to this article.

**Diagnosis:
Erythrasma**

The Wood’s lamp revealed a coral-red fluorescence in the interdigital spaces (FIGURE 2), which led us to a diagnosis of erythrasma.

The coral-red fluorescence seen under the Wood’s lamp is due to porphyrins produced by *Corynebacterium minutissimum*. The organism invades the stratum corneum where it proliferates and causes erythrasma. Erythrasma typically appears as delineated, dry, red-brown patches in intertriginous areas, such as the axilla, groin, interdigital spaces, intergluteal cleft, perianal skin, and inframammary area.^{1,2}

Interdigital erythrasma is more common than previously thought; in one study of 151 patients with erythrasma, the most common site was the toe webs (64.9%), followed by the inguinal region (17.9%), the axillary region (14.6%), and the inframammary region (2.6%).² Erythrasma affects 4% of the population; risk factors include poor hygiene, hyperhidrosis, obesity, warm climate, diabetes, and an immunocompromised state.³

**Differential includes
“athlete’s foot”**

The differential diagnosis for a pruritic rash between the toes includes:

■ **Tinea pedis.** Erythrasma is often mis-

taken for tinea pedis, because both conditions cause scaling between the toes. A Wood’s lamp exam can quickly differentiate between the 2,¹ as tinea pedis does not fluoresce under ultra-violet light.

■ **Contact dermatitis** mimics many conditions, but a negative Wood’s lamp exam and history of worsening with contact to specific substances helps to make this diagnosis.

**Prevention and Tx hinge
on good hygiene, topical agents**

First-line management of erythrasma includes both nonpharmacologic and pharmacologic modalities. Good hygiene and, depending on the area affected, loose-fitting cotton undergarments can help treat and prevent erythrasma.

■ **Topical 2% miconazole** bid for 2 weeks has resulted in clearance rates as high as 88%.⁴ Its affordable price, over-the-counter availability, and lack of adverse effects make miconazole a reasonable choice.^{4,5} It is also a smart treatment choice when erythrasma is coexisting with tinea, because it can treat both conditions. This is not uncommon in the interdigital spaces between the toes and in the groin.

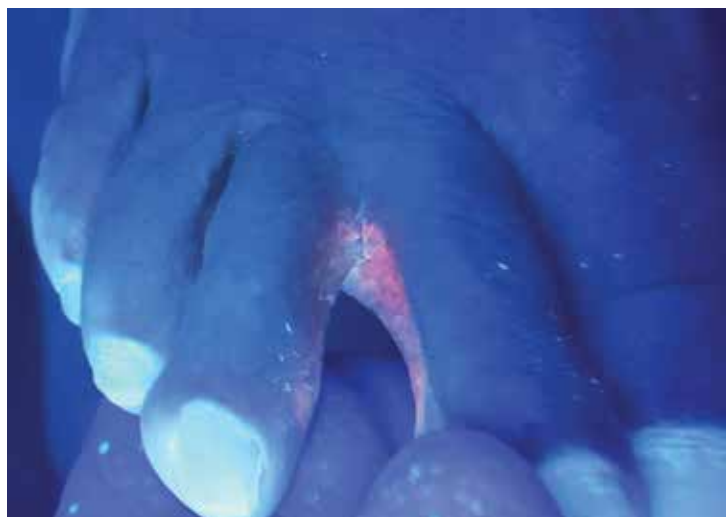
■ **Topical 1% clindamycin or 2% erythromycin** solution or gel bid for 2 weeks can also be used to treat the condition.^{3,6} However, given that topical antibiotics are more expensive than single-dose oral treatment and are no better than the oral formulations of these antibiotics,⁶ clarithromycin 1 g taken once orally may be preferred.^{2,6}

■ **Our patient** was treated with a single dose of clarithromycin 1 g. At follow-up, her erythrasma was clear. **JFP**

CORRESPONDENCE

Richard P. Usatine, MD, University of Texas Health at San Antonio, 7703 Floyd Curl Dr., San Antonio, TX 78229; Usatine@uthscsa.edu.

FIGURE 2
Wood’s lamp reveals coral-red fluorescence



References

1. Polat M, Ihan MN. The prevalence of interdigital erythrasma: a prospective study from an outpatient clinic in Turkey. *J Am Podiatr Med Assoc.* 2015;105:121-124.
2. Avci O, Tanyildizi T, Kusku E. A comparison between the effectiveness of erythromycin, single-dose clarithromycin and topical fusidic acid in the treatment of erythrasma. *J Dermatolog Treat.* 2013;24:70-74.
3. Kibbi AG, Sleiman M. Erythrasma. Available at: [108](http://emedi-

</div>
<div data-bbox=)

cinemedscape.com/article/1052532-overview#a0199. Accessed December 10, 2016.

- Pitcher DG, Noble WC, Seville RH. Treatment of erythrasma with miconazole. *Clin Exp Dermatol*. 1979;4:453-456.
- Clayton YM, Knight AG. A clinical double-blind trial of topi-

cal miconazole and clotrimazole against superficial fungal infections and erythrasma. *Clin Exp Dermatol*. 1976;1:225-232.

- Holdiness MR. Management of cutaneous erythrasma. *Drugs*. 2002;62:1131-1141.



The Medical Intelligence Quiz

*Challenge Yourself,
Build Your Knowledge*

Now Accepting MD-IQ QUIZZES from Readers!

We invite our health care professional readers to develop a 5-question quiz based on a clinically relevant topic in your specialty.

A great MD-IQ quiz submission should:

- A** Test the knowledge of your peers
- B** Inform clinical practice and patient care
- C** Educate your peers on current hot topics in your specialty
- D** All of the above

Answer: D, All of the above!



Interested in submitting a quiz and seeing your byline on MD-IQ?
Request author guidelines by sending an email to
MDIQ@frontlinemedcom.com.