

Hereditary Hypotrichosis Simplex of the Scalp

Ronda S. Farah, MD; Heather M. Holahan, MD; Molly S. Moye, MD; Mary S. Stone, MD; Brian L. Swick, MD



PRACTICE POINTS

- Hereditary hypotrichosis simplex (HHS) is a rare form of hypotrichosis that typically presents in school-aged children as worsening hair loss localized to the scalp.
- Historically, HHS has been largely regarded as autosomal dominant, with variable severity also described within families.
- There is no effective treatment of HHS. Due to potential phenotypic variation, patients should be counseled that they may experience progressive or possible total loss of scalp hair by the third decade of life.

A 7-year-old girl presented with gradual thinning of the scalp hair of 3 to 4 years' duration. Her mother reported the patient had normal hair density at birth. Over the next several years, she was noted to have an inability to grow lengthy hair. At approximately 3 years of age, thinning of scalp hair was identified. There was no prior history of increased shedding, hypohidrosis, or tooth or nail abnormalities. Family history revealed fine hair in her older sister and fine thin hair at the frontal scalp in her mother. Her mother reported similar inability to grow lengthy hair. Physical examination of the patient demonstrated short blonde hair with diffuse thinning of the crown (Figure 1). The longest hair was approximately 10 cm in length. Follicular ostia were without erythema

To the Editor:

Hereditary hypotrichosis simplex (HHS) (Online Mendelian Inheritance in Man [OMIM] 146520) is a rare form of hypotrichosis that typically presents in school-aged children as worsening hair loss localized to the scalp.¹ Most patients are unaffected at birth and otherwise healthy without abnormalities of the nails, teeth, or perspiration. Examination of the scalp reveals normal follicular ostia and absence of scale and erythema; however, decreased follicular density may be noted.¹ The histopathologic findings of HHS reveal velluslike hair follicles without associated fibrosis or inflammation.² Examination of hair follicles with light microscopy is unremarkable.^{3,4} Historically, this condition has been largely regarded as autosomal dominant, with variable severity also described within families. Herein, we report a case of this rare disease in a child, with 2 family members displaying a less severe phenotype.

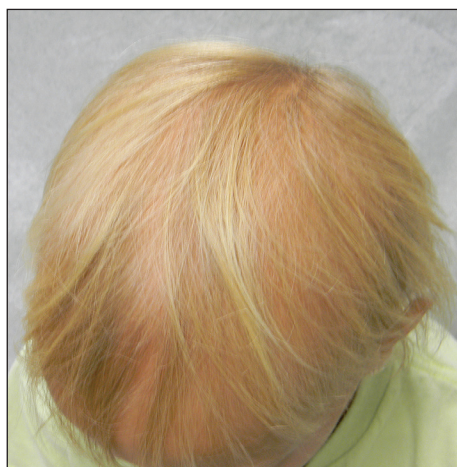

FIGURE 1. Hereditary hypotrichosis simplex of the scalp characterized by short blonde hair with diffuse thinning of the crown.

Dr. Farah is from the Department of Dermatology, University of Minnesota, Minneapolis. Dr. Holahan is from the Department of Dermatology, Rutgers Robert Wood Johnson Medical School, Somerset, New Jersey. Dr. Moye is from Forefront Dermatology, Louisville, Kentucky. Drs. Stone and Swick are from the Department of Dermatology, University of Iowa, Iowa City. The authors report no conflict of interest.

Correspondence: Ronda S. Farah, MD, Department of Dermatology, University of Minnesota, 516 Delaware St SE, Minneapolis, MN 55455 (rfarah@umn.edu).

or scale but notably fewer in number on the crown. Eyebrows, eyelashes, teeth, and fingernails were without abnormalities. A hair pull test was negative and hair mount revealed normal bulb and shaft. Microscopy of hair shafts under polarized light was unremarkable.

Two punch biopsies were obtained and submitted for vertical and horizontal sectioning. Sections demonstrated an intact epidermis, decreased follicle number, and small follicles with hypoplastic velluslike appearance (Figure 2). Fibrosis and inflammation were not seen; there was no increase in catagen or telogen hairs. Clinical and histopathological findings were consistent with HHS.

Hereditary hypotrichosis localized to the scalp was first described by Toribio and Quinones⁵ in 1974 in a large Spanish family presenting with normal scalp hair at birth followed by gradual diffuse hair loss. Hair loss that usually began in school-aged children with subsequent few fine hairs remaining on the scalp by the third decade of life was identified in these individuals. Eyelashes, eyebrows, pubic, axillary, and other truncal hairs were normal.⁵ Several similar cases of HHS localized to the scalp have since been reported.^{2,6} Hereditary hypotrichosis simplex is inherited in an autosomal-dominant fashion, with the exception of 1 reported sporadic case.³

Research on HHS has primarily focused on genetic analyses of several affected families. Betz et al⁷ mapped the gene for HHS to band 6p21.3 in 2 families of Danish origin and in the Spanish family initially described by Toribio and Quinones.⁵ Three years later, a nonsense mutation in the *CDSN* gene encoding corneodesmosin was described.⁸ Despite these genetic advances, the pathogenesis of HHS and the role that corneodesmosin may play remain unclear.

Generalized forms of hypotrichosis (OMIM #605389) have long been reported and described as loss of scalp hair with involvement of eyebrows, eyelashes, and other

body hair.⁹ Genetic studies have allowed for genome-wide linkage analysis, linking 3 families with this more generalized HHS phenotype to chromosome 18; specifically, an Italian family with sparse scalp and body hair but normal eyelashes and eyebrows,⁴ and 2 Pakistani families with thinning scalp hair and sparse truncal hair.¹⁰ A mutation in the APC downregulated 1 gene, *APCDD1*, also has been identified in these families.¹⁰ These genetic findings indicate that the generalized form of HHS is a distinct syndrome.

The differential diagnosis of HHS includes Marie-Unna hereditary hypotrichosis, loose anagen hair syndrome, trichothiodystrophy, and androgenetic alopecia. Marie-Unna hereditary hypotrichosis usually presents as near-complete absence of scalp hair at birth, development of wiry twisted hair in childhood, and progressive alopecia.³ Loose anagen hair syndrome usually demonstrates a ruffled cuticle on hair pull test and remits in late childhood. Polarization of the hair shaft can identify patients with trichothiodystrophy. Follicular miniaturization may lead one to consider early-onset androgenetic alopecia in some patients.

There is no effective treatment of HHS. Due to potential phenotypic variation, patients should be counseled that they may experience progressive or possible total loss of scalp hair by the third decade of life.^{2,3,5} As with other hair loss disorders, wigs or additional over-the-counter cosmetic options may be considered.³ Currently, there are no known patient resources specific for HHS. Therefore, our patient's family was referred to the National Alopecia Areata Foundation website (<https://naaf.org/>) for resources on discussing alopecia with school-aged children. The psychological impact of alopecia should not be overlooked and psychiatric referral should be provided, if needed. Examination of family members along with clinical monitoring are recommended. Genetic counseling also may be offered.³

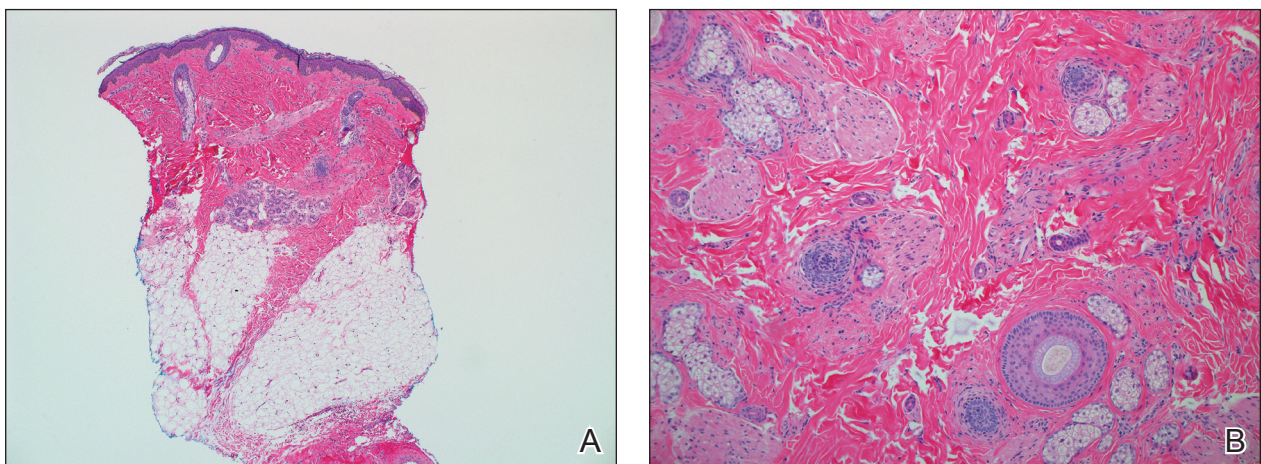


FIGURE 2. Hereditary hypotrichosis simplex of the scalp. Histopathology revealed a normal epidermis with decreased follicle number and hypoplastic hair follicles and no evidence of inflammation or fibrosis (A and B)(H&E, original magnifications $\times 40$ and $\times 100$).

REFERENCES

1. Rodríguez Díaz E, Fernández Blasco G, Martín Pascual A, et al. Heredity hypotrichosis simplex of the scalp. *Dermatology*. 1995; 191:139-141.
2. Ibsen HH, Clemmensen OJ, Brandrup F. Familial hypotrichosis of the scalp. autosomal dominant inheritance in four generations. *Acta Derm Venereol*. 1991;71:349-351.
3. Cambiaghi S, Barbareschi M. A sporadic case of congenital hypotrichosis simplex of the scalp: difficulties in diagnosis and classification. *Pediatr Dermatol*. 1999;16:301-304.
4. Baumer A, Belli S, Trueb RM, et al. An autosomal dominant form of hereditary hypotrichosis simple maps to 18p11.32-p11.23 in an Italian family. *Eur J Hum Genet*. 2000;8:443-448.
5. Toribio J, Quinones PA. Heredity hypotrichosis simplex of the scalp. evidence for autosomal dominant inheritance. *Br J Dermatol*. 1974;91:687-696.
6. Kohn G, Metzker A. Hereditary hypotrichosis simplex of the scalp. *Clin Genet*. 1987;32:120-124.
7. Betz RC, Lee YA, Bygum A, et al. A gene for hypotrichosis simplex of the scalp maps to chromosome 6p21.3. *Am J Hum Genet*. 2000;66:1979-1983.
8. Levy-Nissenbaum E, Betz R, Frydman M, et al. Hypotrichosis of the scalp is associated with nonsense mutations in CDSN encoding corneodesmosin. *Nat Genet*. 2003;34:151-153.
9. Just M, Ribera M, Fuente MJ, et al. Hereditary hypotrichosis simplex. *Dermatology*. 1998;196:339-342.
10. Shimomura Y, Agalliu D, Vonica A, et al. APCDD1 is a novel Wnt inhibitor mutated in hereditary hypotrichosis simplex. *Nature*. 2011;44:1043-1047.