

Black Adherence Nodules on the Scalp Hair Shaft



Patrick M. Kupiec, MD; Audrey N. Green, MD; Katherine C. Marks, DO

Eligible for 1 MOC SA Credit From the ABD

This Photo Challenge in our print edition is eligible for 1 self-assessment credit for Maintenance of Certification from the American Board of Dermatology (ABD). After completing this activity, diplomates can visit the ABD website (<http://www.abderm.org>) to self-report the credits under the activity title "Cutis Photo Challenge." You may report the credit after each activity is completed or after accumulating multiple credits.



Photograph courtesy of Eric Hossler, MD (Danville, Pennsylvania).

A 21-year-old woman presented to the dermatology clinic with what she described as small black dots in her hair that she first noted 3 months prior to presentation. The black nodules were asymptomatic, but the patient noted that they seemed to be moving up the hair shaft. They were firmly attached and great effort was required to remove them. The patient's sister recently developed similar nodules. The patient and her sister work as missionaries and had spent time in India, Southeast Asia, and Central America within the last few years. Physical examination revealed firmly adherent black nodules involving the mid to distal portions of the hair shafts on the scalp. There were no nail or skin findings. Cultures were obtained, and microscopic examination was performed.

WHAT'S THE DIAGNOSIS?

- monilethrix
- pediculosis capitis
- pedra
- tinea capitis
- trichorrhexis nodosa

PLEASE TURN TO **PAGE 38** FOR THE DIAGNOSIS

MORE ONLINE

>> Test your skills with more Photo Challenges online at www.mdedge.com/cutis/photo-challenge

From the Department of Dermatology, Geisinger Medical Center, Danville, Pennsylvania. Dr. Kupiec was from the State University of New York, Upstate Medical University, Syracuse.

The authors report no conflict of interest.

Correspondence: Patrick M. Kupiec, MD, Department of Dermatology, Geisinger Medical Center, 115 Woodbine Ln, Danville, PA 17822-5206 (pkupiec87@gmail.com).

THE DIAGNOSIS:

Piedra

Microscopic examination of the hair shafts revealed brown to black, firmly adherent concretions (Figure 1). Scanning electron microscopy of the nodules was performed, which allowed for greater definition of the constituent hyphae and arthrospores (Figure 2).

Fungal cultures grew *Trichosporon inkin* along with other dematiaceous molds. The patient initially was treated with a combination of ketoconazole shampoo and weekly application of topical terbinafine. She trimmed 15.2 cm of the hair of her own volition. At 2-month follow-up the nodules were still present, though smaller and less numerous. Repeat cultures were obtained, which again grew *T inkin*. She then began taking oral terbinafine 250 mg daily for 6 weeks.

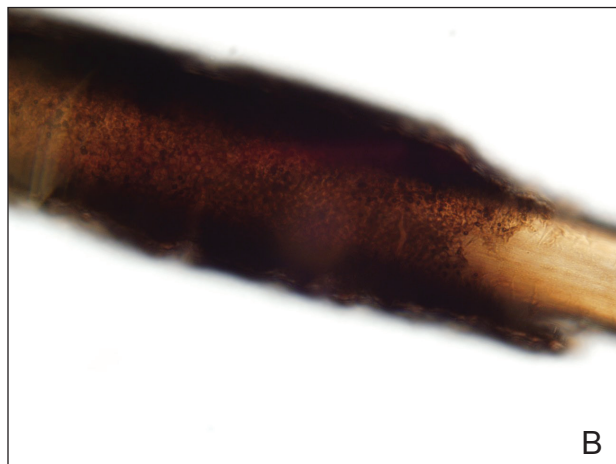


FIGURE 1. Piedra findings on microscopic examination of the hair shafts under light microscopy including brown to black firmly adherent concretions (A and B)(original magnifications $\times 100$ and $\times 400$). Photograph courtesy of Eric Hossler, MD (Danville, Pennsylvania).

This case of piedra is unique in that our patient presented with black nodules clinically, but cultures grew only the causative agent of white piedra, *T inkin*. A search of PubMed articles indexed for MEDLINE using the terms *black piedra*, *white piedra*, or *piedra*, and *mixed infection* or *coinfection* yielded one other similar case.¹ Kanitakis et al¹ speculated that perhaps there was coinfection of black and white piedra and that *Piedraia hortae*, the causative agent of black piedra, was unable to flourish in culture facing competition from other fungi. This scenario also could apply to our patient. However, the original culture taken from our patient also grew other dematiaceous molds including *Cladosporium* and *Exophiala* species. It also is possible that these other fungi could have contributed pigment to the nodules, giving it the appearance of black piedra when only *T inkin* was present as the true pathogen.

White piedra is a rare fungal infection of the hair shaft caused by organisms of the genus *Trichosporon*, with *Trichosporon ovoides* most likely to infect the scalp.² Black piedra is a similar fungal infection caused by *P hortae*. Piedra means stone in Spanish, reflecting the appearance of these organisms on the hair shaft. It is common in tropical regions of the world such as Southeast Asia and South America, flourishing in the high temperatures and humidity.² Both infectious agents are found in the soil or in standing water.³ White piedra most commonly is found in facial, axilla, or pubic hair, while black piedra most often is found in the hair of the scalp.^{2,4}




FIGURE 2. Piedra findings on scanning electron microscopy of the nodules allowed for greater definition of the constituent hyphae and arthrospores. Photograph courtesy of Fred E. Hossler, PhD (Johnson City, Tennessee).

Local cultural practices may contribute to transfer of *Trichosporon* or *P hortae* to the scalp, including the use of Brazilian plant oils in the hair or tying a veil or hijab to wet hair. Interestingly, some groups intentionally introduce the fungus to their hair for cosmetic reasons in endemic areas.^{2,3,5}

Patients with white or black piedra generally are asymptomatic.⁴ Some may notice a rough texture to the hair or hear a characteristic metallic rattling sound as the nodules make contact with brush bristles.^{2,3} On inspection of the scalp, white piedra will appear to be white to light brown nodules, while black piedra presents as brown to black in color. The nodules are often firm on palpation.^{2,3} The nodules of white piedra generally are easy to remove in contrast to black piedra, which involves nodules that securely attach to the hair shaft but can be removed with pressure.^{3,5} Piedra has natural keratolytic activities and with prolonged infection can penetrate the hair cuticle, causing weakness and eventual breakage of the hair. This invasion into the hair cortex also can complicate treatment regimens, contributing to the chronic course of these infections.⁶

Diagnosis is based on clinical and microscopic findings. Nodules on hair shafts can be prepared with potassium hydroxide and placed on glass slides for examination.⁴ Dyes such as toluidine blue or chlorazol black E stain can be used to assist in identifying fungal structures.² Sabouraud agar with cycloheximide may be the best choice for culture medium.² Black piedra slowly grows into small dome-shaped colonies. White piedra will grow more quickly into cream-colored colonies with wrinkles and sometimes mucinous characteristics.³

The best treatment of black or white piedra is to cut the hair, thereby eliminating the fungi,⁷ which is not an easy option for many patients, such as ours, because of the aesthetic implications. Alternative treatments include azole shampoos such as ketoconazole.^{2,4} Treatment with oral terbinafine 250 mg daily for 6 weeks has been successfully used for black piedra.⁷ Patients must be careful to thoroughly clean or discard hairbrushes, as they can serve as reservoirs of fungi to reinfect patients or spread to others.^{5,7}

REFERENCES

1. Kanitakis J, Persat F, Piens MA, et al. Black piedra: report of a French case associated with *Trichosporon asahii*. *Int J Dermatol*. 2006; 45:1258-1260.
2. Schwartz RA. Superficial fungal infections. *Lancet*. 2004;364:1173-1182.
3. Khatu SS, Poojary SA, Nagpur NG. Nodules on the hair: a rare case of mixed piedra. *Int J Trichology*. 2013;5:220-223.
4. Elewski BE, Hughey LC, Sobera JO, et al. Fungal diseases. *Dermatology*. 3rd ed. Philadelphia, PA: Elsevier Health Sciences; 2012:1251-1284.
5. Desai DH, Nadkarni NJ. Piedra: an ethnicity-related trichosis? *Int J Dermatol*. 2013;53:1008-1011.
6. Figueras M, Guarro J, Zaror L. New findings in black piedra infection. *Br J Dermatol*. 1996;135:157-158.
7. Gip L. Black piedra: the first case treated with terbinafine (Lamisil). *Br J Dermatol*. 1994;130(suppl 43):26-28.