

Trans-Scaphoid Transcapitate Perilunate Fracture-Dislocation

Vasilios A. Kontogeorgakos, MD, Andreas F. Mavrogenis, MD, Panayiotis Megaloikonomos, MD, Georgios Panagopoulos, MD, Vasilios Mandalos, MD, and Leonidas Badras, MD

Abstract

Trans-scaphoid transcapitate (TSTC) perilunate fracture-dislocation (PLFD) is a rare type of perilunate injury. Because of the rarity and complexity of this entity, initial diagnosis may be delayed and the extent of osseous and ligamentous lesions underestimated. Early surgical treatment by open reduction and fracture stabilization is recommended to avoid complications such as avascular necrosis, nonunion, posttraumatic arthritis, and functional impairment.

In this article, we report the case of a 32-year-old man who sustained a TSTC-PLFD. We describe the radiographic and intraoperative findings, review the current surgical principles for reduction and stabilization of this injury, and assess the clinical and radiologic outcomes.

Trans-scaphoid transcapitate (TSTC) perilunate fracture-dislocation (PLFD) is a rare hyperextension wrist injury characterized by fracture of both the scaphoid and the capitate and rotation of the proximal bone fragment of the capitate.¹ Isolated capitate fractures with or without rotation of its proximal fragment have been well described.^{2,3} Obviously, this specific type of injury represents just the osseous part of a more complex ligamentous wrist injury.^{2,3}

TSTC-PLFD was first described by Nicholson⁴ in 1940. In 1956, Fenton⁵ coined the term *scapho-capitate syndrome*, which became widely known. With PLFD, accurate diagnosis may be delayed. Usually, only the scaphoid fracture is identified by

Take-Home Points

- TSTC-PLFD is a rare hyperextension wrist injury characterized by fracture of both the scaphoid and the capitate and rotation of the proximal bone fragment of the capitate.
- TSTC-PLFD is associated by a complex ligamentous injury of the wrist.
- Impaction of the wrist in extension seems to be the most important predictor of this injury.
- Optimal treatment for TSTC-PLFD is open reduction, anatomical alignment, and ligamentous and osseous stabilization.
- The most important complications of scaphoid and capitate fractures and PLFD are osteonecrosis and nonunion.

radiologic examination, and thus the severity of the injury is underestimated and appropriate treatment delayed.^{3,6,7}

The English literature includes only case reports and small series on this rare perilunate injury.^{6,9} In this article, we report the case of an adult with TSTC-PLFD. We describe the radiographic and intraoperative findings, review the current surgical principles for reduction and stabilization of this injury, and assess the clinical and radiologic outcomes. The patient provided written informed consent for print and electronic publication of this case report.

Case Report

A 32-year-old man sustained an isolated injury of his right (dominant) hand after falling from a height of 6 feet and landing on his outstretched right arm with the wrist in extension. Physical examination at admission revealed swelling over the dorsum

Authors' Disclosure Statement: The authors report no actual or potential conflict of interest in relation to this article.

of the wrist and pain on palpation. Radiographs showed a fracture of the waist of the scaphoid (**Figure 1**). In addition, the capitate was fractured with the proximal fragment rotated 180° (Figure 1, **Figure 2**). A small avulsion fracture on the dorsal surface of the wrist was obvious as well (Figure 2). A perilunate injury was diagnosed and surgical treatment recommended.

With the patient under general anesthesia and a humerus tourniquet applied, an external fixator was placed for spanning of the wrist joint. The dorsal aspect of the wrist joint was approached through a midline longitudinal 5-cm incision, centered over the Lister tubercle. For adequate exposure of the dorsal wrist, a flap of the dorsal capsule was raised with the apex at the triquetrum and a radial broad base, as previously described.⁹ An avulsion fracture at the insertion of the dorsal capsule to the triquetrum was observed. The dorsal surface of the hamate and lunate showed a small area of bone contusion with hemorrhagic infiltration. The scapholunate and lunotriquetral ligaments were intact. The proximal fragment of the capitate was identified deep into the space between the lunate and distal capitate fragment; the articular surface of the bone fragment was rotated 180° distally (**Figure 3**). Distraction was applied through the external fixator, and the bone fragment was removed from the surgical site. The cartilaginous surface was scratched, but no chondral flap or defect was observed. Hematoma and debris were removed, and the bone fragment was restored to its anatomical position. Two 1.6-mm Kirschner wires (K-wires) were inserted in a distal-to-proximal direction to stabilize the capitate fracture without engaging the lunate. The scaphoid fracture was reduced and stabilized with an antegrade double-threaded compression screw. Then, both K-wires were advanced proximally, engaging the lunate, to try to enhance midcarpus anteroposterior stability (**Figure 4**). The scapholunate and lunotriquetral intervals were stable. Last, the wound was sutured in layers, and the external fixator was locked with the wrist in 0° of flexion-extension and 0° of radioulnar deviation.

Skin sutures were removed 2 weeks after surgery, K-wires 6 weeks after surgery, and the external fixator 8 weeks after surgery. At 8 weeks, radiographs showed healing of both fractures, scaphoid and capitate. The patient was allowed gradual passive and active-assisted range-of-motion exercises of the wrist at 8 weeks, and he returned to work 3 months after surgery. At

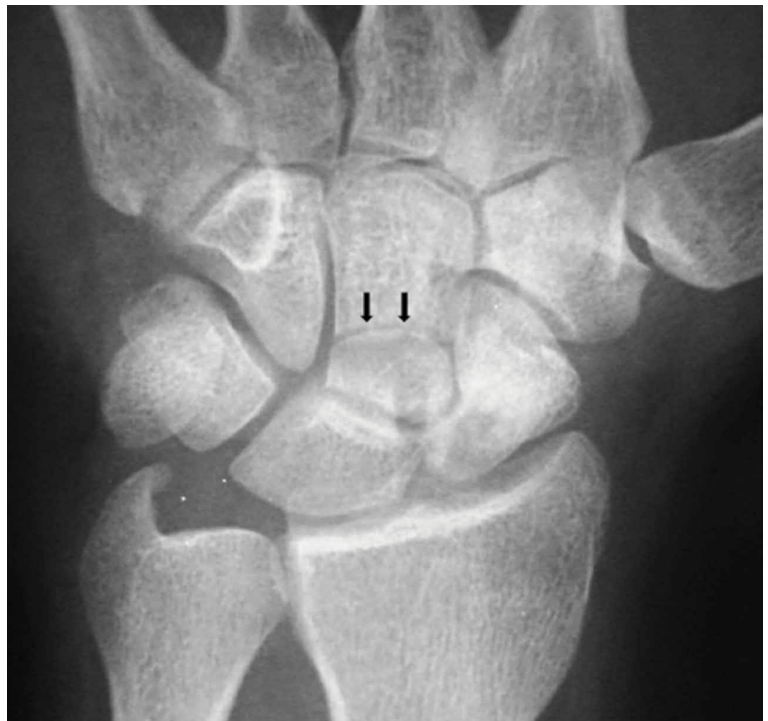

Figure 1. Anteroposterior radiograph of the right wrist shows a fracture of the capitate with the fracture line (black arrows) extending proximally to the waist of the capitate.

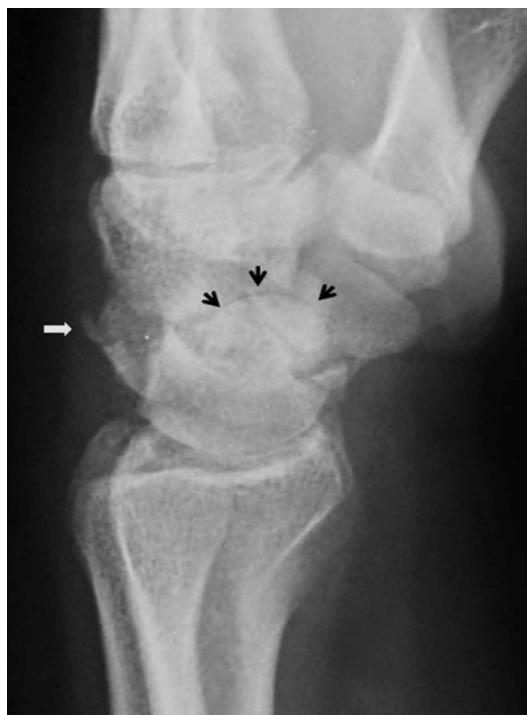

Figure 2. Lateral radiograph of the right wrist shows the domed articular surface of the proximal capitate fragment (black arrows) and an avulsion flake fracture of the dorsal surface of the triquetrum (white arrow). The capitate fragment is rotated 180° facing distally and is displaced palmarly between the lunate and the distal capitate fragment.

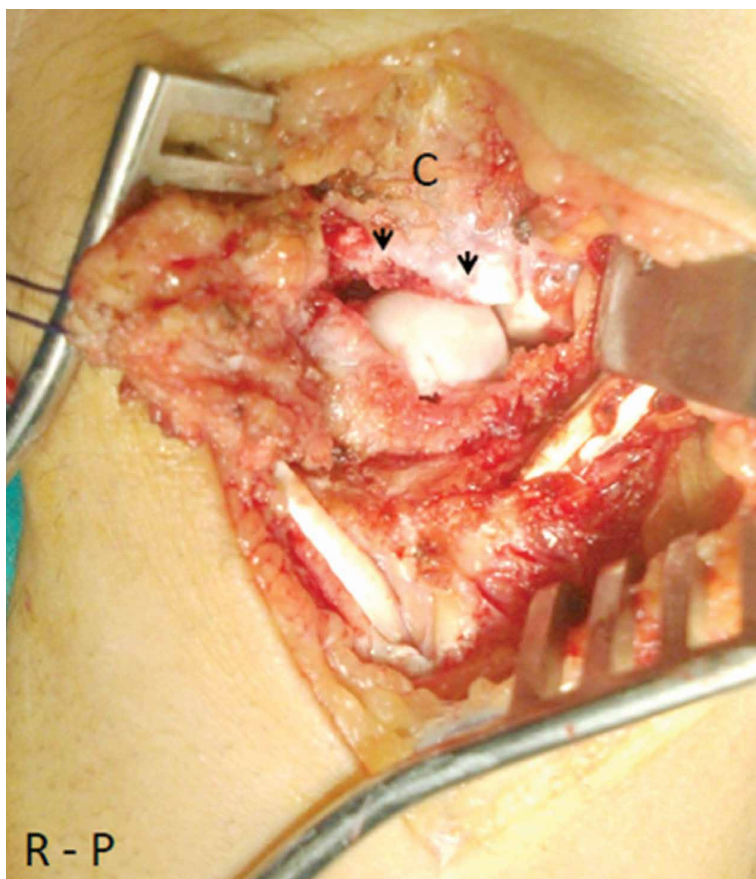


Figure 3. Intraoperative photograph shows the dorsal capsular flap retracted radially, common extensor tendons retracted ulnarly, and the transverse, short oblique fracture line running through the capitate (black arrowheads). The bone marrow of the fractured surface is obvious at the distal side of the fracture gap, and the articular cartilage of the proximal fragment is obvious at the proximal side.

Abbreviations: C, capitate, proximal fragment; R-P, radial and proximal side of the dorsum of wrist.

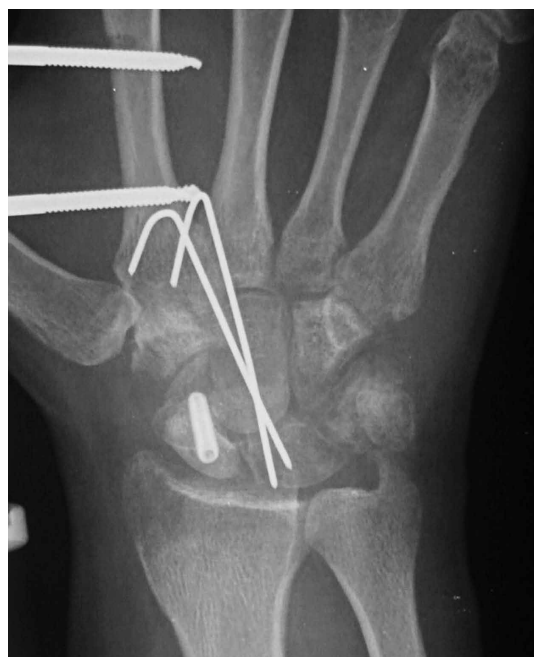

Figure 4. Anteroposterior radiograph of the right wrist at 6-week follow-up.

12-month follow-up, all fractures were completely healed, and the wrist was stable and pain-free. At 24-month follow-up, the patient was asymptomatic, had no ulnar translation of the right wrist joint, and showed full range of pronation-supination, a 10° lag of wrist flexion, and a 20° lag of extension in comparison with the left wrist. Mayo wrist score was excellent (95 points). Radiographs of the right wrist showed fracture healing and ligamentous stability of the carpal joints (**Figure 5**).

Discussion

The exact biomechanism of TSTC-PLFD is unclear. Impaction of the wrist in extension seems to be the most important predictor of this injury.^{5,7,9-11} According to Stein and Siegel,¹⁰ scaphoid fractures first allow hyperextension of the wrist; the lunate and the capitate rotate dorsally, and the dorsal surface of the capitate impacts the dorsal edge of the distal radius, causing a fracture of the neck of the capitate. If the wrist continues to rotate into further hyperextension, the unsupported, proximal part of the capitate rotates 90° around itself.^{9,10} When the carpus returns to neutral position, the bone fragment of the capitate rotates further, reaching a position of 180°, with its proximal articular surface facing distally. In this type of injury, the axis of rotation is transverse (radioulnar), in contrast to the perpendicular (anteroposterior) axis of rotation suggested by the initial report by Fenton.⁵ The scaphoid is fractured by impaction of the radial styloid process. Monahan and Galasko¹¹ reported a case of capitate fracture with palmar displacement and 90° rotation of the proximal bone fragment; the fragmented surface was facing dorsally. A transverse axis of rotation, as in our patient's case, could explain this type of displacement supporting the mechanism of injury proposed by Stein and Siegel.¹⁰ Vance and colleagues⁷ described various patterns of scaphocapitate fractures and concluded that no single mechanism of injury accounts for these types of injuries. Other authors have considered scaphocapitate syndrome as a specific type of TSTC-PLFD, one that reduces either spontaneously or with manipulation.^{1,3,12} Detailed evaluation of standard anteroposterior and lateral wrist radiographs can provide enough evidence for the diagnosis of this injury. Computed tomography may define further the type and extent of injury.⁷ In our patient's case, wrist impaction caused the scaphoid and capitate fractures and the avulsion of the capsule attachment to the triquetrum. The distal fragment of the capitate subluxated dorsally

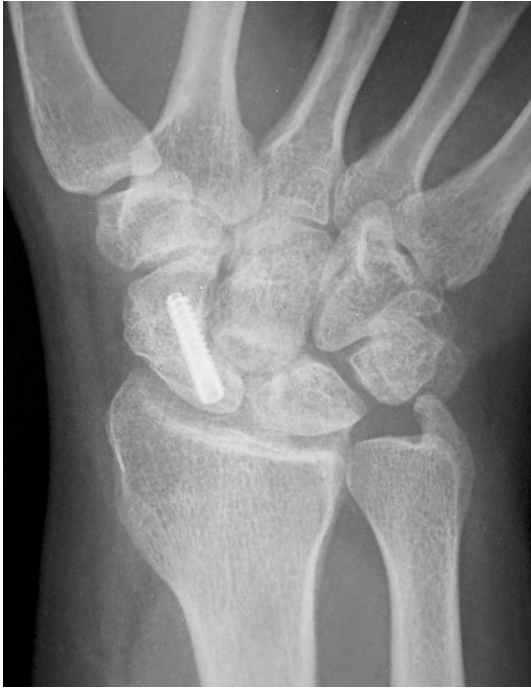

Figure 5. Anteroposterior radiograph of the right wrist at 24-month follow-up.

in relation to the lunate. The lateral radiograph of the wrist showed its position in the lunate fossa. According to the classification of Herzberg and colleagues¹² and Mayfield and colleagues,¹³ this represents a dorsal PLFD of the greater carpal bones arc.

Conservative treatment is not recommended for PLFD because closed reduction usually is not possible, and poor functional outcomes are common. Instead, optimal treatment is open reduction, anatomical alignment, and ligamentous and osseous stabilization.^{7,12,14,15} Dorsal, palmar, and combined approaches have been used in surgery for perilunate injuries. A dorsal approach through a radius-based capsular flap allows excellent exposure of the dorsal wrist and facilitates reduction of fractures.⁹ Capitate reduction should precede scaphoid reduction because scaphoid reduction cannot be easily maintained, especially when the fracture interface is comminuted.⁷ In addition, scaphoid reduction may be guided from the radial surface of the capitate. Moreover, when the scaphoid is fixated first, reduction of the rotated head of the capitate usually is difficult. In our patient's case, traction applied through the external fixator facilitated reduction and K-wire fixation of the capitate fracture. After scaphoid fixation, the K-wires were advanced through the capitate to the

lunate to stabilize the capitoulunate joint. The wrist must be immobilized for 6 to 8 weeks after surgical repair of PLFD. A cast can be used, but, as with our patient, an external fixator facilitates fracture reduction and wrist stability during osteosynthesis. During immobilization, the wrist should be maintained in neutral position to avoid stretching the dorsal and palmar wrist capsule and ligaments.¹⁶

The most important complications of scaphoid and capitate fractures and PLFD are osteonecrosis and nonunion.¹⁷⁻²⁰ Similar to scaphoid fractures, capitate fractures proximal to the waist of the capitate are associated with increased risk of osteonecrosis. Therefore, anatomical reduction and stabilization favor revascularization of the proximal bone fragment. Moreover, any osteonecrosis that occurs in the proximal part of the capitate is not an indication for further surgery as long as wrist height is maintained. Nonunion is not common after open reduction and internal fixation of PLFD (eg, our patient's fractures healed completely).¹⁷ Radiographically, nonunion is characterized by bone absorption and sclerosis of the ends of the bone. Treatment of capitate nonunion depends on symptom severity, bone fragment size, and radiographic evidence of arthritic changes.^{3,7,21-23} Treatment options include resection of sclerotic edges, bone grafting, and stabilization²¹ and removal of the proximal capitate fragment and limited arthrodesis,²² as arthritic changes likely are inevitable.^{22,23}

TSTC-PLFD is a rare wrist injury. Careful radiographic evaluation of the carpal bones and their relationships on both anteroposterior and lateral views is mandatory in making the correct diagnosis. Open reduction (preferably with use of an external fixator) and internal fixation are recommended for optimal healing and functional outcomes.

Dr. Kontogeorgakos and Dr. Mavrogenis are Assistant Professors of Orthopaedics, and Dr. Megalioikonomos and Dr. Panagopoulos are Orthopaedic Residents, First Department of Orthopaedics, Athens University Medical School, Attikon University General Hospital, Athens, Greece. Dr. Mandalos is an Orthopaedic Resident, and Dr. Badras is an Orthopaedic Surgeon, Department of Orthopaedics, General Hospital of Volos, Volos, Greece.

Address correspondence to: Vasilios A. Kontogeorgakos, MD, First Department of Orthopaedics, National and Kapodistrian University of Athens, School of Medicine, Attikon University General Hospital, 1 Rimini, 12462, Chaidari, Athens, Greece (tel, +30 2105831528; email, vaskonto@gmail.com).

Am J Orthop. 2017;46(4):E230-E234. Copyright Frontline Medical Communications Inc. 2017. All rights reserved.

References

1. Johnson RP. The acutely injured wrist and its residuals. *Clin Orthop Relat Res.* 1980;(149):33-44.
2. Volk AG, Schnell SB, Merkle P, Stevanovic M. Unusual capitate fracture: a case report. *J Hand Surg Am.* 1995;20(4):581-582.
3. Apergis E, Darmanis S, Kastanis G, Papanikolaou A. Does the term scaphocapitate syndrome need to be revised? A report of 6 cases. *J Hand Surg Br.* 2001;26(5):441-445.
4. Nicholson CB. Fracture dislocation of the os magnum. *J Roy Navy Med Serv.* 1940;26:289-291.
5. Fenton RL. The naviculo-capitate fracture syndrome. *J Bone Joint Surg Am.* 1956;38(3):681-684.
6. Strohm PC, Laier P, Müller CA, Gutorski S, Pfister U. Scapho-capitate fracture syndrome of both hands—first description of a bilateral occurrence of a rare carpal injury [in German]. *Unfallchirurg.* 2003;106(4):339-342.
7. Vance RM, Gelberman R, Evans EF. Scaphocapitate fractures. Patterns of dislocation, mechanisms of injury, and preliminary results of treatment. *J Bone Joint Surg Am.* 1980;62(2):271-276.
8. Apostolides JG, Lifchez SD, Christy MR. Complex and rare fracture patterns in perilunate dislocations. *Hand.* 2011;6(3):287-294.
9. Berger RA, Bishop AT, Bettinger PC. New dorsal capsulotomy for the surgical exposure of the wrist. *Ann Plast Surg.* 1995;35(1):54-59.
10. Stein F, Siegel MW. Naviculocapitate fracture syndrome. A case report: new thoughts on the mechanism of injury. *J Bone Joint Surg Am.* 1969;51(2):391-395.
11. Monahan PR, Galasko CS. The scapho-capitate fracture syndrome. A mechanism of injury. *J Bone Joint Surg Br.* 1972;54(1):122-124.
12. Herzberg G, Comtet JJ, Linscheid RL, Amadio PC, Cooney WP, Stalder J. Perilunate dislocations and fracture-dislocations: a multicenter study. *J Hand Surg Am.* 1993;18(5):768-779.
13. Mayfield JK, Johnson RP, Kilcoyne RK. Carpal dislocations: pathomechanics and progressive perilunar instability. *J Hand Surg Am.* 1980;5(3):226-241.
14. Moneim MS, Hofmann KE 3rd, Omer GE. Transscaphoid perilunate fracture-dislocation. Result of open reduction and pin fixation. *Clin Orthop Relat Res.* 1984;(190):227-235.
15. Andreasi A, Coppo M, Danda F. Trans-scapho-capitate perilunar dislocation of the carpus. *Ital J Orthop Traumatol.* 1986;12(4):461-466.
16. Song D, Goodman S, Gilula LA, Wollstein R. Ulnocarpal translation in perilunate dislocations. *J Hand Surg Eur.* 2009;34(3):388-390.
17. Rand JA, Linscheid RL, Dobyns JH. Capitate fractures: a long-term follow-up. *Clin Orthop Relat Res.* 1982;(165):209-216.
18. Panagis JS, Gelberman RH, Taleisnik J, Baumgaertner M. The arterial anatomy of the human carpus. Part II: the intraosseous vascularity. *J Hand Surg Am.* 1983;8(4):375-382.
19. Freedman DM, Botte MJ, Gelberman RH. Vascularity of the carpus. *Clin Orthop Relat Res.* 2001;(383):47-59.
20. Vander Griend R, Dell PC, Glowczewskie F, Leslie B, Ruby LK. Intraosseous blood supply of the capitate and its correlation with aseptic necrosis. *J Hand Surg Am.* 1984;9(5):677-683.
21. Rico AA, Holguin PH, Martin JG. Pseudarthrosis of the capitate. *J Hand Surg Br.* 1999;24(3):382-384.
22. Kumar A, Olney DB. Multiple carpometacarpal dislocations. *J Accid Emerg Med.* 1994;11(4):257-258.
23. Kohut GN. Extra-articular fractures of the distal radius in young adults. A technique of closed reposition and stabilization by mono-segmental, radio-radial external fixator. *Ann Chir Main Memb Super.* 1995;14(1):14-19.