

Human T-Lymphotropic Virus 1 Associated With Adult T-Cell Leukemia/Lymphoma

Travis James, DO, MHA; David Fivenson, MD; Jenny Cotton, MD, PhD

PRACTICE POINTS

- Adult T-cell leukemia/lymphoma (ATLL) is an uncommon neoplasm of mature T lymphocytes associated with infection by human T-lymphotropic virus 1.
- In the United States, ATLL is increasing in incidence in areas with large immigrant populations.
- High suspicion and clinical features must be present to make the diagnosis of ATLL due to considerable histologic overlap with other cutaneous T-cell lymphomas.

Adult T-cell leukemia/lymphoma (ATLL) is an uncommon neoplasm of mature T lymphocytes associated with infection by human T-lymphotropic virus 1 (HTLV-1), which is increasing in incidence in areas of the United States with large immigrant populations. Human T-lymphotropic virus 1 infection is asymptomatic in most patients and has been associated with ATLL as well as tropical spastic paraparesis. Because there is considerable histologic overlap with other cutaneous T-cell lymphomas, high suspicion and clinical features must be present to make the diagnosis of ATLL.

Cutis. 2018;102:E4-E7.

Adult T-cell leukemia/lymphoma (ATLL) is an uncommon neoplasm of mature T lymphocytes associated with infection by human T-lymphotropic virus 1 (HTLV-1),¹⁻³ which is increasing in incidence in areas of the United States with large immigrant populations.⁴ Human T-lymphotropic virus 1 infection is asymptomatic in most patients and has been associated with ATLL as well as tropical spastic paraparesis.⁵

We present a case of rapid-onset ATLL in an 82-year-old Japanese man who had immigrated to the United States.

Case Report

An 82-year-old Japanese man who had immigrated to the United States presented with papules and nodules on the neck, trunk, and arms of 4 weeks' duration. Minimal pruritus was associated with the lesions, which were otherwise asymptomatic. The patient reported that he was generally healthy, and a review of systems was negative.

Physical examination revealed numerous erythematous and violaceous papules and nodules on the right side of the neck (Figure 1A), chest, back, abdomen, groin, left arm (Figure 1B), and medial thighs. Bilateral axillary and inguinal lymphadenopathy also was noted.

A biopsy from the abdomen revealed a dense, atypical, pandermal lymphoid infiltrate comprised of medium-sized lymphocytes with oval nuclei, fine chromatin, and pale cytoplasm (Figure 2). Mitotic figures and apoptotic cells also were observed. Immunostaining was strongly and diffusely positive for CD4 (Figure 3A), B-cell lymphoma 2 (Bcl-2)(Figure 3B), CD3, and programmed death 1, and was negative for CD8, CD10, CD20, CD30, and myeloperoxidase.

A bone marrow biopsy revealed an atypical T-cell population on flow cytometry. Western blot analysis for HTLV-1 antibodies was positive. Complete blood cell count and complete metabolic panel were within reference range.

Clinical and histopathologic findings fit the diagnosis of ATLL. The patient was referred to hematology/oncology, but the rapid progression of lesions continued, and the patient died within 4 months of initial presentation.

Dr. James is from St. Joseph Mercy Hospital, Ann Arbor, Michigan. Dr. Fivenson is from Fivenson Dermatology, Ann Arbor. Dr. Cotton is from Integrated Health Associates, Ann Arbor.

The authors report no conflict of interest.

Correspondence: Travis James, DO, MHA, 5333 McAuley Dr, Ste 5003, Ypsilanti, MI 48197 (travissjames@gmail.com).

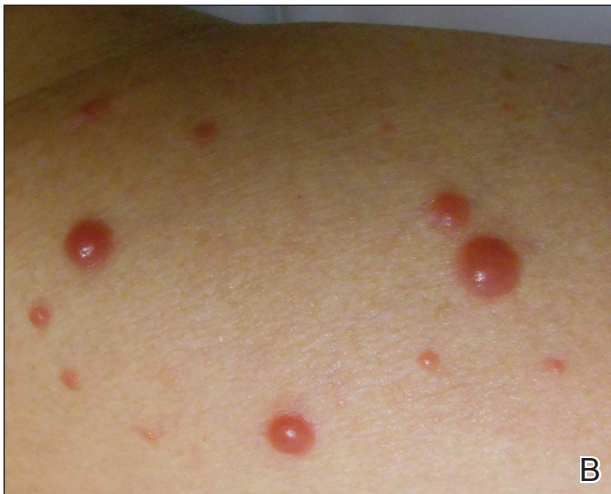
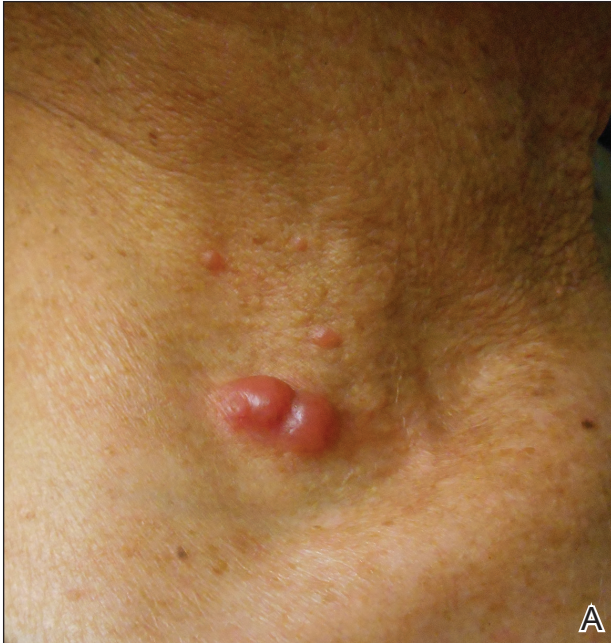
FIGURE 1. Numerous erythematous and violaceous papules and nodules on the right side of the neck (A) and left arm (B) in a patient with adult T-cell leukemia/lymphoma.

Comment

Etiology—First described in 1977, ATLL is an uncommon neoplasm of mature T cells.⁶ The etiology is associated with infection by the retrovirus HTLV-1, which is endemic in Southern Japan, the Caribbean, Central and West Africa, and Central and South America, with increasing incidence in areas of the United States with large immigrant populations.⁷ The incidence of ATLL among all registered lymphoma cases from 2003 to 2008 in Japan was 8.3% compared to 0.2% in the United States.⁷

Transmission of HTLV-1—Human T-lymphotropic virus 1 is a retrovirus most commonly found in CD4⁺ T cells and can be transmitted through breast milk, sexual

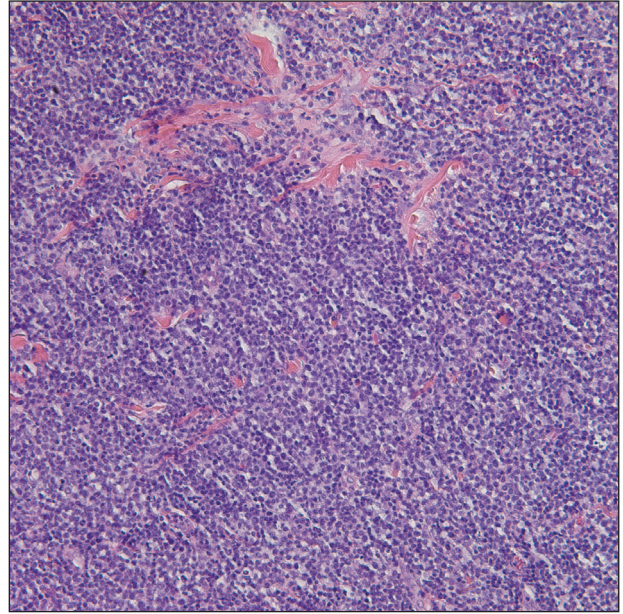


FIGURE 2. Histopathology revealed a dense, atypical, pandermal lymphoid infiltrate comprised of medium-sized lymphocytes with oval nuclei, fine chromatin, and pale cytoplasm (H&E, original magnification $\times 20$).

intercourse, and blood exposure (eg, blood transfusion), with breastfeeding and blood exposure being the most common.⁸⁻¹⁰ Human T-lymphotropic virus 1 has been described as the causative agent for 3 entities: (1) ATLL, (2) a nervous system degenerative disorder known as HTLV-1-associated myelopathy or tropical spastic paraparesis, and (3) HTLV-1 uveitis.^{5,11} It is thought that 10 to 20 million individuals worldwide are infected with HTLV-1.¹²

The evolution from infection with HTLV-1 to ATLL is thought to involve multiple steps.^{13,14} Those who contract the virus later in life rarely, if ever, develop ATLL, suggesting that this progression requires considerable time to evolve to carcinogenesis. More than 90% of those infected with HTLV-1 remain asymptomatic, while only 2% to 3% of women and 6% to 7% of men develop ATLL with a median incubation period greater than 15 to 20 years.⁷

Subtypes—Adult T-cell leukemia/lymphoma has been divided into 4 clinical subtypes based on clinical presentation and prognosis.¹⁵ The acute type is more aggressive and has a poorer prognosis, while the chronic and smoldering types have a more indolent course. The smoldering variant largely has only cutaneous involvement with less than 1% of the peripheral leukocytes being atypical lymphocytes.¹⁶ A cutaneous subtype in which few to no leukemic cells are present also has been described and may overlap with the smoldering variant. The cutaneous variant has been further classified into

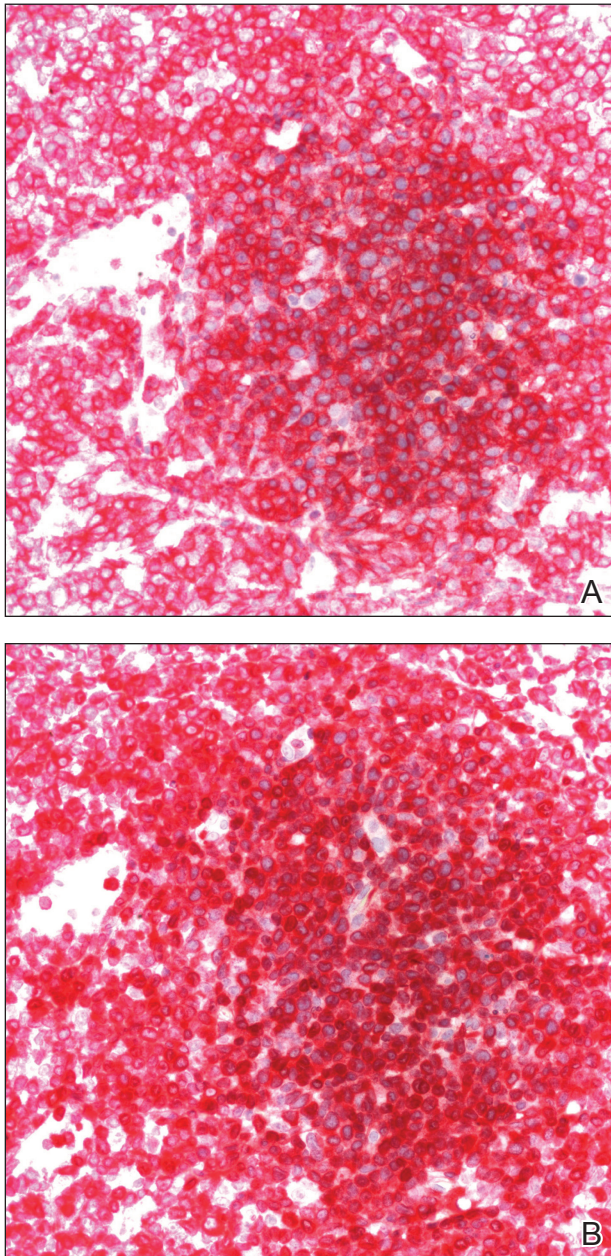


FIGURE 3. Immunostaining was strongly and diffusely positive for CD4 (A)(original magnification $\times 40$) and B-cell lymphoma 2 (Bcl-2)(B) (original magnification $\times 40$).

2 subtypes, tumoral and erythematopapular, with the tumoral subtype carrying a worse prognosis.^{17,18} Clinically, 39% to 57% of ATLL cases have skin involvement, with nearly one-third reporting skin manifestations as the first symptom.^{19,20} The cutaneous manifestations vary greatly and may include papules, plaques, nodules, tumors, erythematous patches, or erythroderma.^{4,21} In addition to skin manifestations, most patients with acute ATLL demonstrate leukemia, lymphadenopathy, organomegaly, and hypercalcemia.²²

Histopathology—Histologically, both the smoldering and chronic forms of tumoral or erythematopapular ATLL demonstrate a cutaneous, dermal, or subcutaneous infiltrate of small- to medium-sized CD4⁺ T cells with histiocytes and admixed granulomas.⁴ Epidermotropism and Pautrier microabscesses often are limited or absent but can be seen. The neoplastic T cells involved in ATLL commonly express CD3, CD4, CD25, CD30, and programmed death 1, and T-cell clonality frequently is present.^{11,22} Even with staining, diagnosis of ATLL is difficult, as it requires positive testing for HTLV-1 antibody as well as monoclonal integration of HTLV-1 proviral DNA into tumor cells.¹¹ Clinical information is vital in coming to this diagnosis, as there is such great histopathologic overlap with other cutaneous T-cell lymphomas.²³

Differential Diagnosis—The differential diagnosis includes other small- or medium-sized T-cell lymphomas. The chronic and smoldering types can be difficult to distinguish from mycosis fungoides. Primary cutaneous CD4⁺ small- or medium-sized pleomorphic T-cell lymphoma also must be considered, though it often is confined to the skin and can be differentiated from ATLL, as systemic involvement is commonly present in the latter.

Treatment—Treatment decisions should be made based on the subclassification and prognostic factors at the time of diagnosis. High doses of interferon alfa and zidovudine may show some benefit, but many cases require multiagent chemotherapy.²² The only possible curative treatment is allogeneic stem cell transplant. Mogamulizumab, an antichemokine receptor 4 monoclonal antibody, has demonstrated some ATLL antitumor activity.²⁴

REFERENCES

1. Uchiyama T, Yodoi J, Sagawa K, et al. Adult T-cell leukemia: clinical and hematologic features of 16 cases. *Blood*. 1977;50:481-492.
2. Poiesz BJ, Ruscetti FW, Gazdar AF, et al. Detection and isolation of type C retro-virus particles from fresh and cultured lymphocytes of a patient with cutaneous T-cell lymphoma. *Proc Natl Acad Sci U S A*. 1980;77:7415-7419.
3. Hinuma Y, Gotoh Y, Sugamura K, et al. A retrovirus associated with human adult T-cell leukemia: in vitro activation. *Gan*. 1982;73:341-344.
4. Marchetti MA, Pulitzer MP, Myskowski PL, et al. Cutaneous manifestations of human T-cell lymphotropic virus type-1-associated adult T-cell leukemia/lymphoma: a single-center, retrospective study. *J Am Acad Dermatol*. 2015;72:293-301.
5. Gessain A, Barin F, Vernant JC, et al. Antibodies to human T-lymphotropic virus type-I in patients with tropical spastic paraparesis. *Lancet*. 1985;2:407-410.
6. Takatsuki K, Uchiyama T, Sagawa K, et al. Adult T cell leukemia in Japan. In: Seno S, Takasu F, Irino S, eds. *Topics in Hematology*. Amsterdam, Netherlands: Excerpta Medica; 1977:73-77.
7. Yoshida N, Chihara D. Incidence of adult T-cell leukemia/lymphoma in nonendemic areas. *Curr Treat Options Oncol*. 2015;16:7.
8. Tajima K, Tominaga S, Suchi T, et al. Epidemiological analysis of the distribution of antibody to adult T-cell leukemia-virus-associated antigen: possible horizontal transmission of adult T-cell leukemia virus. *Gan*. 1982;73:893-901.
9. Kajiyama W, Kashiwagi S, Ikematsu H, et al. Intrafamilial transmission of adult T cell leukemia virus. *J Infect Dis*. 1986;154:851-857.
10. Ichimaru M, Ikeda S, Kinoshita K, et al. Mother-to-child transmission of HTLV-1. *Cancer Detect Prev*. 1991;15:177-181.

11. Lyra-da-Silva JO, de Mello Gonzaga YB, de Melo Espíndola O, et al. Adult t-cell leukemia/lymphoma: a case report of primary cutaneous tumoral type. *Dermatol Pract Concept*. 2012;2:202a03.
12. Edlich RF, Arnette JA, Williams FM. Global epidemic of human T-cell lymphotropic virus type-I (HTLV-I). *J Emerg Med*. 2000;18:109-119.
13. Magalhaes M, Oliveira PD, Bittencourt AL, et al. Microsatellite alterations are also present in the less aggressive types of adult T-cell leukemia-lymphoma. *PLoS Negl Trop Dis*. 2015;9:e0003403.
14. Okamoto T, Ohno Y, Tsugane S, et al. Multi-step carcinogenesis model for adult T-cell leukemia. *Jpn J Cancer Res*. 1989;80:191-195.
15. Shimoyama M. Diagnostic criteria and classification of clinical subtypes of adult T-cell leukaemia-lymphoma. *Br J Haematol*. 1991;79:428-437.
16. Takahashi K, Tanaka T, Fujita M, et al. Cutaneous-type adult T-cell leukemia lymphoma. a unique clinical feature with monoclonal T-cell proliferation detected by Southern blot analysis *Arch Dermatol*. 1988;124:399-404.
17. Amano M, Kurokawa M, Ogata K, et al. New entity, definition and diagnostic criteria of cutaneous adult T-cell leukemia/lymphoma: human T-lymphotropic virus type 1 proviral DNA load can distinguish between cutaneous and smoldering types. *J Dermatol*. 2008;35:270-275.
18. Johno M, Ohishi M, Kojo Y, et al. Cutaneous manifestations of adult T-cell leukemia lymphoma. *Gann Monogr Cancer Res*. 1992;39:33-42.
19. Shimoyama M. Diagnostic criteria and classification of clinical subtypes of adult T-cell leukemia-lymphoma: a report from the Lymphoma Study Group (1984-87). *Br J Haematol*. 1991;79:428-437.
20. Levine PH, Manns A, Jaffe ES, et al. The effect of ethnic differences on the pattern of HTLV-I-associated T-cell leukemia/lymphoma (HATL) in the United States. *Int J Cancer*. 1994;56:177-181.
21. Pezeshkpoor F, Yazdanpanah MJ, Shirdel A. Specific cutaneous manifestations in adult T-cell leukemia/lymphoma. *Int J Dermatol*. 2008;47:359-362.
22. Tsukasaki K, Hermine O, Bazarbachi A, et al. Definition, prognostic factors, treatment, and response criteria of adult T-cell leukemia-lymphoma: a proposal from an international consensus meeting. *J Clin Oncol*. 2009;27:453-459.
23. Vose J, Armitage J, Weisenburger D; International T-Cell Lymphoma Project. International peripheral T-cell and natural killer/T-cell lymphoma study: pathology findings and clinical outcomes. *J Clin Oncol*. 2008;26:4124-4130.
24. Ishida T, Joh T, Uike N, et al. Defucosylated anti-CCR4 monoclonal antibody (KW-0761) for relapsed adult T-cell leukemia-lymphoma: a multicenter phase II study. *J Clin Oncol*. 2012;30:837-842.