

# Foreign Body Insertions: A Review

Alan Lucerna, DO

Treating patients who present with foreign body insertions requires a nonjudgmental and open-minded approach.

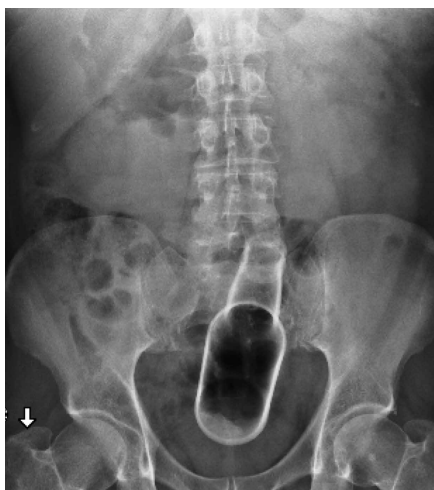Anorectal and urethral foreign body insertions (polyembolokoilamania) are not infrequent presentations to the ED. The motivations behind these insertions vary, ranging from autoeroticism to reckless behavior. These insertions can lead to major complications and even death. Though ED staff members are used to the unpredictability of human behavior, foreign body insertions bring a mixture of responses from the staff, ranging from awe and incredulousness to anger and frustration. A knowledge and comfort in managing these cases includes a nonjudgmental triage assessment, collective professionalism, and self-awareness of the staff's reaction.

## Case 1

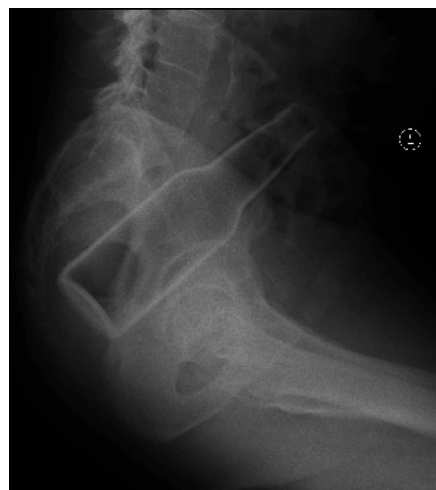A 58-year-old man presented to the ED for evaluation of a foreign body in his rectum. He admitted to placing a beer bottle in his rectum, but was unable to remove it at home. The staff reported that the patient was previously seen in the ED for removal of a vibrator from his rectum.

Radiographic evaluation in the form of an acute abdominal

series was obtained and confirmed a beer bottle in the rectum (**Figures 1 and 2**). This study was performed prior to the rectal examination to evaluate the orientation and integrity of the item, to prevent accidental injury from sharp objects. On examination, there was palpable glass in the rectum consistent with the rounded base of a bottle. The glass appeared intact and no gross bleeding was noted. Given the orientation of the bottle on the X-ray image, a surgical consultation was obtained and the patient



**Figure 1.** Abdominal radiograph showing a foreign body consistent with a beer bottle in the pelvic region.

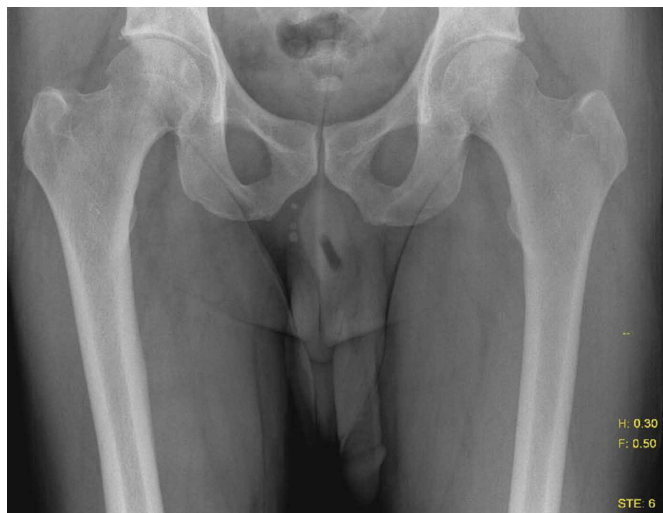

**Figure 2.** Abdominal radiograph lateral view showing a foreign body consistent with a beer bottle in the rectum.

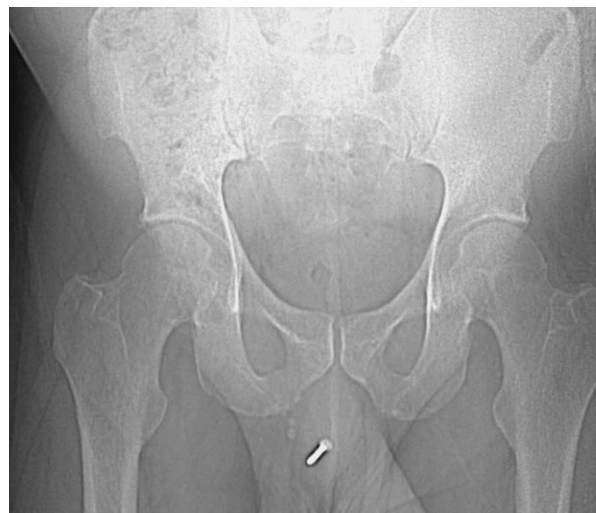**Dr Lucerna** is the program director, department of combined emergency medicine/internal medicine, Rowan University SOM/Kennedy University Hospital, Stratford, New Jersey.

**Author's Disclosure Statement:** The author reports no actual or potential conflict of interest in relation to this article.

DOI: 10.12788/emed.2017.0040



**Figure 3.** Pelvic radiograph showing a 3.5-cm long radiolucent structure projecting over the midline penis. A pen cap was eventually retrieved.



**Figure 4.** Abdominal radiograph showing a radiopaque foreign body consistent with a screw in the penile urethra.

was taken to the operating room (OR). The foreign body was successfully removed with manual extraction under general anesthesia. The patient did not experience any complications. He was offered psychiatric counseling in the ED, but he declined. He was discharged home with a referral to a psychiatrist for counseling.

### Case 2

A 55-year-old man presented to the ED after he inserted a pen cap into his urethra to aid in obtaining an erection. A pelvic X-ray was obtained and showed a radiolucent structure in the penis (**Figure 3**). The patient had been seen in several different hospital EDs more than 20 times with similar presentations of penile foreign body insertion. The various items inserted included a dry wall screw (**Figures 4 and 5**) and ballpoint pen (**Figure 6**). The patient suffered from erectile dysfunction and had been offered multiple treatment options, ranging from medications to penile implant, but he refused these treatments.

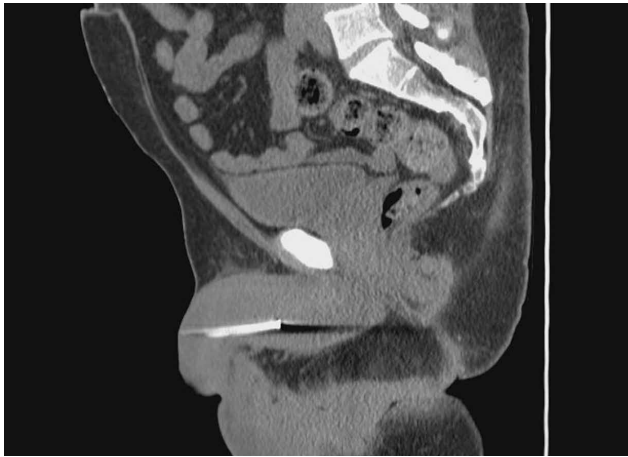The patient was admitted to the hospital and taken to the OR by the consulting urologist. Using a rigid cystoscope and flexible graspers, the pen cap was removed from the proximal urethra under monitored an-

esthesia control. The procedure went without any complications.

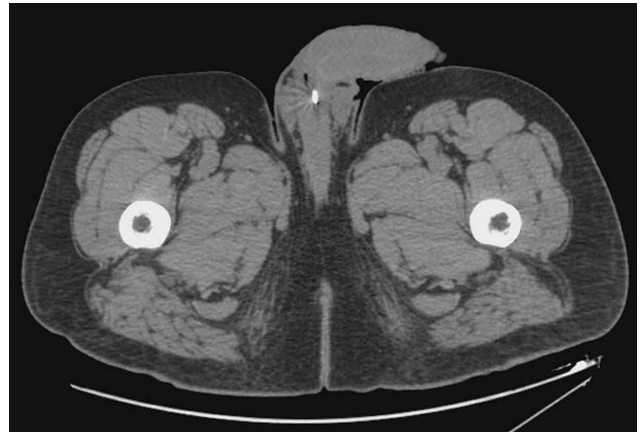
A psychiatrist was consulted, and during the encounter, the patient admitted that his behavior was pathological. He revealed that he was a victim of child abuse and reported he had been having mixed emotions of anxiety, guilt, and embarrassment because of his behavior. He consented to inpatient psychiatric treatment and was subsequently transferred to a psychiatric facility.

### Discussion

Foreign body insertions are seen in patients with a wide variety of backgrounds, ages, and lifestyles. Approximately 80,000 cases of foreign body ingestion are seen annually in children under age 20 years. Young males have a higher predilection of swallowing foreign bodies when compared to young females,<sup>1</sup> and rectal foreign body insertions are seen more commonly in males than in females.<sup>2</sup> In this age group, intentional foreign body insertion may be an initial manifestation of psychiatric illness. It may also reflect risk-taking or attention-seeking behavior, or poor judgment—especially when combined with alcohol or drugs. Many of those who are evaluated for foreign object insertion have a history of



**Figure 5.** Computed tomography scan of the abdomen and pelvis sagittal view showing a 4.9-cm x 4.5-mm radiopaque foreign body in the penile urethra that was eventually found to be a screw.



**Figure 6.** Computed tomography scan of the abdomen and pelvis showing a lucent tubular-shaped structure that is folded onto itself within the penile urethra. At one end of this structure, there is a metallic tip. A ball point bent at a 45° angle was later recovered.

similar prior presentation.<sup>1</sup> In comparison, there is a much lower incidence for lower urinary tract foreign body insertions, and self-inflicted urethral foreign body insertions are considered rare, and much rarer in children.<sup>3-5</sup> Information on the actual prevalence of foreign object insertions in the general population or in specific psychiatric populations, however, is lacking.<sup>1</sup>

#### Rectal Insertions

The earliest published report of a rectal foreign body insertion was in 1919 by Smiley.<sup>6</sup> The typical age at presentation ranges from 20 to 90 years old, with a mean age of 44 years old.<sup>2</sup> Household objects such as bottles and glasses are the most commonly seen, but a long list of other items have also been reported in the literature, including toothbrushes, knives, deodorant bottles, food articles, sports equipment, cell phones, flashlights, wooden rods, broomsticks, sex toys, light bulbs, construction tools, nails, ornaments, aerosol canisters, cocaine packets, jewelry, batteries, guitar picks, and many other items.<sup>1,2,7</sup>

In nearly half of the reported cases, the reasons for rectal insertion was for sexual arousal/stimulation.<sup>1,7</sup> Other reasons include nonsuicidal injurious behavior (eg, borderline personality disorder); suicide

attempt; psychosis; depression; factitious disorder; malingering; cognitive disorders, including dementia and delirium; treatment of constipation and hemorrhoids; concealment; attention-seeking behavior; “accidental”; assault; and the consequences of drunken wagers.<sup>1,2</sup> Additionally, abuse should be considered, especially in patients with developmental delay and/or psychiatric illness.

Close to 20% of all traumatic rectal injuries are due to foreign body insertions. In most cases, foreign bodies fail to cause significant anorectal injuries. Complications, however, can result from the process of insertion, removal, or from the contents introduced into the orifice.<sup>1</sup> Any rectal examination should be preceded by an anatomical survey utilizing radiographic modalities to evaluate the integrity and orientation of the object in question. Any sharp object can injure the examining physician if this is not done prior. All examinations should be chaperoned.<sup>2,7</sup> The most obvious and dangerous complication is perforation, and the patient’s care should proceed in the same manner as any other trauma patient. Additionally, resulting sepsis should be managed with the same standards as any other septic patient.<sup>7</sup>

**Treatment.** The method of object re-

The method of object removal is determined by the presence or absence of a surgical abdomen and the need for general anesthesia.

removal is determined by the presence or absence of a surgical abdomen and the need for general anesthesia. The location and shape of the object, however, may not equate with successful retrieval. Objects placed in the sigmoid colon are more than twice as likely to require surgical intervention compared to items placed distally.<sup>2</sup>

Once it is determined that the patient is clinically stable and does not have an acute abdomen, attempts in removing the rectal foreign object can be done in the ED or, if anesthesia is needed, in the OR. Any attempts at transanal removal require optimal patient relaxation, which can be achieved via procedural sedation. The patient should be placed in a lithotomy or left lateral decubitus position to allow palpation of the object in the lower gastrointestinal tract. From here, several methods of removal can be employed. Blunt objects can be grasped and removed by a gloved hand or with a clamp. A Foley catheter can also be passed alongside the object and the balloon inflated above the foreign body to aid in extraction as the Foley is pulled out slowly. Sengstaken-Blakemore tubes, obstetric forceps, and vacuum extractors have also been utilized.<sup>7</sup>

While bedside extraction is advocated by many authors, Cawich et al<sup>8</sup> recently reported that transanal extraction in the ED failed in 89% of cases. Additionally, these researchers reported that in 63% of the failed extractions, the objects were inadvertently pushed higher into the rectosigmoid region, and therefore recommended early mobilization of the OR team so that exploration under anesthesia can be performed under optimal conditions.<sup>8</sup>

Once the foreign body is successfully removed, follow-up imaging or postextraction endoscopy is warranted. Close observation in the hospital is recommended to facilitate serial abdominal examination.<sup>7</sup>

#### Urethral Insertions

Sexual exploration, efforts at contraception, transport of illicit drugs, assault or sexual violence, and accidental insertion

have all been described as reasons for genitourinary (GU) insertion.<sup>1</sup> The motives, however, mirror those who insert foreign bodies rectally.

Most presentations are due to pain or inability to void. Aggressive treatment should be undertaken because even when the penis appears dark or necrotic, salvage rates have been high. Complications include urinary tract infections, hematuria, urinary retention, urethral tears, abscess, ascending GU infections, and diverticula and fistula formations.<sup>1,3</sup> In women, vaginal insertions can lead to pelvic pain and septic shock.<sup>1</sup> Foreign bodies can also lead to a condition first described in the ancient literature as strangury—the process of slow and painful discharge of urine due to a significant inflammatory component or stricture. The term strangury has been replaced with the more general term bladder spasms.<sup>9</sup>

**Treatment.** Removal of urethral foreign bodies typically is done in conjunction with a urologist. A cystoscopic procedure is usually successful in removing the foreign body and is an effective method to minimize urethral and bladder injuries. However, more invasive surgical options, including perineal urethrotomy, suprapubic cystostomy, cystolithotomy, and external urethrotomy, have been used in more complicated cases or when the foreign body prevents urethral access of an endoscopic instrument.<sup>10</sup>

#### Patient and Staff Reactions

When patients realize they are unable to remove the inserted object, some present immediately to the ED for evaluation. Interestingly, others may wait up to 2 weeks after insertion before seeking help.<sup>2</sup> Patients report feelings of being ashamed and report a feeling of being despised, frowned upon, and being talked about during the course of their ED evaluation. As a consequence, these patients may not readily come to the ED or if they do come, may not be open to conversation and hide the

true reason of why they came in the first place.<sup>1,4</sup> The amplified paranoia and perceived prejudice may delay diagnosis and lifesaving measures, or worse, lead patients to leave prior to a medical screening examination. Therefore, creating a non-judgmental environment is essential, even when the presenting story appears to be fabricated.<sup>2</sup>

Once the patient's foreign body is removed, and complications are excluded or properly managed, the goal is to understand the motivation behind the insertion, mitigate the consequences of the behavior, and prevent future recurrence. A psychiatric evaluation should be obtained in the ED, or if the patient is admitted, during hospitalization. Psychiatric behavior leading to insertions can be unmasked, treated, and harm-reduction strategies can be taught and instituted.<sup>1,3</sup>

Experienced ED staff members are used to the unpredictability of human behavior. However, patients who present with foreign body insertions can elicit a mixture of responses, ranging from awe and incredulosity to anger and frustration. It is not unusual for staff members to not understand or recognize their own reactions. The unique nature of the presentation, along with the astonishing radiographic images, can lead to a breach of privacy and dissemination of the digital photographs by cell phones and into social media sites.<sup>1</sup> Staff members should be encouraged to foster open-mindedness and indifference. Ensuring privacy, professionalism, and empathy can go a long way to helping these patients. Moreover, ED staff members should be educated about countertransference reactions,<sup>1</sup> as these actions are necessary to ensure the singular purpose of optimum patient-staff relationship.

## Conclusion

Patients with foreign body insertions challenge the ED staff, as the presenting complaint not only tests the collective technical know-how of the staff, but also their emotional competencies. A nonjudgmental and open-minded approach is crucial, with the tone set during triage. Coordination with surgical specialties should be done early to ensure safe removal and to identify and manage complications. Psychiatric evaluation should be strongly considered prior to disposition in an attempt to prevent future recurrences.

## References

1. Unruh BT, Nejad SH, Stern TW, Stern TA. Insertion of foreign bodies (polyembolokoilomania): underpinnings and management strategies. *Prim Care Companion CNS Disord.* 2012;14(1). doi:10.4088/PCC.11f01192.
2. Cologne KG, Ault GT. Rectal foreign bodies: what is the current standard? *Clin Colon Rectal Surg.* 2012;25(4):214-218. doi:10.1055/s-0032-1329392.
3. Naidu K, Chung A, Mulcahy M. An unusual urethral foreign body. *Int J Surg Case Rep.* 2013;4(11):1052-1054. doi:10.1016/j.ijscr.2013.07.017.
4. Rahman NU, Elliott SP, McAninch JW. Self-inflicted male urethral foreign body insertion: endoscopic management and complications. *BJU Int.* 2004;94(7):1051-1053. 10.1111/j.1464-410X.2004.05103.x.
5. SaiSwaroop Y, Darakh P, Amlani D. Self insertion of urethral foreign body in a child: a rare case report. *Int J Curr Med Appl Sci.* 2015;9(1):22-24.
6. Smiley O. A glass tumbler in the rectum. *JAMA.* 1919;72:1285.
7. Coskun A, Erkan N, Yakan S, Yildirim M, Cengiz F. Management of rectal foreign bodies. *World J Emerg Surg.* 2013;8(1):11. doi:10.1186/1749-7922-8-11.
8. Cawich SO, Thomas DA, Mohammed F, Bobb NJ, Williams D, Naraynsingh V. A management algorithm for retained rectal foreign bodies. *Am J Mens Health.* 2017;11(3):684-692. doi:10.1177/1557988316680929.
9. Wright B, Husbands E. Strangury: the case of a symptom with ancient origins. *BMJ Support Palliat Care.* 2011;1(1):49-50. doi:10.1136/bmjsp-care-2011-000030.
10. Moon SJ, Kim DH, Chung JH, et al. Unusual foreign bodies in the urinary bladder and urethra due to autoerotism. *Int Neurourol J.* 2010;14(3):186-189. doi:10.5213/inj.2010.14.3.186.