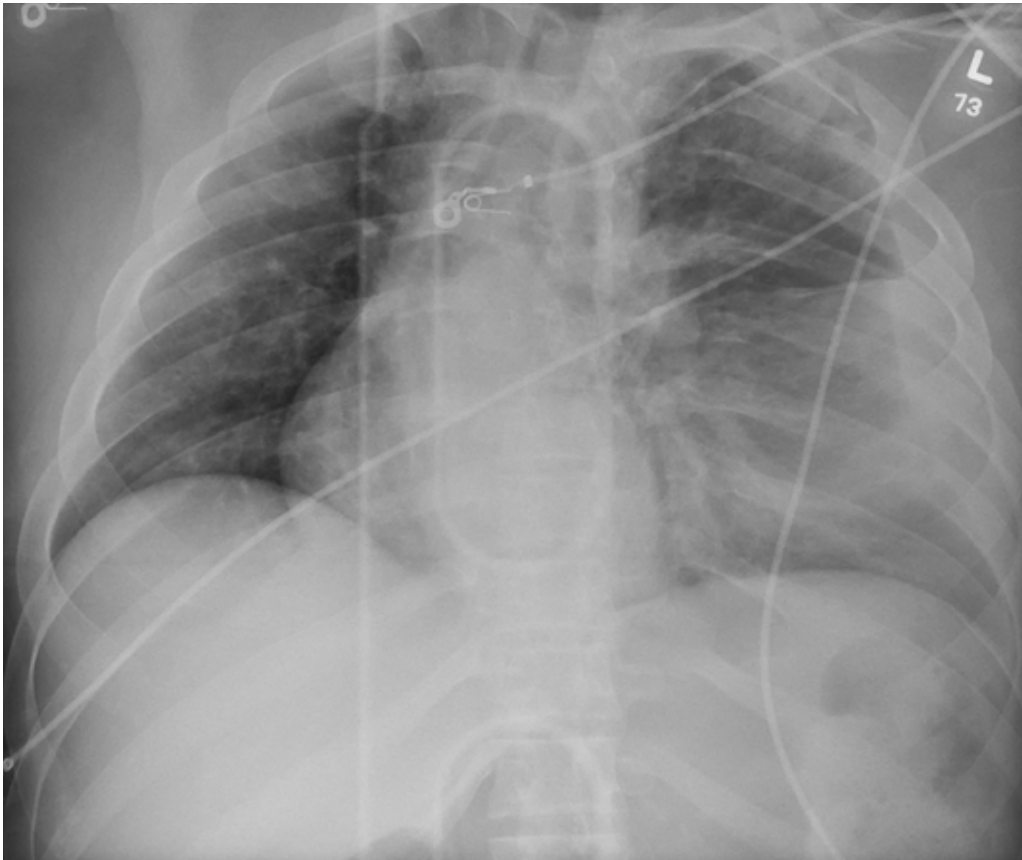

# Thrown Off Track



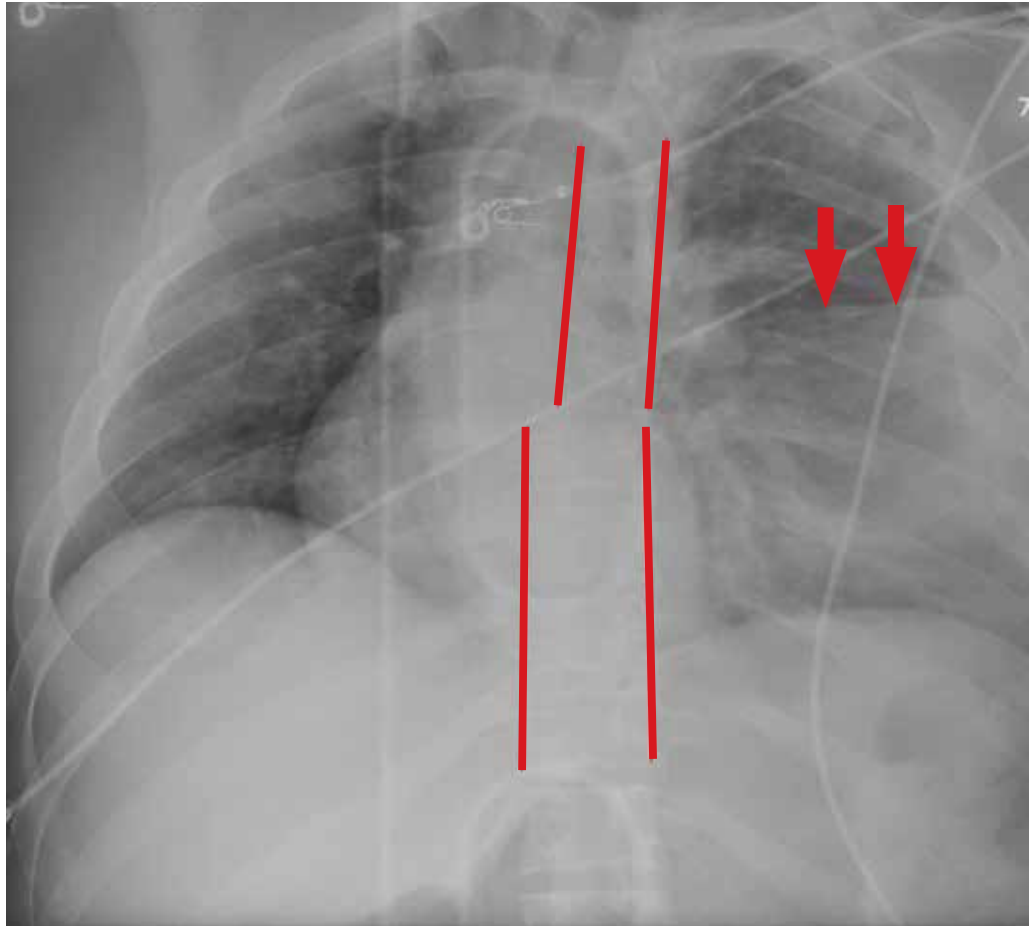
**Nandan R. Hichkad, PA-C, MMSc**, practices at the Georgia Neurosurgical Institute in Macon and is a clinical instructor at the Mercer University School of Medicine, Macon.

**A** 20-year-old man is riding a four-wheel all-terrain vehicle at a high rate of speed when he loses control and is thrown off. He is not wearing a helmet. When paramedics respond, the patient is unable to feel or move his legs. He is transported to your facility by emergency medical services.

As you begin your primary survey, you note a young male who is anxious but awake and able to converse. He is receiving 100%

oxygen via a non-rebreather mask. His heart rate is 130 beats/min and his blood pressure, 80/40 mm Hg. Breath sounds are somewhat decreased on the left side. The patient can move both arms, and his strength is normal. However, he is insensate from his mid-chest down and is unable to move his legs at all.

Portable radiographs are obtained, including a chest radiograph (shown). What is your impression?



**ANSWER**

The radiograph shows rib fractures on the left side (arrows); on the same side, there is a moderate-sized pleural effusion—presumably a hemothorax from the trauma.

A closer look at the mid-thoracic spine

reveals some irregularity and possible deformity—note the slight offset. This finding is strongly suspicious for a fracture.

A subsequent CT revealed a thoracic burst fracture with retropulsion into the spinal canal. **CR**