

Acrodermatitis Enteropathica From Zinc-Deficient Total Parenteral Nutrition

Danielle Baruch, MD; Lina Naga, MD; Marcia Driscoll, MD, PharmD; Grace Kao, MD

PRACTICE POINTS

- Acrodermatitis enteropathica (AE) may be acquired or due to a rare autosomal-recessive disorder of zinc absorption.
- Hereditary AE typically becomes symptomatic during infancy, while acquired AE may develop during hypozincemia in patients of any age.
- Both acquired and hereditary AE improve with zinc supplementation.

Acrodermatitis enteropathica (AE) is a rare autosomal-recessive disorder of zinc malabsorption, characterized by acral and periorificial dermatitis, alopecia, and diarrhea. Acquired AE is the result of decreased zinc intake, excessive zinc loss, or other malabsorptive processes. We present a case of a 54-year-old woman who developed characteristic skin lesions of acquired AE after zinc supplementation was removed from her total parenteral nutrition (TPN) solution. She was found to have hypozincemia and eventually exhibited prompt resolution of skin lesions after zinc was added to TPN. This case provides a unique opportunity to illustrate the direct correlation between decreased zinc intake and development of acquired AE.

Cutis. 2018;101:450-453.

Case Report

A 54-year-old woman presented with a pruritic and slightly painful skin eruption that began perinasally and progressed over 1 week to involve the labial commissures, finger webs, dorsal surfaces of the feet, heels, and bilateral gluteal folds. In addition, the eruption involved the left thigh at the donor site of a prior skin graft. She received no relief after an intramuscular steroid injection and hydrocortisone cream 1% prescribed by a primary

care physician who diagnosed the rash as poison ivy contact dermatitis despite no exposure to plants. Review of systems was negative and she denied any new medication use. Her medical history was notable for extensive mesenteric injury secondary to a motor vehicle accident. She subsequently had multiple enterocutaneous fistulas that resulted in a complete small bowel enterectomy 10 months prior to presentation, which caused her to become dependent on total parenteral nutrition (TPN).

Physical examination revealed sharply demarcated, erythematous, scaly plaques perinasally, periorally, and on the bilateral gluteal folds (Figure 1). There were sharply demarcated, erythematous, scaly plaques on the

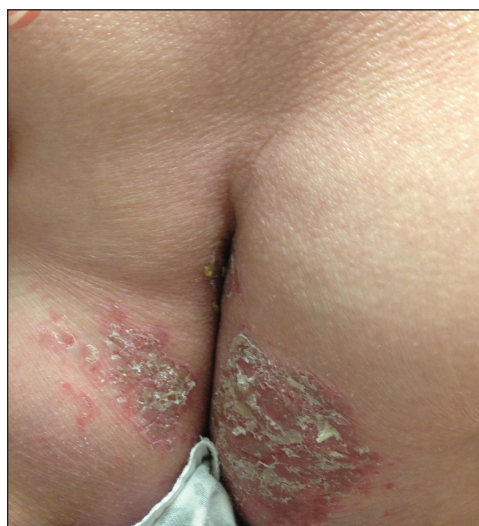

FIGURE 1. Sharply demarcated, erythematous, scaly plaques on the bilateral gluteal folds.

From the Department of Dermatology, University of Maryland School of Medicine, Baltimore.

The authors report no conflict of interest.

Correspondence: Lina Naga, MD, University of Maryland School of Medicine, 419 W Redwood St, Ste 240, Baltimore, MD 21201 (linanaga@gmail.com).

right and left finger webs, dorsal surface of the right foot, and left upper thigh. Hemorrhagic bullae were appreciated on the left finger webs. Large flaccid bullae were present on the bilateral heels and dorsum of the right foot (Figure 2).

Suspecting a diagnosis of acrodermatitis enteropathica (AE), laboratory testing included a serum zinc level, which was 42 $\mu\text{g/dL}$ (reference range, 70–130 $\mu\text{g/dL}$). The copper and selenium levels also were low with values of 71 $\mu\text{g/dL}$ (reference range, 80–155 $\mu\text{g/dL}$) and 31 $\mu\text{g/dL}$ (reference range, 79–326 $\mu\text{g/dL}$), respectively. No additional vitamin or mineral deficiencies were discovered. A complete blood cell count and comprehensive metabolic panel were performed and showed no abnormalities other than a mildly elevated sodium level of 147 mEq/L (reference range, 136–142 mEq/L).

A punch biopsy was performed. Histopathology revealed subcorneal neutrophils and neutrophilic crust, mild spongiosis, and a dense upper dermal mixed neutrophilic and lymphohistiocytic infiltrate. The specimen also exhibited mild intercellular edema and prominent capillaries (Figure 3).

After further investigation, the company providing the patient's TPN confirmed that zinc had been removed several weeks prior to the onset of symptoms due to a critical national shortage of trace element additives. Zinc was supplemented at 15 mg daily to the TPN solution. Three days later a skin examination revealed dramatic changes with notable improvement of the finger web plaques and complete resolution of the facial lesions. The plaques and bullae on the lower extremities also had resolved (Figure 4).

Comment

Background—Acrodermatitis enteropathica is a rare autosomal-recessive disorder of zinc metabolism characterized by skin lesions predominantly distributed in acral and periorificial sites as well as alopecia and diarrhea. Acrodermatitis enteropathica was first described by Brandt¹ in 1936 and later characterized by Danbolt and Closs² in 1942 as a unique and often fatal disease of unknown etiology. More than 30 years later, the link between zinc deficiency and AE was illustrated by Moynahan³ who demonstrated clinical improvement with zinc supplementation. It was not until 2002 that the molecular pathogenesis of hypozincemia in patients with inherited AE was described. Küry et al⁴ identified a mutation in the *SLC39A4* gene responsible for encoding the Zip4 protein, a zinc transporter found on enterocytes, particularly in the proximal small intestine.^{5,6} Classically, patients with inherited AE are children who present within days of birth or days to weeks after being weaned from breast milk to cow's milk. The zinc in bovine milk is less bioavailable than breast milk, though both have similar total zinc concentrations, which results in the decreased plasma zinc levels seen in children with inherited AE.^{5–8} Occasionally, children present before

weaning due to decreased maternal mammary zinc secretion (lactogenic AE).^{9,10}

Clinical Presentation—Similar clinical findings are seen in patients with noninherited forms of zinc deficiency known as acquired AE. Acquired zinc deficiency may be broadly categorized as being from inadequate intake, deficient absorption, excess demand, or overexcretion.⁸ Such disturbances of zinc balance are most frequently seen in patients with restrictive diets, anorexia nervosa, intestinal bypass procedures, Crohn disease, pancreatic insufficiency, alcoholism, human immunodeficiency virus, and extensive cutaneous burns. Premature infants, mothers who are breastfeeding, and those dependent on TPN are at risk for developing acquired zinc deficiency.^{7–9,11}

Differentiating Characteristics—Both acquired and inherited AE present as erythematous or pink eczematous scaly plaques with the variable presence of vesicular or bullous lesions involving periorificial, acral, and anogenital regions. Early manifestations of AE may include angular cheilitis and paronychia. Alopecia and diarrhea are characteristics of later disease. In fact, the

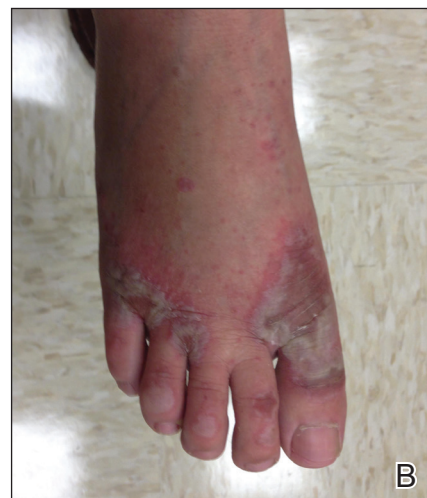
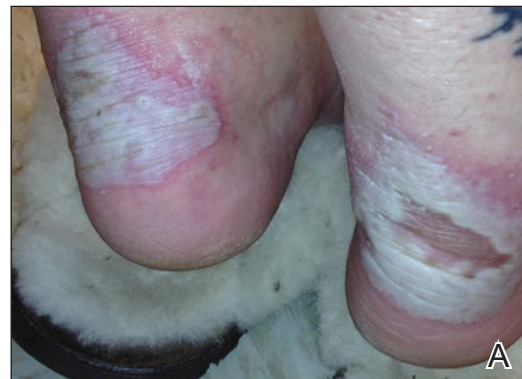
FIGURE 2. Large flaccid bullae on the bilateral heels (A) and dorsum of the right foot (B).

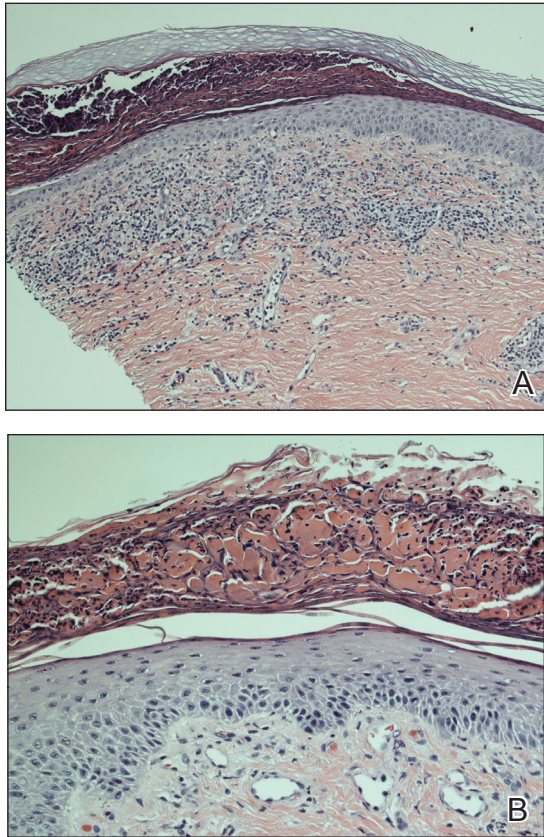


FIGURE 3. Punch biopsy specimen demonstrated subcorneal collection of neutrophils, mild spongiosis, and a dense upper dermal mixed neutrophilic and lymphohistiocytic infiltrate (A)(H&E, original magnification $\times 100$), as well as subcorneal serum, neutrophilic scale crust, mild intercellular edema, and prominent capillaries (B)(H&E, original magnification $\times 200$).

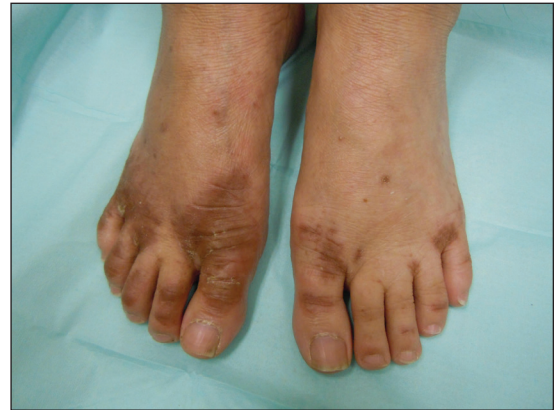

FIGURE 4. Bullae and hyperpigmented macules and patches with scale resolved on the dorsum of the feet.

Diagnosis—Evaluation includes measurement of plasma zinc levels. Zinc levels less than $50 \mu\text{g/dL}$ are suggestive but not diagnostic of AE.⁵ Although plasma zinc measurement is the most useful indicator of zinc status, its utility in assessing the true total body store of zinc is limited. Plasma zinc is tightly regulated and only represents 0.1% of body stores.^{5,6} Additionally, zinc levels may decrease in proinflammatory states.¹² Beyond zinc measurement, evaluation of alkaline phosphatase, a zinc-dependent enzyme, can provide useful diagnostic information.^{5,6}

Zinc and TPN—Patients on TPN are at a unique risk for developing zinc and other nutritional deficiencies. Because the daily recommended dietary allowance for zinc is low (8 mg daily for adult women and 11 mg daily for adult men)⁵ and the element is found in a wide variety of foods, maintaining adequate zinc levels is easily achieved in healthy individuals with normal diets. Kay et al¹³ described 4 patients on parenteral nutrition who developed hypozincemia and an AE-like syndrome within weeks of TPN induction. The authors described rapid and drastic clinical improvement after initiating zinc supplementation, accentuating the importance of including zinc as a component of TPN.^{13,14} Brazin et al¹⁵ also reported a case of an AE-like syndrome from zinc-deficient hyperalimentation in a patient receiving TPN for short bowel syndrome. Chun et al¹⁶ described another case of acquired AE in a patient on TPN for acute pancreatitis. Both cases demonstrated prompt improvement of skin lesions after treatment with zinc supplementation. Other nutrient deficiencies may reveal themselves through similar dermatologic manifestations. For example, cases of scaly dermatitis secondary to the development of essential fatty acid deficiency from TPN formulations lacking adequate quantities of linoleic acid have been reported. Similar to our case, the resolution of skin lesions was seen after TPN was supplemented with the deficient nutrient.¹⁷ These cases exemplify the importance in considering deficiency dermatoses in the TPN-dependent patient population.

complete triad of dermatitis, alopecia, and diarrhea is seen in only 20% of cases.⁷ Without treatment, patients may develop blepharitis, conjunctivitis, photophobia, irritability, anorexia, apathy, growth retardation, hypogonadism, hypogeusia, and mental slowing. Skin lesions frequently become secondarily infected with *Candida albicans* and/or bacteria.^{5,7,11}

Histopathology—Histopathologic examination of skin biopsy specimens from AE lesions demonstrates non-specific findings similar to other deficiency dermatoses, such as pellagra and glucagonoma-associated necrolytic migratory erythema. Histology typically reveals cytoplasmic pallor with vacuolization and ballooning degeneration of keratinocytes, followed by confluent keratinocyte necrosis within the stratum granulosum and stratum spinosum of the epidermis.⁵ Confluent parakeratosis with hypogranulosis variably associated with neutrophil crust also is seen. Scattered dyskeratotic keratinocytes may be found within all levels of the epidermis. In resolving or chronic AE lesions, psoriasiform hyperplasia is prevalent, though necrolysis may be minimal or absent.^{5,11}

Conclusion

In our case, the development of skin lesions directly coincided with a recent removal of zinc from the patient's TPN, which provided us with a unique opportunity to observe the causal relationship between decreased zinc intake and the development of clinical signs of acquired AE. This association was further elucidated by laboratory confirmation of low serum zinc levels and rapid improvement in all skin lesions after zinc supplementation was initiated.

REFERENCES

1. Brandt T. Dermatitis in children with disturbances of general condition and absorption of food. *Acta Derm Venereol.* 1936;17:513-537.
2. Danbolt N, Closs K. Acrodermatitis enteropathica. *Acta Derm Venereol.* 1942;23:127-169.
3. Moynahan E. Acrodermatitis enteropathica: a lethal inherited human zinc deficiency disorder. *Lancet.* 1974;2:299-400.
4. Küry S, Dréno B, Bézieau S, et al. Identification of SLC39A4, a gene involved in acrodermatitis enteropathica. *Nat Genet.* 2002; 31:238-240.
5. Maverakis E, Fung MA, Lynch PJ, et al. Acrodermatitis enteropathica and an overview of zinc metabolism. *J Am Acad Dermatol.* 2007;56:116-124.
6. Thrash B, Patel M, Shah KR, et al. Cutaneous manifestations of gastrointestinal disease: part II. *J Am Acad Dermatol.* 2013;68:211.e1-211.e33; quiz 244-246.
7. Perafán-Riveros C, França LF, Alves AC, et al. Acrodermatitis enteropathica: case report and review of the literature. *Pediatr Dermatol.* 2002;19:426-431.
8. Kumar P, Ranjan NR, Mondal AK. Zinc and skin: a brief summary. *Dermatol Online J.* 2012;18:1.
9. Saritha M, Gupta D, Chandrashekar L, et al. Acquired zinc deficiency in an adult female. *Indian J Dermatol.* 2012;57:492-494.
10. Neldner K, Hambidge K, Walravens P. Acrodermatitis enteropathica. *Int J Dermatol.* 1978;17:380-387.
11. Gehrig K, Dinulos J. Acrodermatitis due to nutritional deficiency. *Curr Opin Pediatr.* 2010;22:107-112.
12. Liuzzi JP, Lichten LA, Rivera S, et al. Interleukin-6 regulates the zinc transporter Zip14 in liver and contributes to hypozincemia of the acute-phase response. *Proct Natl Acad Sci U S A.* 2005;102:6843-6848.
13. Kay RG, Tasman-Jones C, Pybus J, et al. A syndrome of acute zinc deficiency during total parenteral nutrition in man. *Ann Surg.* 1976;183:331-340.
14. Jeejeebhoy K. Zinc: an essential trace element for parenteral nutrition. *Gastroenterology.* 2009;137(5 suppl):S7-S12.
15. Brazin SA, Johnson WT, Abramson LJ. The acrodermatitis enteropathica-like syndrome. *Arch Dermatol.* 1979;115:597-599.
16. Chun JH, Baek JH, Chung NG. Development of bullous acrodermatitis enteropathica during the course of chemotherapy for acute lymphocytic leukemia. *Ann Dermatol.* 2011;23(suppl 3):S326-S328.
17. Roongpisuthipong W, Phanachet P, Roongpisuthipong C, et al. Essential fatty acid deficiency while a patient receiving fat regimen total parenteral nutrition [published June 14, 2012]. *BMJ Case Rep.* doi:10.1136/bcr.07.2011.4475.