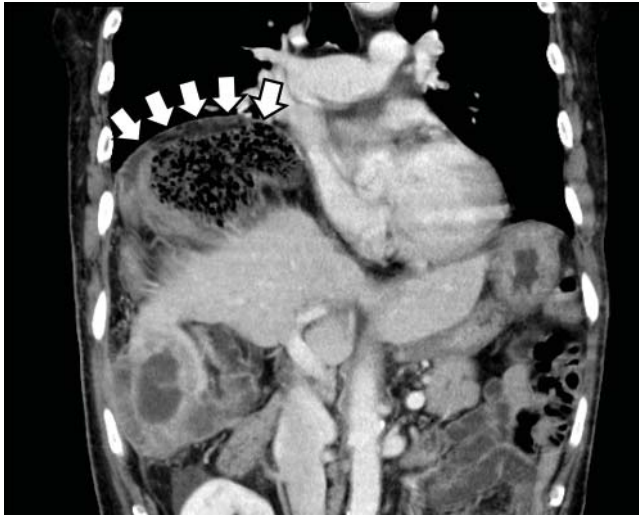


## Gas under the right diaphragm

FEBRUARY 2018

In the article “Gas under the right diaphragm” (Matsuura H, Hata H. *Cleve Clin J Med* 2018; 85[2]:98–100), **Figure 2** appeared upside down. It should have appeared as follows:



**Figure 2.** The Chilaiditi sign on computed tomography, with volvulus of the cecum between the diaphragm and liver and a closed-loop obstruction (arrows).

The correction has been made to the online version at [www.ccmj.org](http://www.ccmj.org).

## Physical examination in dyspnea

DECEMBER 2017

On page 949 of the article “Diagnostic value of the physical examination in patients with dyspnea” (Shellenberger RA, Balakrishnan B, Avula S, Ebel A, Shaik S. *Cleve Clin J Med* 2017; 84[12]:943–950), the terms “abdominojugular reflex” and “hepatojugular reflex” should have been “abdominojugular reflux” and “hepatojugular reflux.” This error also occurred in **Table 5** on that page. The correction has been made to the online version at [www.ccmj.org](http://www.ccmj.org).

 **Cleveland Clinic**  
Endocrinology and Metabolism Institute

# 23rd Annual Diabetes Day

*New Frontiers in Diabetes*

**Friday, May 11, 2018**

InterContinental Hotel and Bank  
of America Conference Center  
Cleveland, OH

A CME-certified educational symposium to provide up-to-date reviews of advances in management strategies for patients with diabetes

Key topic areas include the **pathobiology of diabetes complications, new oral agents, diabetes control, and current guideline recommendations.**

*Presented by the Cleveland Clinic  
Department of Endocrinology, Diabetes  
and Metabolism.*

Register Today!

[ccfcme.org/diabetesday](http://ccfcme.org/diabetesday)

