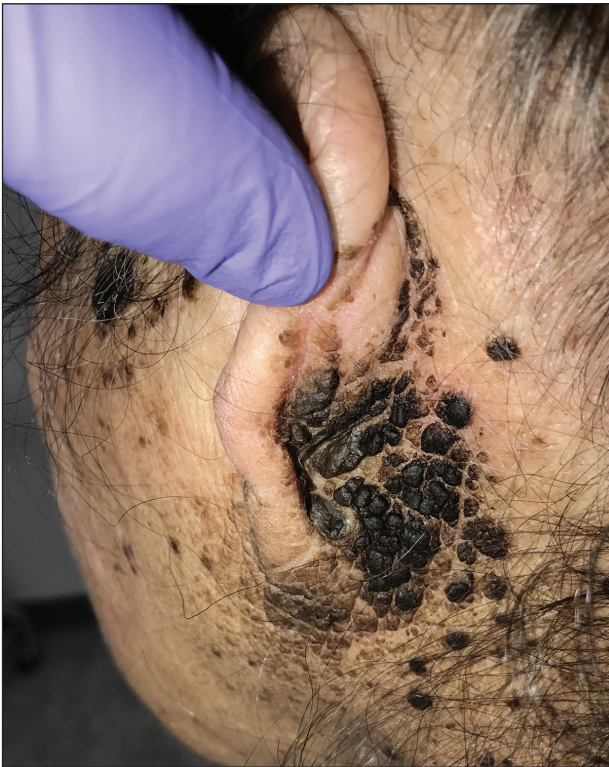

# Bilateral Brown Plaques Behind the Ears

Sarah Mattessich, BS; Pamela Aubert, MD; Adam Rees, MD



A 94-year-old woman was referred to the dermatology department for biopsy of pigmented tumors behind the ears of unknown duration. The growths were asymptomatic. Her medical history included the early stages of Alzheimer disease. On physical examination dark brown, smooth, coalescing papules and plaques were noted extending from the posterior neck to the conchal bowls and ear folds bilaterally. The nodules were removed by scrubbing with isopropyl alcohol 70%. A nodule was submitted for histopathologic review.

## WHAT'S THE DIAGNOSIS?

- a. acanthosis nigricans
- b. confluent and reticulated papillomatosis
- c. malignant melanoma
- d. seborrheic keratosis
- e. terra firma-forme dermatosis

PLEASE TURN TO **PAGE E2** FOR THE DIAGNOSIS

Ms. Mattessich is from the University of Connecticut School of Medicine, Farmington. Drs. Aubert and Rees are from the Department of Dermatology, Kaiser Permanente Panorama City Medical Center, California.

The authors report no conflict of interest.

Correspondence: Adam Rees, MD, Kaiser Permanente Panorama City Medical Center, 13652 Cantara St, Bldg 6, Area 192, Panorama City, CA (Adam.rees@kp.org).

## THE DIAGNOSIS: Terra Firma-Forme Dermatitis

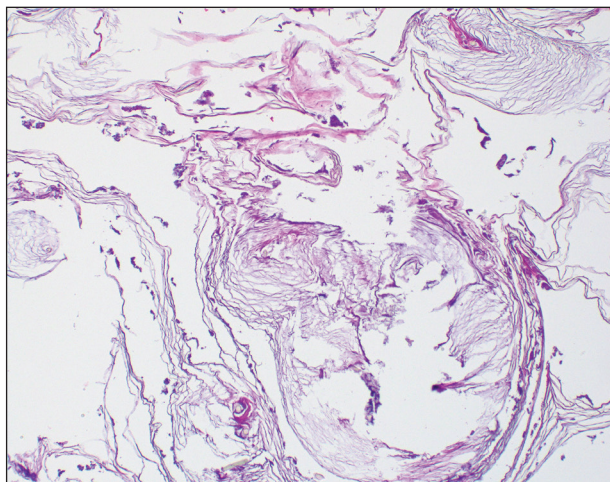
**T**erra firma-forme dermatosis (TFFD), also known as Duncan dirty dermatosis, is an idiopathic benign cutaneous condition that is easily misdiagnosed or mismanaged. In 1987, Duncan et al<sup>1</sup> first described the condition in children who had mothers that lamented over dirty skin spots that could not be washed off. The term *terra firma* translates in Latin to solid ground, which describes the characteristic dirtlike appearance of these lesions.

Terra firma-forme dermatosis most commonly affects children and young adults, though it can present in patients of any age without any known predisposing risk factors.<sup>1-4</sup> The lesions have a predilection for the face, neck, shoulders, trunk, and ankles. Terra firma-forme dermatosis has no association with bathing and hygiene habits, and most patients describe unsuccessful removal of the lesions, even after vigorous scrubbing with soaps and detergents at home. The lesions are asymptomatic, and many patients present to dermatology for cosmetic concerns.<sup>1-8</sup>

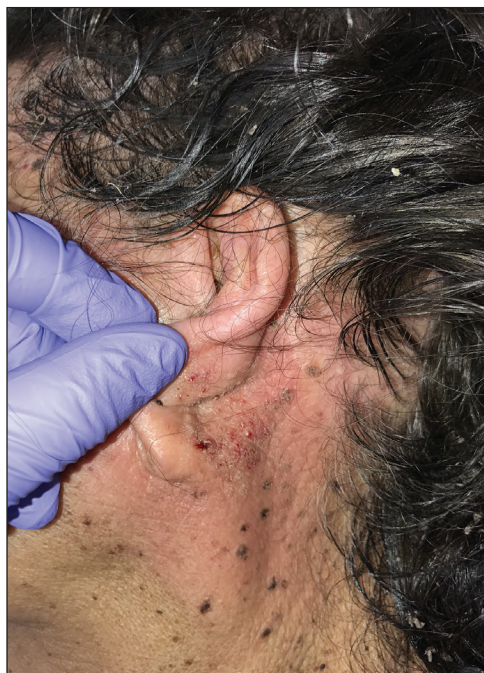The etiology of TFFD is not well understood and is considered a retention hyperkeratosis. Duncan et al<sup>1</sup> postulated that TFFD is the result of partial or improper maturation of keratinocytes leading to keratinocyte and melanin retention. Hematoxylin and eosin stains demonstrate lamellar hyperkeratosis of the stratum corneum without parakeratosis as well as keratin pearls scattered throughout. Mild acanthosis and papillomatosis also have been reported.<sup>1,5-7</sup> Fontana-Masson stain shows excess melanin in these lesions, extending from the basal layer to the stratum corneum. Fungal and bacterial stains as well as cultures often have no notable findings.<sup>1,7</sup> Similarly, histopathologic examination of our patient's biopsy with hematoxylin and eosin stain revealed hyperorthokeratosis with scattered naked vellus hair shafts and incidental yeast forms (Figure 1).

The differential diagnosis for TFFD may include pityriasis versicolor, confluent and reticulated papillomatosis, acanthosis nigricans, ichthyosis, malignant melanoma, and seborrheic keratosis. All of these diagnoses can be ruled out by the easy removal of the lesions with isopropyl alcohol 70%, which was performed on our patient by scrubbing the lesions with soaked gauze (Figure 2). Indeed, removal with isopropyl alcohol 70% is both the therapeutic and diagnostic procedure for TFFD.<sup>1-8</sup> Of note, dermatitis neglecta is histologically and clinically identical to TFFD, albeit with a history of uncleanly habits or exposure to dirty environments.

The diagnosis of TFFD often is discovered incidentally as physicians wipe the area with alcohol to prepare for biopsy.<sup>1</sup> Occasionally, vigorous scrubbing is needed to completely remove the lesions, and without this effort the lesions may be easily mistaken for another cutaneous



**FIGURE 1.** Terra firma-forme dermatosis histopathology showed prominent hyperorthokeratosis, naked vellus hair shafts, and incidental yeast forms (H&E, original magnification  $\times 100$ ).



**FIGURE 2.** Resolution of the plaques after scrubbing with isopropyl alcohol 70%.

process.<sup>3</sup> Failure to consider TFFD as a diagnosis has led to unnecessary endocrine workups and invasive biopsies.<sup>4</sup> Therefore, physicians should have early clinical suspicion of TFFD and be aware of the bedside diagnostic procedure using isopropyl alcohol.

## REFERENCES

1. Duncan WC, Tschen JA, Knox JM. Terra firma-forme dermatosis. *Arch Dermatol*. 1987;123:567-569.
2. Greywal T, Cohen PR. Terra firma-forme dermatosis: a report of ten individuals with Duncan's dirty dermatosis and literature review. *Dermatol Pract Concept*. 2015;5:29-33.
3. Moon J, Kim MW, Yoon HS, et al. A case of terra firma-forme dermatosis: differentiation from other dirty-appearing diseases. *Ann Dermatol*. 2016;28:413-415.
4. Berk DR. Terra firma-forme dermatosis: a retrospective review of 31 patients. *Pediatr Dermatol*. 2012;29:297-300.
5. Akkash L, Badran D, Al-Omari AQ. Terra firma forme dermatosis. case series and review of the literature. *J Dtsch Dermatol Ges*. 2009; 7:102-107.
6. Ashique KT, Kaliyadan F, Goyal T. Terra firma-forme dermatosis: report of a series of 11 cases and a brief review of the literature. *Int J Dermatol*. 2016;55:769-774.
7. Chun SW, Lee SY, Kim JB, et al. A case of terra firma-forme dermatosis treated with salicylic acid alcohol peeling. *Ann Dermatol*. 2017;29:83-85.
8. Aslan NC, Guler S, Demirci K, et al. Features of terra firma-forme dermatosis. *Ann Fam Med*. 2018;16:52-54.