



Chronic diarrhea in a 64-year-old woman

Our patient presented with abdominal pain and worsening diarrhea. She had no significant medical history, but imaging studies helped us make the Dx.

A 64-YEAR-OLD WOMAN with no significant medical history presented to the emergency department with worsening intermittent abdominal pain and chronic diarrhea, which had increased in frequency over the prior 3 months. She had taken loperamide, which yielded mild symptomatic relief. A complete metabolic panel revealed no significant abnormalities, with a normal inflammatory marker and erythrocyte sedimentation rate (ESR).

Physical examination revealed mild ten-

derness to palpation over the right hemiabdomen, but no rebound tenderness or guarding. An abdominal radiograph (FIGURE 1), computed tomography (CT) without contrast of the abdomen and pelvis (FIGURE 2), and a whole-body octreotide scan (FIGURE 3) were ordered.

- WHAT IS YOUR DIAGNOSIS?
- HOW WOULD YOU TREAT THIS PATIENT?

Don N. Nguyen, MD, MHA;
Cassie D. Tran, MD; Nicholas C. Cleveland, DO; Matthew S. Hartman, MD

Department of Diagnostic Radiology (Drs. Nguyen and Hartman), Department of Family Medicine (Dr. Tran), Department of General Surgery (Dr. Cleveland) Allegheny Health Network, Pa

Nguyendn3@gmail.com

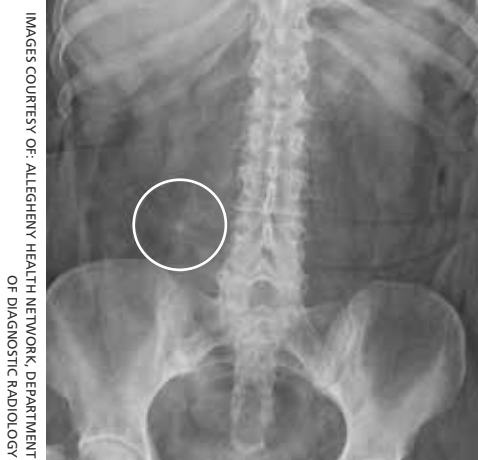DEPARTMENT EDITOR

Richard P. Usatine, MD
University of Texas Health at San Antonio

The authors reported no potential conflict of interest relevant to this article.

FIGURE 1

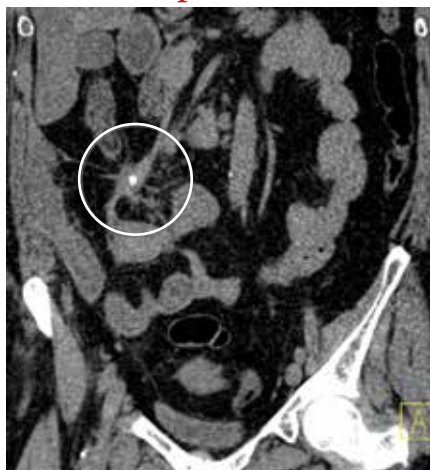Abdominal radiograph



Indeterminate calcification was seen in the right lower quadrant, with associated linear soft tissue strands radiating from the center.

FIGURE 2

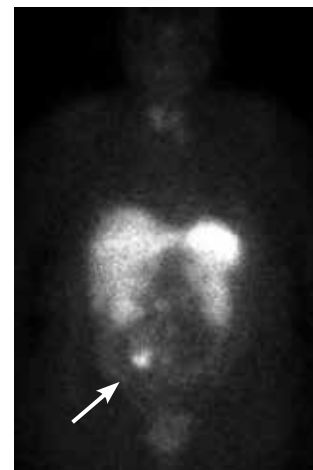
Abdominopelvic CT



Unenhanced computed tomography of the abdomen and pelvis showed a 2.6-cm mesenteric mass with calcification and a stellate, sunburst appearance in the right lower quadrant.

FIGURE 3

Whole-body octreotide scan



Abnormal focal intense radiotracer uptake was seen in the corresponding right lower quadrant mass (arrow).

IMAGES COURTESY OF: ALLEGHENY HEALTH NETWORK, DEPARTMENT OF DIAGNOSTIC RADIOLOGY

➤ **Carcinoid tumors are derived primarily from serotonin-producing cells in the gastrointestinal tract, which can lead to symptoms such as chronic diarrhea.**

Diagnosis: Carcinoid tumor

Based on the patient's symptoms and imaging studies, we suspected that she had a carcinoid tumor with mesenteric involvement. The CT showed a 2.6-cm mesenteric mass with a characteristic sunburst pattern and desmoplastic stranding, as well as numerous prominent retroperitoneal lymph nodes, suggestive of nodal involvement. The octreotide scan showed abnormal focal intense radiotracer uptake in the corresponding right lower quadrant mass, which confirmed our suspicion. There was no evidence of hepatic metastasis on the CT or octreotide scan.

Most common locations

Carcinoid tumors are the most common type of neuroendocrine tumors and are derived primarily from serotonin-producing enterochromaffin cells.¹ These slow-growing, well-differentiated tumors usually originate in the gastrointestinal and bronchopulmonary tracts (67.5% and 25.3%, respectively), with uncommon primary sites involving the mesentery, ovaries, and kidneys.² Generally, carcinoid tumors that arise in the mesentery are metastatic, often from an occult primary site. It has been reported that 40% to 80% of midgut carcinoid tumors spread to the mesentery.³

Carcinoid tumors are estimated to occur in 1.9 individuals per 100,000 annually.⁴ Traditionally, the appendix was cited as the most common location for these tumors. However, more recently, Modlin et al² conducted a comprehensive analysis of epidemiologic data from the 13,715 carcinoid tumors registered in the National Cancer Institute database. Over the more than 25-year study period (1973-1999), Modlin and colleagues found a significant change in the distribution of gastrointestinal carcinoid tumors, with the incidence rates of small bowel (41.8%) and rectal carcinoids (27.4%) increasing, while appendiceal carcinoids decreased (24.1%).²

Gastrointestinal complications can arise from metastasis

Small bowel carcinoid tumors often manifest with intermittent abdominal pain, which can be caused by fibrosis of the mesentery, intestinal obstruction, or kinking of the bowel. Less common is the constellation of diarrhea,

cutaneous flushing, and asthma seen with carcinoid syndrome. The prevalence of this syndrome is mediated by various humoral factors, the most notable of which is serotonin.

Patients with carcinoid syndrome often have metastasis to the liver, where serotonin is normally metabolized. This metastasis allows serotonin and other vasoactive substances to bypass hepatic metabolic degradation, resulting in the aforementioned symptoms. Carcinoid syndrome can also occur without hepatic metastasis in the setting of nodal involvement, which enables direct hormone release into the systemic circulation.⁵

Carcinoid syndrome affects fewer than 10% of patients with carcinoid tumors.⁶ Therefore, although carcinoid tumor should be suspected in patients with suggestive symptoms, other diagnoses must be considered.

Other disorders to consider on work-up

Chronic diarrhea and colicky abdominal pain are nonspecific features also associated with conditions such as inflammatory bowel disease and celiac disease, necessitating further work-up to elucidate the diagnosis.

■ **Inflammatory bowel disease** often involves elevated inflammatory markers, such as increased ESR and C-reactive protein.

■ **Ulcerative colitis** can show thickened and inflamed bowel walls on CT, with cross-sectional target appearance due to transmural involvement.

■ **Crohn's disease** usually affects the terminal ileum. CT is useful for identifying complications such as strictures/fistulas and abscesses.

■ **Celiac disease** involves elevated endomysial antibody and human tissue transglutaminase antibody. On CT, a characteristic jejunoileal fold pattern reversal can be seen.

A 24-hour urine test + imaging studies

The most useful diagnostic test for carcinoid tumor is the 24-hour urinary test for 5-hydroxyindoleacetic acid (5-HIAA), the metabolic end-product of serotonin. The normal rate of 5-HIAA excretion ranges from 3 to 15 mg/d, whereas the rates of patients with carcinoid tumors may have elevated levels.⁷

■ **What you'll see.** On CT scan, a carcinoid tumor affecting the mesentery appears as a soft tissue mass with calcification and desmoplastic stranding, which produces a “sunburst” appearance. Another diagnostic tool is the octreotide scan, which is considered the test of choice due to its high sensitivity for detection of the tumor and metastases.⁸ The increase in somatostatin receptors seen with carcinoid tumors allows not only imaging by octreotide scan but also therapy using octreotide with larger doses of therapeutic radioactive agents.

If tumor is operable, surgery is curative

Surgery is the only curative therapy and is the mainstay of treatment for carcinoid tumors. Local segmental resection is generally adequate for tumors <2 cm without nodal involvement. However, tumors >2 cm with regional mesentery metastasis and nodal involvement require wide excision of the bowel and mesentery with lymph node dissection because of the associated higher incidence of metastasis.⁹ If the tumor has metastasized to the liver and is considered inoperable, radiolabeled octreotide or ¹³¹I-metaiodobenzylguanidine are potential treatment options for arresting tumor growth and improving survival rates.¹⁰

■ **Our patient** underwent an uncomplicated surgical resection of the mesenteric

carcinoid tumor and adjacent small bowel, as well as lymph node dissection. Intraoperatively, there was no evidence of tumor elsewhere in the abdomen or pelvis, including the liver, ovaries, and other solid organs, suggesting probable metastasis from an occult primary site. The patient had an unremarkable postoperative course and was reported to be asymptomatic on follow-up.

JFP

CORRESPONDENCE

Don N. Nguyen, MD, MHA, Dept. of Diagnostic Radiology, 320 E. North Ave., Pittsburgh, PA 15212; Nguyendn3@gmail.com

References

1. Pinchot SN, Holen K, Sippel RS, et al. Carcinoid tumors. *Oncologist*. 2008;13:1255-1269.
2. Modlin M, Lye KD, Kidd M. A 5-decade analysis of 13,715 carcinoid tumors. *Cancer*. 2003;97:934-959.
3. Park I-S, Kye B-H, Kim H-S, et al. Primary mesenteric carcinoid tumor. *J Korean Surg Soc*. 2013;84:114-117.
4. Crocetti E, Paci E. Malignant carcinoids in the USA, SEER 1992-1999: an epidemiological study with 6830 cases. *Eur J Cancer Prev*. 2003;12:191-194.
5. Sonnet S, Wiesner W. Flush symptoms caused by a mesenteric carcinoid without liver metastases. *JBR-BTR*. 2002;85:254-256.
6. Levy AD, Sobin L. Gastrointestinal carcinoids: imaging features with clinicopathologic comparison. *RadioGraphics*. 2007;27:237-257.
7. Maroun J, Kocha W, Kvols L, et al. Guidelines for the diagnosis and management of carcinoid tumours. Part 1: the gastrointestinal tract. A statement from a Canadian National Carcinoid Expert Group. *Curr Oncol*. 2006;13:67-76.
8. Woodside KJ, Townsend CM, Mark Evers B. Current management of gastrointestinal carcinoid tumors. *J Gastrointest Surg*. 2004;8:742-756.
9. de Vries H, Verschuere RC, Willems PH, et al. Diagnostic, surgical and medical aspect of the midgut carcinoids. *Cancer Treat Rev*. 2002;28:11-25.
10. Akerstrom G, Hellman P, Hessman O, et al. Management of midgut carcinoids. *J Surg Oncol*. 2005;89:161-169.



MEDJOBNETWORK.com

Physician • NP/PA Career Center

**The first mobile job board
for Physicians, NPs, and PAs**

Mobile Job Searches—access MedJobNetwork.com on the go from your smartphone or tablet

Advanced Search Capabilities—search for jobs by specialty, job title, geographic location, employer, and more

