



Progressive discoloration over the right shoulder

The discolored patch on our patient’s shoulder was nothing new—but when it grew in size and developed hypertrichosis, it prompted a closer investigation.

A 15-YEAR-OLD CAUCASIAN BOY presented for evaluation of an asymptomatic brown patch on his right shoulder. While the patient’s mother first noticed the patch when he was 5 years old, the discolored area had recently been expanding in size and had developed hypertrichosis. The patient was otherwise healthy; he took no medications and denied any symptoms or history of trauma to the area. None of his siblings were similarly affected.

A physical examination revealed a well-demarcated hyperpigmented patch with an irregularly shaped border and an increased

number of terminal hairs (FIGURE 1). The affected area was not indurated, and there were no muscular or skeletal abnormalities on inspection. Examination of the patch under a dermatoscope revealed islands of reticular (lattice-like) hyperpigmentation, focal hypopigmentation, and prominent follicles (FIGURE 2).

- WHAT IS YOUR DIAGNOSIS?
- HOW WOULD YOU TREAT THIS PATIENT?

Matthew F. Helm, MD;
David Cole, MD;
Elizabeth V. Seiverling, MD
Departments of Dermatology and Family Medicine, Penn State Health Milton S. Hershey Medical Center, Hershey (Drs. Helm and Cole); Division of Dermatology, Maine Medical Partners, Portland (Dr. Seiverling)

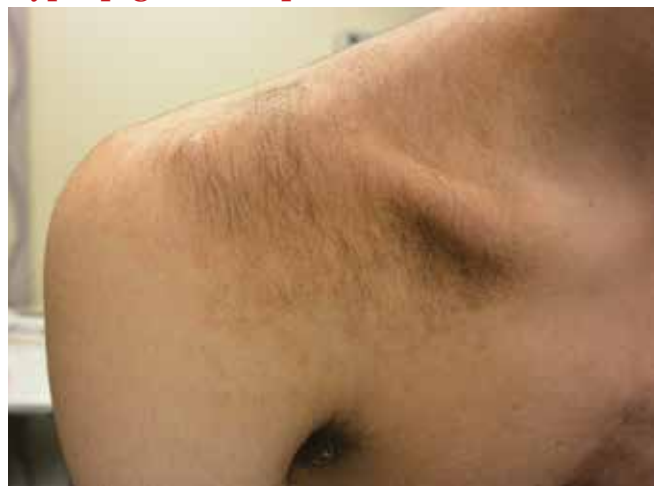Mhelm2@pennstatehealth.psu.edu

DEPARTMENT EDITOR
Richard P. Usatine, MD
University of Texas Health at San Antonio

The authors reported no potential conflict of interest relevant to this article.

FIGURE 1

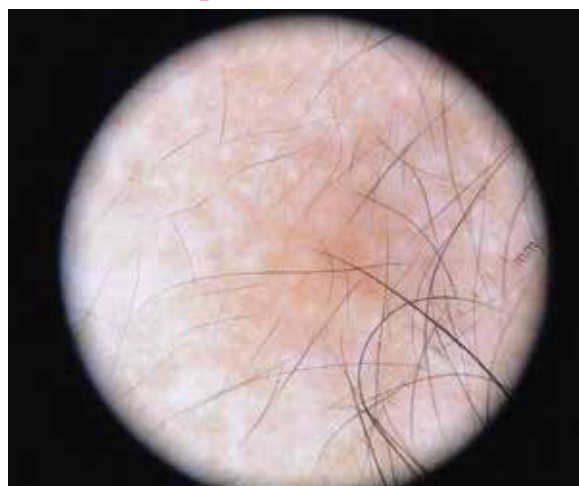
Increased hair growth on hyperpigmented patch on the shoulder



IMAGES COURTESY OF: ELIZABETH SEIVERLING, MD

FIGURE 2

A dermoscopic view



Islands of reticular hyperpigmentation, focal hypopigmentation, and prominent follicles were seen on dermoscopy.

DIAGNOSIS:
Becker melanosis

Becker melanosis (also called Becker’s nevus or Becker’s pigmentary hamartoma) is an organoid hamartoma that is most common among males.¹ This benign area of hyperpigmentation typically manifests as a circumscribed patch with an irregular border on the upper trunk, shoulders, or upper arms of young men. Becker melanosis is usually acquired and typically comes to medical attention around the time of puberty, although there may be a history of discoloration (as was true in this case).

A diagnosis that’s usually made clinically

■ **Androgenic origin.** Because of the male predominance and association with hypertrichosis (and for that matter, acne), androgens have been thought to play a role in the development of Becker melanosis.² The condition affects about 1 in 200 young men.¹ To date, no specific gene defect has been identified.

Underlying hypoplasia of the breast or musculoskeletal abnormalities are uncommonly associated with Becker melanosis. When these abnormalities are present, the condition is known as Becker’s nevus syndrome.³

■ **Look for the pattern.** Becker melanosis is associated with homogenous brown patches with perifollicular hypopigmentation, sometimes with a faint reticular pattern.^{4,5} The diagnosis can usually be made clinically, but

a skin biopsy can be helpful to confirm questionable cases. Dermoscopy can also assist in diagnosis. In this case, our patient’s presentation was typical, and additional studies were not needed.

Other causes of hyperpigmentation

The differential diagnosis includes other localized disorders associated with hyperpigmentation (TABLE^{1,3,4}).

■ **Morphea** represents a thickening of collagen bundles in the skin. Although morphea can affect the shoulder and trunk, as Becker melanosis does, lesions of morphea feel firm to the touch and are not associated with hypertrichosis.

■ **Localized post-inflammatory hyperpigmentation** occurs following a traumatic event, such as a burn, or a prior dermatosis, such as zoster. Careful history-taking can uncover an antecedent inflammatory condition. Post-inflammatory pigment changes do not typically result in hypertrichosis.

■ **Café-au-lait macules** can manifest as isolated areas of discoloration. These macules can be an important indicator of neurofibromatosis, a genetic disorder in which tumors grow in the nervous system. Melanocytic hamartomas of the iris (Lisch nodules), axillary freckling (Crowe’s sign), or multiple cutaneous neurofibromas serve as additional clues to neurofibromatosis. In ambiguous cases, a skin biopsy can help differentiate a café au lait macule from Becker melanosis.

➤ **Becker melanosis is a benign condition marked by hyperpigmentation and hypertrichosis.**

TABLE
Conditions associated with hyperpigmentation^{1,3,4}

Condition	Clinical history	Characteristics	Dermoscopy findings
Morphea	Spreading, nonpainful	Hyperpigmented and indurated plaque	Fibrotic beams and linear branching vessels
Localized post-inflammatory hyperpigmentation	Prior inflammatory condition or trauma to the site	Minimal to no change in skin texture; discoloration that gradually fades over time	No specific findings
Café-au-lait macule	Often since birth or early childhood; may be associated with neurofibromatosis	Discoloration without any textural abnormalities or other skin changes; has a “coast of California” edge	Homogeneous brown patches with perifollicular hypopigmentation; sometimes with a faint reticular pattern
Becker melanosis	Gradual pigmentation on shoulder or torso	Localized hyperpigmentation with hypertrichosis and occasional acne	Homogeneous brown patches with perifollicular hypopigmentation; sometimes with a faint reticular pattern

To treat or not to treat?

No treatment other than reassurance is needed in most cases of Becker melanosis, as it is a benign condition. Protecting the area from sunlight can minimize darkening and contrast with the surrounding skin. Electrolysis and laser therapy can be used to treat the associated hypertrichosis; laser therapy can also reduce the hyperpigmentation. Nonablative frac-

tional resurfacing accompanied by laser hair removal is also reported to be of value.⁶

■ **Our patient** was satisfied with reassurance of the benign nature of the condition and did not elect treatment. **JFP**

CORRESPONDENCE

Matthew F. Helm, MD, 500 University Drive, Suite 4300, Department of Dermatology, HU14, UPC II, Hershey, PA 17033-2360; Mhelm2@pennstatehealth.psu.edu

References

1. Rabinovitz HS, Barnhill RL. Benign melanocytic neoplasms. In: Bologna JL, Jorizzo JL, Schaffer JV, eds. *Dermatology*. 3rd ed. New York, NY: Elsevier Saunders; 2012;112:1853-1854.
2. Person JR, Longcope C. Becker's nevus: an androgen-mediated hyperplasia with increased androgen receptors. *J Am Acad Dermatol*. 1984;10:235-238.
3. Cosendey FE, Martinez NS, Bernhard GA, et al. Becker nevus syndrome. *An Bras Dermatol*. 2010;85:379-384.
4. Ingordo V, Iannazzone SS, Cusano F, et al. Dermoscopic features of congenital melanocytic nevus and Becker nevus in an adult male population: an analysis with 10-fold magnification. *Dermatology*. 2006;212:354-360.
5. Luk DC, Lam SY, Cheung PC, et al. Dermoscopy for common skin problems in Chinese children using a novel Hong Kong-made dermoscope. *Hong Kong Med J*. 2014;20:495-503.
6. Balaraman B, Friedman PM. Hypertrichotic Becker's nevi treated with combination 1,550nm non-ablative fractional photothermolysis and laser hair removal. *Lasers Surg Med*. 2016;48:350-353.

A special supplement to The Journal of Family Practice®

Hot Topics in Primary Care

Discussion of primary care topics includes expert insight into:

FREE 5 CME CREDIT

- Basal Insulin/GLP-1RA Combination Therapy
- Weight Management with Type 2 Diabetes
- NSAID Over-the-Counter Formulations
- Colorectal Cancer Screening Rates
- Migraine
- Prandial Insulin
- Statin Therapy

- Hepatitis C Infection
- Gout
- Orthostatic Hypotension
- Irritable Bowel Syndrome
- SGLT-2 Inhibitors



This supplement can be found in the Education Center on the JFP website or directly at www.mdedge.com/jfponline/hottopics2018

This supplement is sponsored by Primary Care Education Consortium.