

# Telangiectatic Melasma: A New Entity?

Series Editor:  
Doris Hexsel, MD

Marta I. Rendon, MD; Adolfo L. Benitez, MD; Jorge I. Gaviria, MD

The appearance of telangiectatic melasma, a possible subtype of melasma, has not been described in the literature. Published cases of melasma associated with telangiectasias have been secondary to the effect of topical corticosteroids, pregnancy, sun damage, rosacea, or systemic diseases. Reported herein are 4 unique cases that represent a subtype in which melasma appears in conjunction with underlying telangiectasias and is not associated with any of the previously mentioned pathogenetic mechanisms. The patients were successfully treated for their melasma with a triple-combination cream (tretinoin 0.05%, hydroquinone 4%, fluocinolone acetonide 0.01%). Even after all 4 patients were successfully treated for melasma for up to 12 weeks, the underlying telangiectasias remained easily visible on their faces (Figure 1). These preliminary observations suggest possible ramifications for the management of melasma and the need for the early detection of underlying telangiectasias.

## Melasma

Melasma is a common acquired hypermelanosis characterized by the development of sharply demarcated, blotchy brown macules. The macules of melasma typically have a symmetric distribution on sun-exposed areas of the face and neck. Although melasma can affect anyone, individuals with Fitzpatrick skin type IV or higher are more prone to develop melasma than lighter-complected individuals. Melasma presents mainly in subjects who are Hispanic, Asian, or of Indochinese or African origin. Three different distribution patterns have been described as centrofacial, malar, and mandibular. Wood lamp examination helps to differentiate between dermal and epidermal melasma.<sup>1,2</sup>

The cause of melasma is not currently understood, although many etiologic factors have been implicated (Table 1). Genetic predisposition may be important. Perhaps the clearest association is with UV light exposure.<sup>3</sup> Melasma occurs frequently during pregnancy and in women taking oral contraceptives or postmenopausal hormone replacement therapy.<sup>4-6</sup> Therefore, it is generally believed that estrogen may be important in its pathogenesis, although there is some suggestion that melasma may be associated with thyroid abnormalities in some cases.<sup>7</sup> Cancer chemotherapeutic agents are a common cause of facial hyperpigmentation, and the cardiac drug amiodarone has been associated with a similar type of facial hyperpigmentation.<sup>8,9</sup> In addition, photosensitizing and phototoxic medications, such as phenytoin and hydantoin derivatives, sulfonamides, tetracyclines, and minocycline, may cause a melasmalike hyperpigmentation, as may plant psoralens. A similar pattern of facial hyperpigmentation may also be associated with chronic liver disease.

Throughout the years, many different medications and combinations of drugs and cosmetic procedures have been used for the treatment of melasma. The mainstay has been topical hydroquinone, but topical corticosteroids, retinoic acid and its derivatives and analogues, azelaic acid, kojic acid, and many herbal compounds have been used with varying degrees of success.<sup>10</sup>

Kligman and Willis<sup>11</sup> initially developed their triple-combination formulation (dexamethasone 0.1%, tretinoin 0.1%, hydroquinone 5%) as a way of enhancing the depigmenting activity of topical hydroquinone. Earlier observation had suggested a skin-lightening effect was obtainable with corticosteroids. Tretinoin was added because its epidermal renewal effect seemed to further improve results. Kligman and Willis<sup>11</sup> later stated that tretinoin caused a dispersion of pigment granules in keratinocytes and accelerated epidermal turnover so that pigment was lost more rapidly. In their original study, Kligman and Willis<sup>11</sup> compared the efficacy of the triple-combination agent with that of each ingredient applied singly and in dual combinations and found that omission of even 1 ingredient vitiated the depigmenting

---

*Dr. Rendon is Medical Director, and Dr. Benitez and Dr. Gaviria were Research Fellows, all at the Dermatology and Aesthetic Center, Boca Raton, Florida. Dr. Rendon is also Associate Clinical Professor, University of Miami, Florida, and Associate Clinical Professor, Florida Atlantic University, Boca Raton.*

*The authors report no conflict of interest in relation to this article.*

# MANAGING MELASMA



**Figure 1.** Patient with severe melasma at baseline (A) and at week 12 posttreatment with a triple-combination cream containing tretinoin 0.05%, hydroquinone 4%, and fluocinolone acetonide 0.01% (B). The telangiectasias present at baseline remained after treatment was completed. Photographs courtesy of Pearl E. Grimes, MD.

effect. In the later clinical trials, the efficacy and tolerability of each possible combination of 2 of the 3 ingredients were compared with those of the triple-combination formulation, with the same resulting loss of efficacy. The 3 components, therefore, appear to have additive, or even synergistic, effects.

Combination therapies and newer delivery systems are more effective than single agents used alone. There are combination products with hydroquinone that contain

retinol, vitamin C, and vitamin E, either with or without glycolic acid, that are used to treat melasma. The only prescription triple-combination product available in the United States indicated for the treatment of melasma is a cream formulation containing hydroquinone 4%, retinoic acid 0.05%, and fluocinolone acetonide 0.01%. Dual-combination products are also efficacious and particularly useful in patients with mild or moderate disease or who are unable to tolerate an ingredient in the triple combination.

In clinical trials, triple-combination treatment has been shown to be effective and well tolerated in the management of melasma.<sup>12</sup> In two 8-week, multicenter, randomized, investigator-blinded studies, 26% of patients treated with the triple-combination formulation experienced complete clearing of their melasma by week 8 compared with 3 groups of controls who received creams containing 2 of the 3 ingredients. At week 8, more than 70% of those treated with the triple-combination cream had a 75% reduction in their melasma. It was reported that only 3% of the patients treated with the triple-combination cream experienced telangiectasias. However, it is important to note that the telangiectasias were not treatment related; all patients had reported them at baseline. The most common adverse reactions associated with triple-combination treatment were mild erythema, peeling, burning, and stinging.

## Telangiectasia

Telangiectasias, also known as vascular ectasias or vascular stasis, are a permanent dilation of small blood vessels (capillaries, arterioles, venules), creating focal red lesions. Telangiectasias are visible as nonpulsatile, fine, bright red lines or netlike patterns on the skin. They may or may not disappear with application of pressure.

TABLE 1

## Etiology of Facial Melasma

- Genetic predisposition
- UV light exposure
- Pregnancy
- Oral contraceptives and hormone replacement therapy
- Autoimmune thyroid disease
- Cancer chemotherapeutic agents
- Amiodarone
- Cosmetics
- Phototoxic medicines (eg, phenytoin)
- Plant psoralens (eg, oil of bergamot)

TABLE 2

Causes of Facial Telangiectasias

Common	Less Common
Age	Ataxia telangiectasia
Alcohol use	Bloom syndrome
Photodamage	Café-au-lait spots
Sun and wind exposure	Carcinoid syndrome
Topical corticosteroids	Use of carmustine and hydroxyurea
Rosacea	Connective tissue disorders
Scars	Cutis marmorata telangiectasia congenita
Burns	Hereditary hemorrhagic telangiectasia (Osler-Weber-Rendu syndrome)
Nevus flammeus (port-wine stain)	Kippel-Trenaunay-Weber syndrome
Poikiloderma	Sturge-Weber disease
Spider angioma	Systemic lupus erythematosus
	Telangiectatic lymphatica lymphangioma
	Telangiectatic macularis eruptive persistans
	Unilateral nevoid telangiectatic syndrome
	Xeroderma pigmentosa

Although most commonly seen on the skin, telangiectasias associated with other disease states may also appear on the conjunctivae and mucous membranes. Table 2 lists some of the different conditions in which facial telangiectasias may be present. Many are uncommon in daily clinical practice. However, telangiectasias are more frequently observed in the settings of chronic sun exposure, rosacea, alcohol abuse and chronic liver disease, lymphoma, and carcinoid tumors. Telangiectasias and melasma both occur independently in pregnancy as a physiologic skin change of endocrine origin related to increased serum levels of melanocyte-stimulating hormone, estrogen, and progesterone. Telangiectasias, spider telangiectasias, spider angiomas, spider nevi, and nevi aranei appear between the second and fifth months of pregnancy in areas drained by the superior vena cava. They typically resolve in the first 3 months postpartum.<sup>4,13</sup> It is not uncommon to find telangiectasias underlying solar lentigines. A subtype of rosacea known as erythematotelangiectatic rosacea is characterized by flushing, erythema,

and telangiectasias. Telangiectasias are also common in papulopustular rosacea.<sup>14</sup>

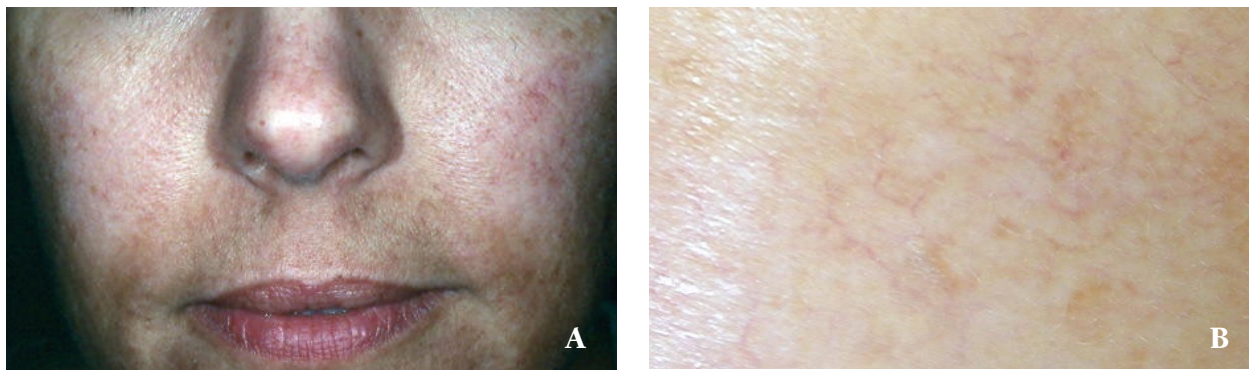
Finally, dermatologists have long been aware of the possible appearance of telangiectasias as a consequence of long-term use of potent topical corticosteroids on the face. However, nothing has been written in the literature regarding the coexistence of telangiectasias in corticosteroid-naïve patients with melasma.

For the purposes of this article, we include reports of 4 patients who have presented in our clinic with telangiectasias in association with melasma.

**Case Reports**

All patients were seen in our clinic for treatment of hyperpigmentation. Pigmented areas with telangiectasias were observed when the skin was stretched for clinical examination and were evident to the naked eye. These findings were objectively confirmed by dermoscopy, a noninvasive clinical technique utilizing a handheld illuminated microscope that provides a detailed visualization of

## MANAGING MELASMA



**Figure 2.** Patient with severe hyperpigmentation of the face (A). There are a significant number of dilated vessels and brown pigment on the cheek (B).

both pigmented areas and telangiectasias. None of the 4 patients had been treated with topical corticosteroids for any skin condition, and only 2 had received hydroquinone for treatment of their melasma in the past.

Patient 1 was a 58-year-old Hispanic female with Fitzpatrick skin type III. She presented with brown macules and freckles on her face (cheeks, tip of the nose, and forehead). During her pregnancy 30 years ago she developed persistent, blotchy, macular areas of brown pigmentation over her cheeks, forehead, upper lip, and chin. Treatment with topical bleaching agents and sun blocks had been only modestly successful. She used hydroquinone, glycolic acid, and over-the-counter (OTC) products. When examined under magnification, she was found to have a significant number of telangiectasias. The patient denied the use of topical cortisone or retinoid products and had not used any oral corticosteroids.

The patient's history and physical exam were consistent with melasma, and the observation of significant numbers of telangiectasias was noted at the first visit. She was treated with triple-combination cream, and her melasma cleared over the next 8 weeks, after which the telangiectasias were even more evident.

Patient 2 was a 52-year-old Hispanic female with Fitzpatrick skin type V who presented for treatment of hyperpigmentation on her face. The patient had had blotchy pigmentation on both cheeks for more than 5 years. She denied the use of any bleaching treatment or OTC products and had never used topical or systemic corticosteroids. The patient stated that these hyperpigmented areas increased after the use of hormone replacement therapy. The only other medication that she reported was thyroid hormone replacement. On physical examination she had brown macules on both cheeks and multiple facial telangiectasias. Melasma with

telangiectasias was diagnosed, and the patient was treated with triple-combination cream with excellent results and complete resolution of her hyperpigmentation. Her telangiectasias appeared more prominent once her hyperpigmentation had disappeared.

Patient 3 was a 53-year-old Hispanic female with Fitzpatrick skin type IV who presented for treatment of hyperpigmentation on her face (cheeks and forehead). The patient stated that the hyperpigmentation had started 3 years prior to her visit; she also had multiple matlike telangiectasias. There were no other areas of hyperpigmentation and no relevant past medical history. On physical examination she presented with severely hyperpigmented dark brown macules affecting her cheeks, forehead, and chin. The patient denied the use of any previous treatment for her skin condition. Severe melasma with telangiectasias was diagnosed. The patient was treated with triple-combination cream with excellent results and complete resolution. Her significant number of telangiectasias appeared more prominent once her hyperpigmentation had resolved.

Patient 4 was a 38-year-old Hispanic female with Fitzpatrick skin type IV. She presented for treatment of hyperpigmented skin on her face. The patient had severe hyperpigmentation, which had been present for more than 10 years on her cheeks, chin, and forehead. She denied the use of any bleaching treatment or OTC products and had never used topical corticosteroids. On physical examination she had dark brown macules on her cheeks, forehead, and chin (Figure 2A). She also had a significant number of dilated vessels on both cheeks (Figure 2B). The diagnosis was severe facial melasma and telangiectasia. The patient was treated with triple-combination cream for her melasma. The area of telangiectasia was clearly seen immediately after the successful resolution of her melasma.

**TABLE 3**

**Possible Local Adverse Effects of Topical Corticosteroid Use**

- Acneiform eruptions
- Bacterial infections
- Candidiasis
- Depigmentation
- Impetigo
- Perioral dermatitis
- Rosacea
- Skin atrophy
- Striae
- Telangiectasias

**Discussion**

To the best of our knowledge, this is the first time this subtype of telangiectatic melasma has been reported in the literature. Mandry Pagan and Sanchez<sup>15</sup> reported on 10 patients with mandibular melasma and concomitant telangiectasias. In addition to the expected hyperpigmentation, histopathologic examination revealed solar elastosis and a thickened papillary dermis. Chronic sun exposure was the common factor in all 10 of these cases. We think that melasma is exacerbated or precipitated by sun exposure. The presence of telangiectasias in patients with melasma may therefore simply be a manifestation of photodamage, or it may be hormonally triggered.

Owing to the high incidence of melasma and its increased diagnosis, particularly within the Hispanic population, it is essential to identify telangiectatic melasma prior to initiating treatment for melasma. The increased use of dermoscopy will help identify patients whose telangiectasias may be obscured by hyperpigmentation. This subgroup of patients (with photodamage) may be at higher risk of developing more or more severe telangiectasias when treated with agents that contain a topical corticosteroid. However, it should be noted that telangiectasias in patients with melasma are not always an adverse effect of topical corticosteroids. In the 4 cases reported here, the use of fluocinolone acetonide, a low-potency, class VI fluorinated steroid, did not result in

development of telangiectasias, nor did it increase the area of those that were already present.

As early as the initial Kligman and Willis<sup>11</sup> study, the local adverse effects of topical corticosteroids were not observed with the triple-combination formulation (Table 3). Kligman and Willis<sup>11</sup> suggested that the tretinoin overrode the atrophic effect of the corticosteroid, while the corticosteroid appeared to antagonize the thinning effect of tretinoin on the stratum corneum. In a later study, Sarkar and associates<sup>16</sup> utilized sequential melasma therapy with clobetasol propionate 0.05% applied for 8 weeks followed by azelaic acid 20% for 16 weeks compared with azelaic acid 20% alone for 24 weeks. They also found the combination treatment to be more efficacious than the single agent. The sole steroid effect they noted was acneiform eruption, which cleared after 8 weeks. They observed no telangiectasias.

A later study in the hairless mouse model showed that the combination of tretinoin and several different topical steroids did not result in atrophy. Moreover, it was shown that while counteracting the undesirable effects of corticosteroids, tretinoin did not adversely affect their anti-inflammatory abilities.<sup>17</sup> This finding was corroborated in a study of psoriasis patients that noted that tretinoin “partially ameliorates epidermal atrophy produced by the topical corticosteroid.”<sup>18</sup> In the clinical trials of the triple-combination agent, a 3% incidence of telangiectasias was noted, but the authors stated that most were mild and occurred in patients who had them prior to enrollment in the trial. A subsequent 24-week extension study revealed a 4% incidence of mild telangiectasias, many of which had resolved or improved by study end.<sup>12</sup>

**Conclusion**

Whether telangiectatic melasma constitutes a new syndrome or merely a chance confluence of etiologic factors will be important to ascertain, given the newer combination agents used to treat pigmentary abnormalities, some of which might increase the risk of these vascular lesions.

We want to create awareness of the need for careful clinical evaluation of patients with melasma with an underlay of telangiectasias since this presentation might not be an uncommon finding. Whether the telangiectasias are a measure of skin type, are related to genetic or ethnic background, or are secondary to photodamage still needs to be elucidated. Further studies should be conducted to see what the true incidence of this disorder is in the present melasma population.

# MANAGING MELASMA

## References

1. Grimes PE. Melasma: etiologic and therapeutic considerations. *Arch Dermatol.* 1995;131:1453-1457.
2. Pandya AG, Guevara IL. Disorders of hyperpigmentation. *Dermatol Clin.* 2000;18:91-98.
3. Pathak MA, Fitzpatrick T, aus EW. Usefulness of retinoic acid in the treatment of melasma. *J Am Acad Dermatol.* 1986;15:894-899.
4. Winton GB, Lewis CW. Dermatoses of pregnancy. *J Am Acad Dermatol.* 1982;6:977-998.
5. Resnik S. Melasma induced by oral contraceptive drugs. *JAMA.* 1967;199:601-605.
6. Snell RS, Bischitz PG. The effect of large doses of estrogen and progesterone on melanin pigmentation. *J Invest Dermatol.* 1960;35:73-82.
7. Lutfi RJ, Fridmanis M, Misiunas AL, et al. Association of melasma with thyroid autoimmunity and other thyroidal abnormalities and their relationship to the origin of melasma. *J Clin Endocrinol Metab.* 1985;61:28-31.
8. Susser WS, Whitaker-Worth DL, Grant-Kels JM. Mucocutaneous reactions to chemotherapy. *J Am Acad Dermatol.* 1999;40:367-398.
9. Bork K. *Cutaneous Side Effects of Drugs.* Philadelphia, Pa: WB Saunders Co; 1988:201-213.
10. Pérez-Bernal A, Muñoz-Pérez MA, Camacho F. Management of facial hyperpigmentation. *Am J Clin Dermatol.* 2000;1:261-268.
11. Kligman AM, Willis I. A new formula for depigmenting human skin. *Arch Dermatol.* 1975;111:40-48.
12. Taylor SC, Torok H, Jones T, et al. Efficacy and safety of a new triple-combination agent for the treatment of facial melasma. *Cutis.* 2003;72:67-72.
13. Kroumpouzou G, Cohen LM. Dermatoses of pregnancy. *J Am Acad Dermatol.* 2001;45:1-19.
14. Wilkin J, Dahl M, Detmar M, et al. Standard classification of rosacea: Report of the National Rosacea Society Expert Committee on the Classification and Staging of Rosacea. *J Am Acad Dermatol.* 2002;46:584-587.
15. Mandry Pagan R, Sanchez JL. Mandibular melasma. *P R Health Sci J.* 2000;19:231-234.
16. Sarkar R, Bhalla M, Kanwar AJ. A comparative study of 20% azelaic acid cream monotherapy versus a sequential therapy in the treatment of melasma in dark-skinned patients. *Dermatology.* 2002;205:249-254.
17. Kligman LH, Schwartz E, Lesnik RH, et al. Topical tretinoin prevents corticosteroid-induced atrophy without lessening the anti-inflammatory effect. *Curr Probl Dermatol.* 1993;21:79-88.
18. McMichael AJ, Griffiths CE, Talwar HS. Concurrent application of tretinoin (retinoic acid) partially protects against corticosteroid-induced epidermal atrophy. *Br J Dermatol.* 1996;135:60-64. ■