

Temporal Brow-lift With Botulinum Toxin Type A: Review of Existing Methods and Description of an Easy and Reliable Method to Achieve a Lateral Temporal Brow-lift

Kristina Paley, MD; Suzan Obagi, MD

The brow-lift effects achieved by botulinum toxin type A (BTX-A) are among the most pleasing to patients. However, there are many different methods described to achieve brow-lifting. Some of these involve the use of a relatively high dose of BTX-A whereas others require a number of different injection sites. We present a review of these methods and our simplified technique for achieving lateral brow-lifting using one injection site and a low dose of BTX-A.

Botulinum toxin type A (BTX-A), a neurotoxin derived from the obligate anaerobe *Clostridium botulinum*, was first introduced for use in facial rejuvenation in the early 1990s.¹ Today, it is the most sought-out cosmetic procedure by both women and men.² Since the initial induction of BTX-A into the arena of cosmetic dermatology, a number of injection techniques have been developed to augment rhytides in both the upper and the lower face. In this article, we will review BTX-A application for temporal

brow-lift and describe a simple yet reproducible way to achieve lateral brow-lifting.

ANATOMY BEHIND THE TEMPORAL BROW-LIFT TECHNIQUE

Like anywhere else in the body, the different muscles of the forehead act in opposition to each other to produce our facial expressions. Frontal bellies of the occipitofrontalis muscle raise the eyebrows in opposition to brow depressors, which include the orbicularis oculi, procerus, and corrugator supercilii muscles (Figure 1).³

BTX-A INJECTION TECHNIQUES USED FOR THE TEMPORAL BROW-LIFT

The notion that BTX-A-mediated paralysis of the primary lateral brow depressor, the orbital portion of the orbicularis oculi muscle, results in temporal elevation of the brow through unopposed action of the frontalis

Dr. Paley is Dermatology Resident, University of Pittsburgh School of Medicine, and Dr. Obagi is Assistant Professor of Dermatology, University of Pittsburgh School of Medicine, and Director, Cosmetic Surgery and Skin Health Center, Sewickley, Pennsylvania.

The authors report no conflicts of interest in relation to this article.



Figure 1. Anatomic illustration showing balance of muscular forces (arrows) acting on the brow. Illustration courtesy of Kameo W. Munnell.

muscle was first demonstrated in 1999 by Huilgol et al⁴ and then in 2000 by Ahn et al⁵ and Huang et al.⁶

In their study, Ahn et al⁵ observed statistically significant ($P < .0001$) increases in brow height after injection of 7 to 10 U of BTX-A into the superolateral portion of the orbicularis oculi at 3 sites below the lateral one third of the brow. In their subsequent study, the injection doses were increased to 16 to 20 U to further maximize the brow-elevation effect.⁷

Huang et al⁶ used doses of BTX-A similar to those of Ahn's group to elevate both the central and the lateral portions of the brow. Ten units of BTX-A were injected into 4 sites, starting at the midpupillary position and extending below the lateral brow. However, with this technique, maximal elevation in the central portion of the brow was observed.

Huilgol et al⁴ described a technique that was different from those of the Ahn and Huang groups not only in location but also in the amount of BTX-A that they used to elevate the lateral portion of the brow. In their study, Huilgol et al⁴ injected 1 to 2.5 U of BTX-A into the supralateral eyebrow above the eyebrow at the level of the lateral canthus to achieve lateral brow elevation. The injection techniques from all 3 groups are summarized in Figure 2.

In a more recent study, Lee et al⁸ used 2 different approaches, both similar to those of the Ahn and Huang groups, involving injections into the superolateral portion of the orbicularis oculi below the lateral third of the brow. A total of 5 U of BTX-A was used at 2 injection sites per lateral brow. As expected, statistically significant elevation in the lateral portion of the brow was noted in both protocols.

OUR EXPERIENCE WITH THE TEMPORAL BROW-LIFT

In the methods previously described to achieve brow-lifting, either significantly higher doses of BTX-A were used, a variable amount was used, or several injection

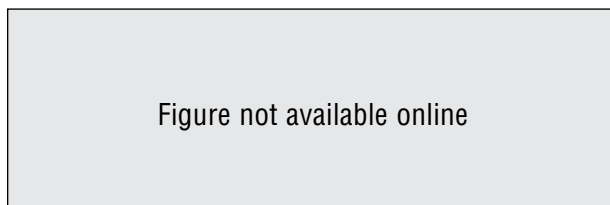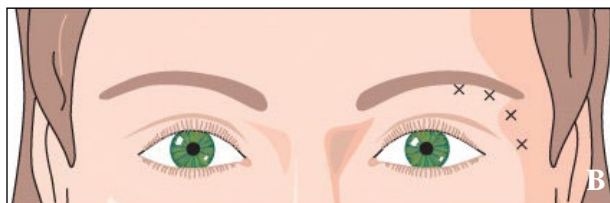
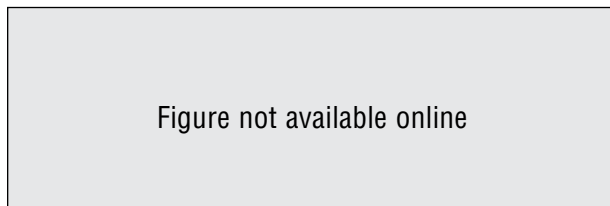


Figure 2. Botulinum toxin type A injection sites as described by Ahn et al⁵ (A), Huang et al⁶ (B), and Huilgol et al⁴ (C). Illustration courtesy of Kameo W. Munnell.

sites were used that make the technique a bit more cumbersome. Furthermore, Ahn et al⁵ reported a 4.5% incidence of overly elevated brows and a 4.5% incidence of "trace" ptosis in patients. However, the biggest challenge in achieving the temporal brow-lift is accurate and consistent placement of the injection.

We have found that even smaller amounts of BTX-A than those previously described can effectively elevate the lateral portion of the brow. We inject 2 U of BTX-A at one site on the supralateral eyebrow below the eyebrow, into the lateral orbicularis oculi muscle. This location is determined by either feeling for the bony frontotemporal fusion point or by having the patient squint tightly and injecting into the portion of the orbicularis oculi muscle that pulls the brow down, in a parallel approach to the line formed by the squint (Figures 3 and 4).

Our technique is similar to that proposed by Glaich et al⁹ and Cohen and Dayan,¹⁰ who recommend using 4 to 6 U per side and also inject into the lateral infrabrow. In their study comparing 4- to 6-U injections, Cohen and Dayan¹⁰ noted no statistically significant difference between groups in terms of efficacy and degree of improvement in dermatochalasis. These authors use higher doses but minimize diffusion to the frontalis by using a more concentrated dilution of BTX-A (10 U/0.1 mL). Most physicians find this dilution of BTX-A difficult to work with. Therefore, we suggest using a 5-mL dilution but minimizing diffusion by limiting the amount of BTX-A injected

Figure not available online

Figure 3. Diagram showing bony frontotemporal fusion point (A), which is used to map the site of botulinum toxin type A injection (B). Illustration courtesy of Kameo W. Munnell.

Figure not available online

Figure 4. A patient squinting her eye tightly. The arrow shows the point where the brow is pulled down the most (A). Injection of botulinum toxin type A into the orbicularis oculi muscle parallel to the line formed by the squint (B).

to 2 U per lateral brow. Furthermore, by limiting the potential for diffusion, one reduces the risk of dry eye, which is a risk associated with use of BTX-A in the periocular region.¹¹

We find that best aesthetic results are achieved using this technique, which, like the previously described brow-lift techniques, decreases the depressor activity of the lateral portion of the orbicularis oculi muscle, thus allowing the unopposed frontalis muscle to elevate the lateral brow (Figure 5). Furthermore, by using this lower dose and limiting the injection to the lateral portion of the brow, S. Obagi, MD, has treated more than 2500 patients over a 4-year period with no incidence of ptosis. As suggested by Glaich et al,⁹ when injecting into the lateral infrabrow, it is essential to stay approximately 1.5 cm away from the orbital septum to avoid weakening of the levator palpebrae superioris muscle, which can result in eyelid ptosis, and to stay away from the lateral frontalis muscle to minimize the risk of brow ptosis.

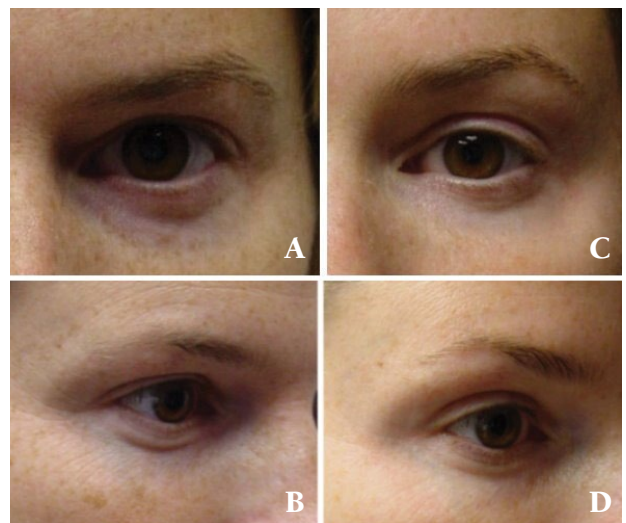


Figure 5. Patient before (A, B) and after (C, D) treatment with botulinum toxin type A as described by the authors. Note the lateral brow elevation. This patient was also treated in the glabella to elevate the medial brow.

BROW-LIFT WITH BTX-A

SUMMARY

The temporal brow-lift is probably the most sought-after result for patients. When achieved correctly, it contributes aesthetically to the results achieved when the glabella is also treated. Although patients may request treatment of the glabellar rhytides, those who have lateral brow ptosis may end up with a semicircular arch to the brow and a surprised look to their facial expressions if the lateral brow is not also addressed. A number of different brow-lift techniques have been described and discussed in this article. We believe our technique is simple, quick, and, most importantly, reproducible from patient to patient while using smaller amounts of BTX-A.

REFERENCES

1. Carruthers A, Carruthers J. Botulinum toxin type A: history and current cosmetic use in the upper face. *Semin Cutan Med Surg*. 2001;20:71-84.
2. The American Society for Aesthetic Plastic Surgery. 11.5 million cosmetic procedures in 2006. Available at: <http://www.surgery.org/press/news-release.php?iid=465>. Accessed July 31, 2007.
3. Abramo AC. Anatomy of the forehead muscles: the basis for the videoendoscopic approach in forehead rhytidoplasty. *Plast Reconstr Surg*. 1995;95:1170-1177.
4. Huilgol SC, Carruthers A, Carruthers JD. Raising eyebrows with botulinum toxin. *Dermatol Surg*. 1999;25:373-375.
5. Ahn MS, Catten M, Maas CS. Temporal brow lift using botulinum toxin A. *Plast Reconstr Surg*. 2000;105:1129-1135.
6. Huang W, Rogachefsky AS, Foster JA. Browlift with botulinum toxin. *Dermatol Surg*. 2000;26:55-60.
7. Maas CS, Kim EJ. Temporal brow lift using botulinum toxin A: an update. *Plast Reconstr Surg*. 2003;112(suppl):109S-112S.
8. Lee CJ, Kim SG, Han JY. The results of periorbital rejuvenation with botulinum toxin A using two different protocols. *Aesthetic Plast Surg*. 2006;30:65-70.
9. Glaich AS, Cohen JL, Goldberg LH. Achieving a lateral brow lift with botulinum toxin type A. *Cosmet Dermatol*. 2006;19:121-123.
10. Cohen JL, Dayan SH. Botulinum toxin type A in the treatment of dermatochalasis: an open-label, randomized dose-comparison study. *J Drugs Dermatol*. 2006;5:596-601.
11. Arat YO, Yen MT. Effect of botulinum toxin type A on tear production after treatment of lateral canthal rhytids. *Ophthal Plast Reconstr Surg*. 2007;23:22-24. ■