

Hair Restoration: The Present and the Future

David H. Ciocon, MD; David J. Goldberg, MD

The field of hair restoration has witnessed dramatic changes in the past 2 decades, both in the understanding of the natural physiology of the hair follicle and in the surgical techniques used to replace areas of decreased hair density. In this review we explore the latest medical, surgical, and technological developments in the field of hair restoration with an emphasis on safety and efficacy. We also explore current theories about the growth of the hair follicle and how that information has been used to develop hair restoration techniques with natural and aesthetically pleasing results. Finally, we review current indications for hair restoration with respect to medical versus surgical therapy.

From the first report of successful punch graft hair transplantation for alopecia in the Japanese literature in the 1930s,¹ to Norman Orentreich, MD, using larger 6- to 8-mm punch grafts and his description of the concept of donor site dominance in the 1950s,² to the definition of the follicular unit by John Headington, MD,³ and the development of follicular unit transplantation by B.L. Limmer, MD,⁴ the field of hair restoration has trended toward developing techniques that achieve more natural-appearing end results.⁵⁻⁷ Alternative techniques such as scalp reduction and scalp flaps have been described,⁵ but they have become largely obsolete because of procedure-related complications as well as outcomes that were aesthetically undesirable. We discuss issues regarding patient selection for hair transplantation as it relates to indications for

medical therapy versus surgical intervention. We also describe contemporary methods of hair restoration such as the combined mini-micrografting technique and the follicular unit transplantation technique as well as less common procedures such as scalp reduction, scalp extension, and scalp flaps. Finally, we explore more recent advances in noninvasive hair restoration technique, including the use of laser and light technologies to augment hair growth.

PATIENT SELECTION

Although many patients benefit from hair restoration surgery, selecting the proper patient is vital to optimizing therapeutic outcome because hair loss can typically continue throughout an individual's life. Most experts agree that the ideal candidates for hair restoration surgery are individuals with androgenetic alopecia, or male pattern baldness.^{4,8-12} The most common presentation of male pattern alopecia is the "regular" Norwood pattern, in which 2 areas of hair loss—a bitemporal recession and crown thinning—gradually enlarge and coalesce until the entire front, top, and crown of the scalp are bald.¹⁰ The various stages of the regular Norwood pattern are shown in Figure 1. In this pattern of alopecia, the occipital and parietal scalp hairs form a stable permanent zone that provides the optimal donor site for hair restoration surgery.^{2,11,12} Individuals with unpatterned forms of alopecia do not make viable transplant candidates because they lack predictable and stable hair-growth zones.

Dr. Ciocon is Clinical Instructor of Dermatology and Dr. Goldberg is Clinical Professor of Dermatology and Director of Laser Research, both at Mount Sinai School of Medicine, New York, New York. Drs. Ciocon and Goldberg are also from Skin Laser & Surgery Specialists of New York and New Jersey, Hackensack, New Jersey, and New York, New York.

Drs. Ciocon and Goldberg report no conflict of interest in relation to this article.

Correspondence: David J. Goldberg, MD, Skin Laser & Surgery Specialists of New York and New Jersey, 115 E 57th St, Ste 710, New York, NY 10022 (drdavidgoldberg@skinandlasers.com).

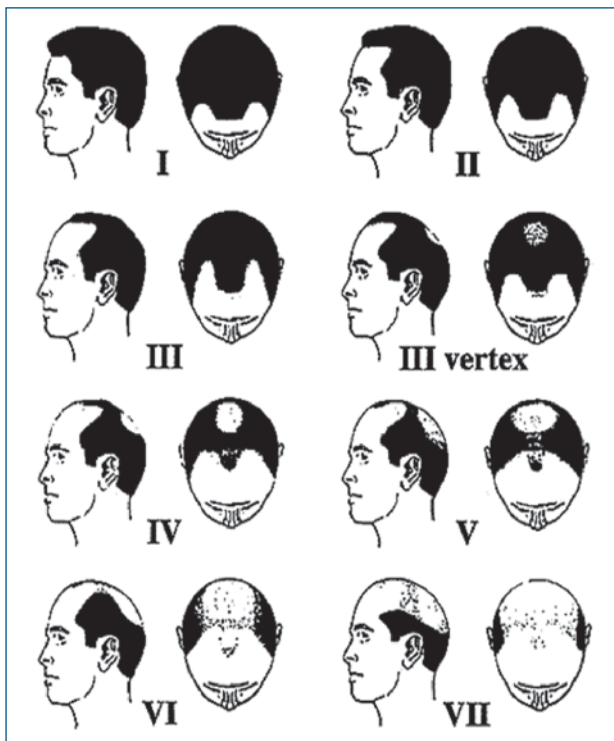


Figure 1. Norwood classification of male pattern androgenetic alopecia.

Because women tend to experience unpatterned alopecia, they often make poor candidates for hair restoration surgery. Notwithstanding, women with female pattern alopecia can be considered for hair restoration as long as secondary causes of female pattern alopecia, including iron deficiency and thyroid disorders, are ruled out.^{13,14} All patients must be screened preoperatively for potential surgical contraindications, including a history of bleeding diathesis and medications or vitamin supplements (ie, vitamin E) that promote bleeding. Regarding lifestyle modification, all patients are encouraged to avoid alcohol 2 to 3 days before surgery to minimize bleeding and to avoid tobacco for at least 24 hours before and 1 to 2 weeks after the procedure for optimal wound healing. Finally, most patients routinely are encouraged to discontinue topical minoxidil 4 to 5 days before surgery because of its vasodilative properties. Clinicians also routinely place patients on finasteride before surgery to minimize the chance of a postsurgical effluvium, though there are no controlled studies confirming this benefit.¹⁵

PREOPERATIVE PLANNING

Various opinions have been expressed regarding the optimal timing of hair transplantation with respect to

the stage of alopecia. Bernstein and Rassman⁹ have argued that hair restoration should not be contemplated for any male patient until he reaches at least the Norwood type III stage of hair loss, with the understanding that patients in this stage often benefit from monotherapy with medications such as finasteride and minoxidil. Conversely, extensive balding should not preclude someone from being a hair restoration candidate as long as the donor zone is stable with miniaturization of less than 20%, and the patient's expectations are realistic. Regarding age, most experts agree that transplantation should be postponed until the patient is in his mid-20s (23–25 years) so that medications, particularly finasteride, are given adequate time to work.⁹

MEDICAL THERAPY

Finasteride improves hair density by increasing the number of functioning hair follicles as well as individual hair caliber and length. It also functions synergistically with minoxidil, exerting its effects by inhibiting the conversion of testosterone to dihydrotestosterone, which blocks the androgen-mediated pathway of follicle miniaturization, the hallmark of androgenetic alopecia.^{12,16,17} Minoxidil is postulated to exert its effects by increasing blood flow to the hair follicle. For many years it was available only as a solution 2% or 5%, but vehicle foam 5% recently has become available. The foam does not contain propylene glycol, which was found to cause local irritation in previous formulations. As most patients show hair regrowth for up to 2 years after medical treatment is initiated, finasteride and/or minoxidil should be given for at least this long to achieve a therapeutic trial. Avram and Rogers⁶ argue that 6 to 9 months is the minimum amount of time these agents should be given, as that is the time needed for the medication to affect the new hair cycle.

SURGICAL TECHNIQUE

Hair restoration involves relocation of hairs from the occipital and parietal areas to bare areas, typically on the crown or vertex, top, and front of the scalp. Mini-micrografting is a method of hair restoration widely practiced in the 1980s that involves the harvesting and transplantation of randomly assorted groups of hair without consideration for the natural configuration of follicular units.^{1,4,18} The transplanted grafts are sectioned from a donor strip from the back of the scalp according to the number of hairs they contain. Minigrafts consist of 4 to 6 hairs while micrografts consist of 1 to 3 hairs. The minigrafts are placed into small circular recipient sites 1.5 to 2.5 mm in size made with punch blades, and sometimes into slit recipient sites made with a small

linear blade. The micrografts typically are placed into smaller incisions in front of the minigrafts to create the frontal hairline. The donor strip that provides the mini-micrografts is harvested using a multiblade knife that cuts 3 to 5 strips, each 1.5- to 2-mm wide.¹⁹ From these strips the grafts are dissected under loupe magnification or direct visualization with good lighting.

One disadvantage of the mini-micrografting technique is that the grafts do not necessarily correspond to the naturally occurring follicular units (described later in this article), so that individual follicular units may not be fully intact in a single graft. Second, use of the multiblade knife for harvesting can result in the destruction of up to 20% of the naturally occurring follicular units in the donor area, injuring potential sites for future harvesting. Finally, with this technique, all the tissue from the donor site is transplanted because trimming of the tissue would result in loss of the hair fragments within the grafts. As a result, an excess of intervening bald skin in the donor area often is transplanted along with the hairs. This not only could produce decreased optical density in the recipient area but also could potentially compromise the blood supply of the grafts and thus limit their survival.

The idea of follicular unit transplantation that emerged in the late 1980s was dependent on the recognition by Headington²⁰ that scalp hair grows in natural clusters, or "follicular units," rather than as single hairs.²¹ These units are best appreciated by clipping scalp hairs to 1 mm in length and viewing them with a magnifying hair densitometer. Each unit is a discrete, anatomic, and physiologic grouping of 1 to 4 terminal hair follicles with 1 or 2 associated vellus follicles, 9 sebaceous lobules, and arrector pili muscles. The follicular unit is surrounded by its own neurovascular bundle and circumferential adventitial collagen sheath. Limmer was the first to describe the clinical use of follicular unit grafts in the mid-1990s using stereoscopic dissection⁴, while Bernstein and colleagues^{8,9,22-27} elaborated on its rationale and optimal techniques in a series of respected publications. In contrast to mini-micrografting, each follicular unit graft is dissected out individually under stereomicroscopic visualization to permit careful removal of surrounding, non-hair-bearing skin. These grafts then are placed into tiny recipient sites, many of which are less than 1 mm.^{26,28,29} In a typical procedure, 1800 to 2200 of these follicular unit grafts are transplanted, but as many as 5000 grafts sometimes can be transferred in a single session. The number of follicular units transferred is limited, however, by the hair density, scalp laxity, and local blood supply. As recipient sites are made closer together, the likelihood

of compromising their local microvascular integrity increases, threatening the viability of the grafts.³⁰⁻³² The current recommended standard for graft density is approximately 25 to 30 follicular units per cm² per session, though there have been successful reports of up to 100 follicular units per cm² in a single session.^{27,33-37}

The follicular unit grafts can be harvested from the donor site on the occiput, either through standard single strip excision or through follicular unit extraction.³⁸ In standard strip excision, an elliptical incision is made in the region between the external occipital protuberance and 1 cm above the top of the ears after infiltration with tumescent anesthesia.^{39,40} To make the incision, experts have reported using either a single blade to make a free-hand ellipse or a scalpel handle loaded with 2 parallel #10 blades, with tapering of the ends into corners of an ellipse.^{4,41} To minimize scar formation in the donor area, most experts agree that the width of the ellipse usually should not exceed 1 cm and that its length be proportional to the number of grafts needed.^{42,43} In most reports, closure of the donor site is achieved without undermining to minimize bleeding and with a running nonabsorbable suture or staples.^{9,37} Many hair restoration surgeons also implement a "trichophytic" closure technique, which involves excising a narrow rim of epidermis along the inferior border so that the underlying hairs grow directly into the resulting donor scar. There is evidence that this technique may improve the scar's appearance, but patients also may experience a slightly higher incidence of ingrown hair formation. Once the strip is extracted, it is dissected under stereomagnification into slivers that are each 1.5- to 2-mm wide. Each sliver can then be dissected into 1- to 2-hair follicular unit grafts or 3- to 4-hair follicular unit grafts, which are held on normal saline-soaked nonadherent gauze or on Petri dishes filled with normal saline. While most hair restoration surgeons dissect these slivers under stereomicroscopic magnification,⁴⁴⁻⁴⁶ several reports from the literature have described successful follicular unit graft dissection using standard loupe magnification or naked eye visualization.⁴⁷ Furthermore, whether the follicular unit graft should be "chubby" or "skinny" has been a matter of intellectual debate and has not been tested in randomized controlled trials.^{32,48} Skinny grafts require smaller recipient sites and can be packed densely, but overly fine dissection can injure the arrector pili muscles, sebaceous glands, telogen hairs, and the follicles themselves, which may be crucial to optimal hair growth. Once harvested, grafts must be protected from desiccation.^{49,50} The timing from harvest to transplantation to the recipient site is important because graft survival rates have been demonstrated to drop from 95% at

Comparison of Follicular Unit Transplantation and Mini-Micrografting Transplantation

		Follicular Unit Transplantation	Mini-Micrografting Transplantation
Grafts	Follicular units used exclusively	Yes	No
	Graft size	Uniformly small	Larger
	Number of hairs per graft	1–4	1–6 (or more)
	Hair-to-skin ratio in graft	High	Variable
	Extra skin transplanted	No	Yes
	Recipient wound size	Uniformly small	Variable
Techniques	Harvesting types	Single strip or follicular unit extraction	Multiblade knife
	Microscopic dissection required	Yes/variable	No
	Preservation of follicular units	Yes	No
	Follicular transaction	No	Yes
	Maximizes donor supply	Yes	No
Results	Healing time	Fast	Slow
	Maximum optical density	Yes	No
Cost and Convenience	Staff requirements	Moderate	Minimal
	Duration of individual procedure	Long	Short
	Time for complete restoration	Short, if few sessions	Long
	Cost per procedure	More	Less
	Total cost for restoration	Similar	Similar

Adapted with permission from Rassman W, www.newhair.com/treatment/follicular-unit-transplants.asp.⁶⁰

2 hours to 86% after 6 hours.⁴ Therefore, experts agree that preparation of these grafts requires a well-trained, efficient, and well-coordinated ancillary staff and a surgeon meticulously trained in the expedient performance of proper follicular transplantation technique.

An alternative approach to follicular unit graft harvesting has been described and is known as follicular unit extraction.⁵¹ With this technique, each individual

follicular unit is harvested under stereoscopic magnification using a small, circular incision created by a 1-mm trephine.⁵² Each circular incision is left open to heal by secondary intention. Although more time consuming, the advantage to this technique over standard ellipse incision is the avoidance of a linear scar. Furthermore, for patients with loose or tight donor skin, or limited donor tissue because of previous restoration surgeries,

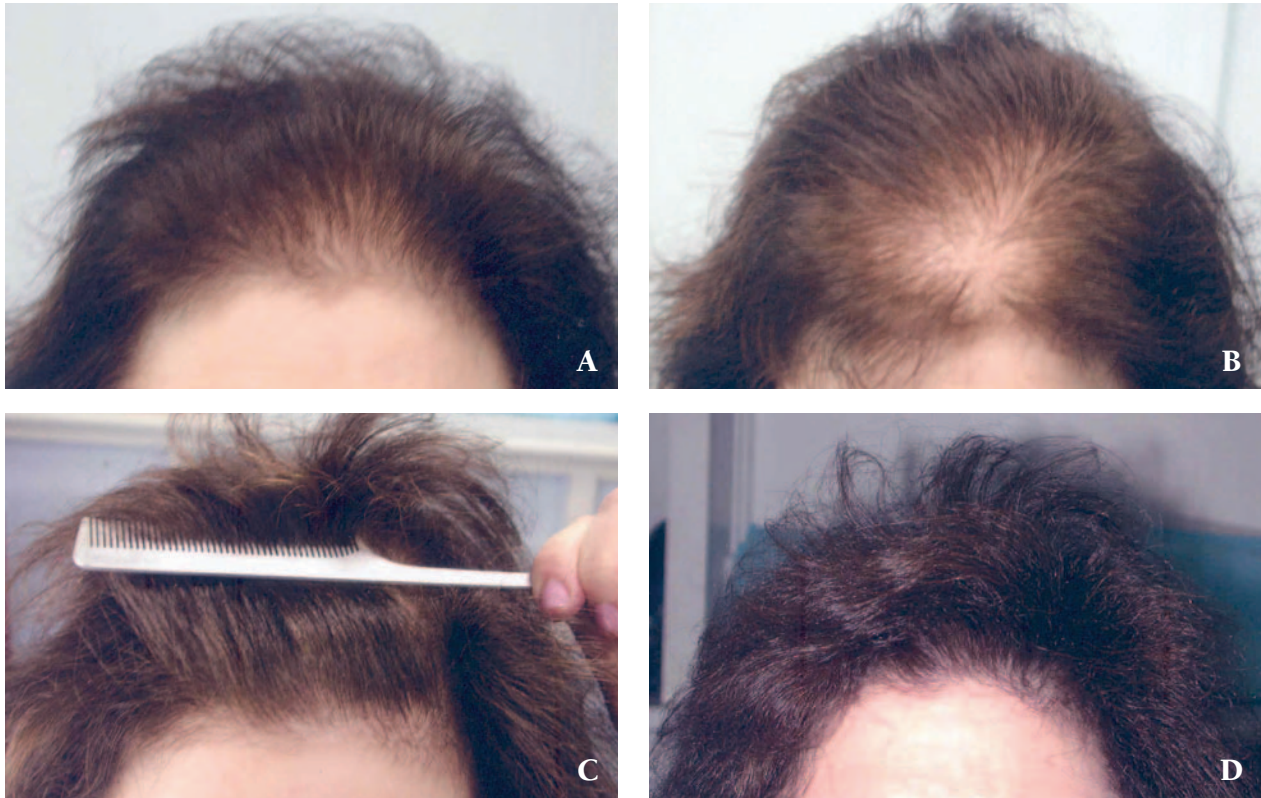

Figure 2. Before treatment with hair combed back for clinical evaluation (A), caudal view (B). Twelve months after frontal hair transplant with 934 follicular units (C) and 3½ years after second follicular unit transplantation session (D).

follicular unit extraction permits the removal of less tissue with an optical cosmetic outcome. The technique is particularly suited for hair restoration patients who want to maintain a short, or “buzzed,” hairstyle after surgery without a visible scar. The disadvantages include fewer grafts being transplanted per procedure, an increase in overall operative time and cost because of longer harvesting times, as well as an increased risk of transecting harvested hair follicles.⁵¹

Various methods for recipient hair bed preparation have been described. In the “stick and place” method, each recipient site is created by the physician, followed by immediate insertion of a graft into each site by an assistant with a jeweler’s forceps. Alternatively, all recipient sites can be created first, followed by placement of grafts into each site. The most commonly reported instruments to create these sites include a 19- or 20-gauge needle for 1- and 2-hair follicular unit grafts and an 18- or 19-gauge needle for thick 2-hair or 3- to 4-hair unit grafts.^{1,4,53} Slits are made by puncturing the scalp to a 4- to 6-mm depth and can have either a coronal or sagittal orientation, depending on the growth pattern of the surrounding native hair. Recipient

sites can be created with the aid of either loupe magnification or naked-eye visualization, though Avram⁵⁴ has reported improved results when creating the sites with polarized light-emitting diode magnification. If the recipient scalp is bare, site orientation should follow the normal angulation of 20 to 40 degrees from the plane of the scalp, with a tendency to more acute angulation along the frontal hairline and the temporal area. Sites anterior to the vertex transition line typically are oriented anteriorly and more inferiorly toward the lateral aspect. Hairs posterior to this line are more randomly configured and are oriented to match the natural whorl of the crown. It generally is agreed that placement of the recipient sites in the frontal hairline must include consideration for hairline design, feathering, and achievement of optical density.^{25,55,56} Furthermore, most experts agree that the goal of any first transplantation session should be to maximize optical density in the frontal regions of the scalp by forward weighting, which includes placing recipient sites closely together at a typical density of 30 follicular units per cm², and placing larger follicular units in the front, particularly in the forelock region.³⁶

Although the mini-micrograft and follicular unit transplantation techniques are different in both theory and practice, they should not be considered mutually exclusive. In fact, many recognized authorities have reported using both types of grafts in their practices, depending on the desired density for the areas they are transplanting.^{37,57,58} To avoid confusion, however, members of the International Society of Hair Restoration Surgery have published consensus guidelines emphasizing that, whatever method be employed, hair restoration surgeons be vigilant about documenting a precise description of both the type and number of grafts they are using, and whether they are dissecting the grafts on the basis of size, number of hairs, or number of follicular units.²⁴ In a review from 2005, Unger⁵⁹ demonstrated that grafts harvested using both techniques can be combined depending on the desired cosmetic outcome (Figures 2–4) (Table).⁶⁰

Successful artificial hair transplantation has been reported in cases where the donor site has been depleted but historically has been marred by poor quality fiber, untrained operators, and inadequate technique.⁶¹ Furthermore, follicular transplantation also has been described for other parts of the body, including the eyebrow, beard, mustache, eyelash area, and areas of scarring alopecia, though it is not commonly performed.^{62–64}

EXCISIONAL SURGERY

In addition to hair transplantation, less common surgical options for androgenetic alopecia include scalp reduction, scalp extension, and scalp flap surgery.^{1,65} Scalp reduction is defined as the excision of an area of alopecia. The size of the area that can be excised varies with the degree of natural scalp laxity and the extent of surgical undermining and/or the amount of “biological creep” created by scalp expansion or extension prior to alopecia reduction. The larger the area that can be removed, the smaller the remaining area of alopecia will be, resulting in fewer grafts being required to transplant it. Unger⁶⁶ has recommended that scalp reduction be employed anytime the objective is “complete” coverage of frontal, mid-third, or vertex alopecia. Conversely, Avram and Rogers⁶ argue that scalp reduction be limited only to the vertex of the scalp. A variety of scalp reduction patterns have been described, but the most common patterns employed are the ellipse, inverted Y, and more recently, a flattened S shape. Usually, scalp reduction is carried out after the first 2 transplants have been completed, but occasionally, scalp reduction will be done before any transplanting is started.⁶⁶

Scalp extension refers to a procedure in which a conventional scalp reduction is combined with the use of a

scalp extender.^{67,68} A scalp extender consists of a Silastic sheet with metal hooks at both ends. To allow it to be stretched to double its original width, it is hooked into the underside of the galea beneath the left and right side “permanent” rim hair. Over approximately 30 days, the Silastic sheet attempts to revert to its original size, bringing both sides of fringe hair closer together in the process. During a second scalp reduction performed after 30 days, twice the amount of alopecic skin can be removed in a conventional scalp reduction. The object of scalp extension is the removal of “all” alopecic skin. The subsequent slot of alopecic hair that remains after multiple scalp reductions and extension can be corrected by another type of surgery called a “3 flap corrective procedure.”⁶⁵

Scalp flap surgeries, most notably the Juri flap and the Fleming-Mayer flap, have been described but are no longer as popular as they were in the 1980s.⁶⁹ The pedicle of these flaps, both of which are temporoparietal flaps, arise from the posterior branch of the temporal artery. The flaps can be as long as 24 cm and are sufficient for creating an entire frontal hairline 3- to 4-cm

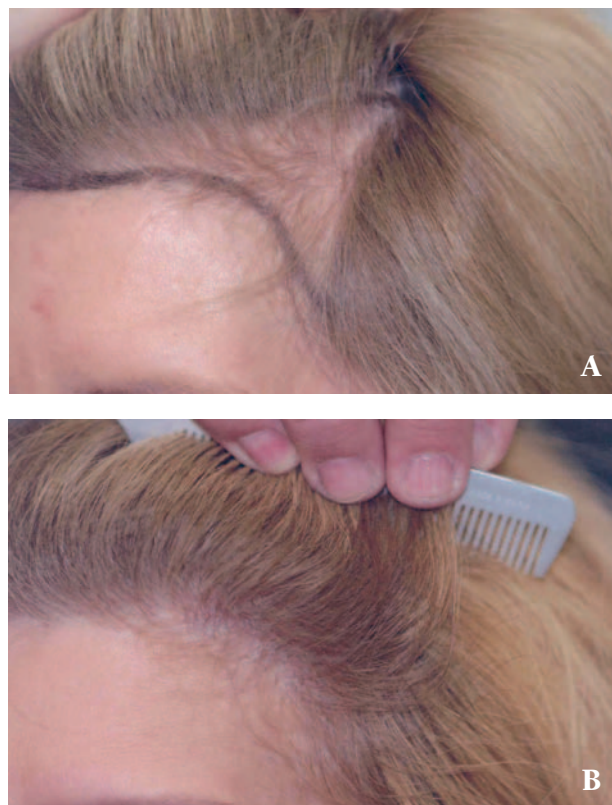

Figure 3. Patient before first transplant. The black crayon outlines the proposed recipient area for session (A). Eleven months after a session of 1973 follicular transplant units (B).

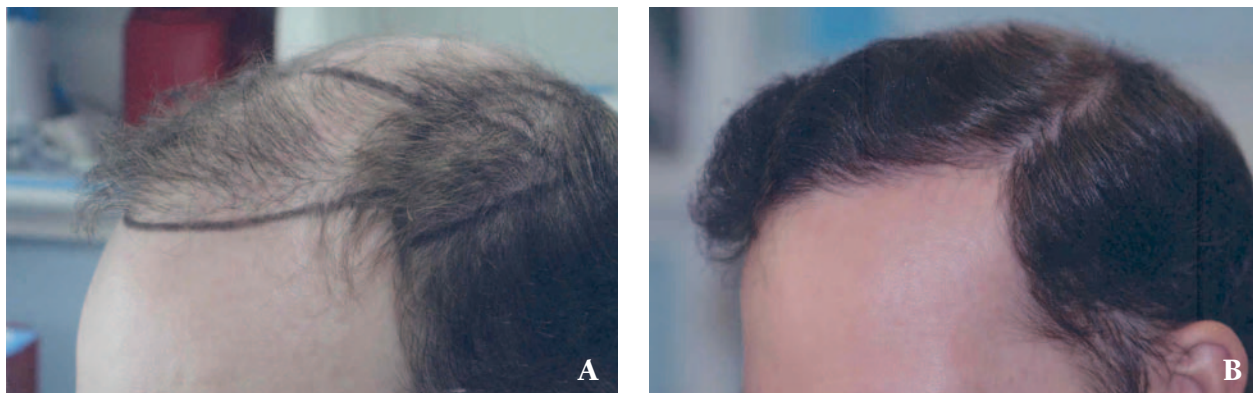


Figure 4. Crown area before first hair transplant. Patient was 45 years old with no evidence or family history of vertex male pattern baldness (A). One year posttransplant (consisting of 2132 follicular transplant units)(B).

wide. These flap procedures are rarely performed today because of their technical difficulty, limitations, and incidence of scarring, as well as because they have been largely supplanted by grafting techniques that yield more natural-appearing results.

COMPLICATIONS

Complications from hair restoration surgery are extremely low and are much more frequently associated with scalp advancement and scalp flap surgeries than with grafting.^{70,71} Most of these complications, which have been discussed in the preoperative planning section above, are typically inherent to any outpatient surgery procedure, including bleeding, infection, reactions to lidocaine or adrenaline chloride and scarring. Regarding grafting techniques, swelling over the forehead may occur 3 days postoperatively due to intravascular-to-interstitial electrolyte effects and large amounts of injected tumescent anesthesia fluid pooling. Use of short courses of oral corticosteroids or local injections of a dilute solution of intralesional corticosteroids have been advocated for this complication. Finally, long-term complications include poor graft survival and unpleasant cosmetic outcomes. Many of these complications can be avoided through careful attention to design, minimizing time between graft harvesting and transplantation, and delicate handling of graft tissue.²⁹

PHOTOBIMODULATION

In recent years, the use of laser and light sources to improve hair growth in areas of alopecia has been investigated. Photobiomodulation is the commonly used term to describe the stimulatory effect of low-intensity light energy on the cellular level. The mechanism by which photobiomodulation stops or reverses pattern hair loss is unknown. One theory suggests

that such laser and light devices increase microcirculation to the dermal papilla.⁷² Another suggests that light stimulates adenosine triphosphate synthesis in the mitochondria of exposed cells, increasing cellular metabolic activity. Hair loss treatment protocols with low-intensity light energy include shining light in the 600- to 950-nm spectrum, at low powers of 5 mW, to stimulate hair growth.⁶ Treatments can be during 15- to 30-minute sessions on alternating days for 2 to 4 weeks, tapering to 1 to 2 treatments per week for 6 to 12 months, followed by biweekly and once monthly maintenance treatments.^{73,74} Some companies have recently developed technologies to deliver the light through a brush or with a hood directly onto the scalp. One company has achieved US Food and Drug Administration 510(k) approval to market the technology as a handheld comb that contains a single laser module that emits 9 beams at a wavelength of 655 nm and a power of 4 mW (HairMax LaserComb). The device uses a technique of parting the user's hair by combs attached to the device, which improves delivery. Treatments are delivered for approximately 15 minutes, 3 times a week, for 6 months. In a recent, double-blind, sham-device-controlled study of 110 male participants with Norwood class IIa through V androgenetic alopecia who were randomized to receive treatment with either the laser comb or the sham device, those treated with the laser comb exhibited significantly greater increases ($P < .0001$) in mean terminal hair density.⁷⁵ In addition, at 26 weeks, the mean scores for patient-assessed improvement in hair growth were significantly higher ($P < .015$) for the laser comb group than the sham device group. Regarding safety, side effects were minimal and included urticaria and paresthesias in less than 5% of participants treated with the laser comb. Further research is needed to determine the efficacy of

these low-intensity light energy devices with respect to traditional treatments such as topical minoxidil or oral finasteride.

COMMENT

Hair restoration surgery is a safe and effective means of redistributing hair to areas of alopecia in individuals with pattern hair loss whose medical options have been exhausted. Although scalp advancement and scalp flap surgeries can accomplish similar ends, their results are inferior to grafting techniques with respect to postoperative and perioperative complications and achieving a “natural” cosmetic outcome. Proper training of the surgeon and the assisting team as well as judicious preoperative planning and patient selection are essential to optimizing functional and cosmetic outcomes. Future trends in hair restoration include the development of techniques that expedite the surgical process as well as noninvasive approaches that can induce hair growth with minimal downtime.

Acknowledgment—The authors would like to express their sincerest gratitude to Walter Unger, MD, who has provided representative photographs of hair transplantation for this article.

REFERENCES

- Epstein JS. Evolution of techniques in hair transplantation: a 12-year perspective. *Facial Plast Surg*. 2007;23:51-59.
- Orentreich N. Autografts in alopecias and other selected dermatological conditions. *Ann N Y Acad Sci*. 1959;83:463-479.
- Rassman WR, Bernstein RM, McClellan R, et al. Follicular unit extraction: minimally invasive surgery for hair transplantation. *Dermatol Surg*. 2002;28:720-728.
- Rawnsley JD. Hair restoration. *Facial Plast Surg Clin North Am*. 2008;16:289-297.
- Unger WP. The history of hair transplantation. *Dermatol Surg*. 2000;26:181-189.
- Avram M, Rogers N. Contemporary hair transplantation. *Dermatol Surg*. 2009;35:1705-1719.
- Patwardhan N, Mysore V; IADVL Dermatosurgery Task Force. Hair transplantation: standard guidelines of care. *Indian J Dermatol Venereol Leprol*. 2008;74(suppl):S46-S53.
- Bernstein RM, Rassman WR. Follicular unit transplantation. *Dermatol Clin*. 2005;23:393-414.
- Bernstein RM, Rassman WR. Follicular transplantation. patient evaluation and surgical planning. *Dermatol Surg*. 1997;23:771-784.
- Olsen EA, Messenger AG, Shapiro J, et al. Evaluation and treatment of male and female pattern hair loss. *J Am Acad Dermatol*. 2005;52:301-311.
- Rebora A. Pathogenesis of androgenetic alopecia. *J Am Acad Dermatol*. 2004;50:777-779.
- Whiting DA. Possible mechanisms of miniaturization during androgenetic alopecia or pattern hair loss. *J Am Acad Dermatol*. 2001;45(suppl 3):S81-S86.
- Chartier MB, Hoss DM, Grant-Kels JM. Approach to the adult female patient with diffuse nonscarring alopecia. *J Am Acad Dermatol*. 2002;47:809-818.
- Unger WP, Unger RH. The art of hair transplantation in women. *Body Lang Dermatol*. 2004;4:26-28.
- Avram MR, Cole JP, Gandelman M, et al. The potential role of minoxidil in the hair transplantation setting. *Dermatol Surg*. 2002;28:894-900.
- Thompson IM, Goodman PJ, Tangen CM, et al. The influence of finasteride on the development of prostate cancer. *N Engl J Med*. 2003;349:215-224.
- Bouhanna P. Androgenetic alopecia: combining medical and surgical treatments. *Dermatol Surg*. 2003;29:1130-1134.
- Lam SM, Karamanovski E. Surgical hair restoration. *Operative Techniques in Otolaryngology-Head & Neck Surgery*. 2007;18:195-202.
- Arnold J. Mini-blades and a mini-blade handle for hair transplantation. *Am J Cosm Surg*. 1997;14:195-200.
- Headington JT. Transverse microscopic anatomy of the human scalp. a basis for a morphometric approach to disorders of the hair follicle. *Arch Dermatol*. 1984;120:449-456.
- Choi YC, Kim JC. Single hair transplantation using the Choi hair transplanter. *J Dermatol Surg Oncol*. 1992;18:945-948.
- Bernstein RM, Rassman WR, Rashid N. A new suture for hair transplantation: poliglecaprone 25. *Dermatol Surg*. 2001;27:5-11.
- Bernstein RM. Measurements in hair restoration. *Hair Transplant Forum Int*. 1998;8:27.
- Bernstein RM, Rassman WR, Seager D, et al. Standardizing the classification and description of follicular unit transplantation and mini-micrografting techniques. *Dermatol Surg*. 1998;24:957-963.
- Bernstein RM, Rassman WR. The aesthetics of follicular transplantation. *Dermatol Surg*. 1997;23:785-799.
- Bernstein RM, Rassman WR. The logic of follicular unit transplantation. *Dermatol Clin*. 1999;17:277-295.
- Bernstein RM, Rassman WR. What is delayed growth? *Hair Transplant Forum Int*. 1997;7:22.
- Stough D, Whitworth JM. Methodology of follicular unit hair transplantation. *Dermatol Clin*. 1999;17:297-306.
- Tan Baser N, Cigsar B, Balci Akbuga U, et al. Follicular unit transplantation for male-pattern hair loss: evaluation of 120 patients. *J Plast Reconstr Aesthet Surg*. 2006;59:1162-1169.
- Leavitt M, Perez-Meza D, Barusco M. Research Symposium 1999-2000: Clinical Update on Research Studies Reported at the World Hair Restoration Society/International Society of Hair Restoration Surgery Live Surgery Workshop. *Int J Cosmetic Surg Aesthet Derm*. 2001;3:135-138.
- Mayer ML, Keene SA. Study comparing follicular unit growth with different planting densities. Presented at: 2003 Annual Meeting of the International Society of Hair Restoration Surgery; October 2003; New York, NY.
- Mayer ML, Keene SA. Hair transplant study. Presented at: 2005 Annual Meeting of the International Society of Hair Restoration Surgery; August 2005; Sydney, Australia.
- Alhaddab M, Kohn T, Sidloi M. Effect of graft size, angle, and intergraft distance on dense packing in hair transplant. *Dermatol Surg*. 2005;31:650-653.
- Limmer BL. The density issue in hair transplantation. *Dermatol Surg*. 1997;23:747-750.
- Marritt E. The death of the density debate. *Dermatol Surg*. 1999;25:654-660.

36. Unger WP. Density issue in hair transplantation. *Dermatol Surg.* 1998;24:297.
37. Unger RH, Unger WP. What's new in hair transplants? *Skin Therapy Lett.* 2003;8:5-7.
38. Seery GE. Hair transplantation: management of donor area. *Dermatol Surg.* 2002;28:136-142.
39. Brandy DA. Intricacies of the single-scar technique for donor harvesting in hair transplantation surgery. *Dermatol Surg.* 2004;30:837-844.
40. Seager DJ, Simmons C. Local anesthesia in hair transplantation. *Dermatol Surg.* 2002;28:320-328.
41. Brandy DA. New instrumentation for hair transplantation surgery. *Dermatol Surg.* 1998;24:629-631.
42. Chang SC. Estimation of number of grafts and donor area. *Hair Transplant Forum Int.* 2001;11:101-103.
43. Jimenez F, Ruifernández JM. Distribution of human hair in follicular units. a mathematical model for estimating the donor size in follicular unit transplantation. *Dermatol Surg.* 1999;25:294-298.
44. Unger WP. Suturing of donor sites. In: Unger WP, ed. *Hair Transplantation*. New York, NY: Marcel Dekker; 1979:64.
45. Bernstein RM, Rassman WR. Dissecting microscope versus magnifying loupes with transillumination in the preparation of follicular unit grafts. a bilateral controlled study. *Dermatol Surg.* 1998;24:875-880.
46. Seager D. Binocular stereoscopic dissecting microscopes: should we use them? *Hair Transplant Forum Int.* 1996;6:2-5.
47. Brandy DA. A technique for hair-grafting in between existing follicles in patients with early pattern baldness. *Dermatol Surg.* 2000;26:801-805.
48. Beehner ML. A comparison of hair growth between follicular-unit grafts trimmed "skinny" vs "chubby". *Dermatol Surg.* 1999;25:339-340.
49. Kurata S, Ezaki T, Itami S, et al. Viability of isolated single hair follicles preserved at 4 degrees C. *Dermatol Surg.* 1999;25:26-29.
50. Raposio E, Cella A, Panarese P, et al. Effects of cooling micrografts in hair transplantation surgery. *Dermatol Surg.* 1999;25:705-707.
51. Harris JA. Follicular unit extraction. *Facial Plast Surg.* 2008;24:404-413.
52. Onda M, Igawa HH, Inoue K, et al. Novel technique of follicular unit extraction hair transplantation with a powered punching device. *Dermatol Surg.* 2008;34:1683-1688.
53. Brandy DA, Meshkin M. Utilization of No-Kor needles for slit-micrografting. *J Dermatol Surg Oncol.* 1994;20:336-339.
54. Avram MR. Polarized light-emitting diode magnification for optimal recipient site creation during hair transplant. *Dermatol Surg.* 2005;31:1124-1127.
55. Beehner M. Hairline design in hair replacement surgery. *Facial Plast Surg.* 2008;24:389-403.
56. Lam SM, Hempstead BR, Williams EF. A philosophy and strategy for surgical hair restoration: a 10-year experience. *Dermatol Surg.* 2002;28:1035-1042.
57. Brandy DA. The art of mixing follicular units and follicular groupings in hair restoration surgery. *Dermatol Surg.* 2004;30:846-855.
58. Unger WP. Different grafts for different purposes. *Am J Cosmetic Surg.* 1997;14:177-183.
59. Unger WP. Hair transplantation: current concepts and techniques. *J Investig Dermatol Symp Proc.* 2005;10:225-229.
60. Rassman W. How is follicular unit transplantation different from Mini-micrografting? New Hair Institute. <http://www.newhair.com/treatment/follicular-unit-transplants.asp>. Accessed August 18, 2010.
61. Agrawal M. Modern artificial hair implantation: a pilot study of 10 patients. *J Cosmet Dermatol.* 2008;7:315-323.
62. Marritt E. Transplantation of single hairs from the scalp as eyelashes. review of the literature and a case report. *J Dermatol Surg Oncol.* 1980;6:271-273.
63. Al-Bdour M. Eyebrow to eyelid cilia transplant: a case report. *Case Rep Clin Pract Rev.* 2005;6:351-353.
64. Straub PM. Replacing facial hair. *Facial Plast Surg.* 2008;24:446-452.
65. Unger WP. Hair transplantation. In: Arndt KA, Dover JS, Kaminer MS, eds. *Atlas of Cosmetic Surgery*. Philadelphia, PA: WB Saunders; 2002:231-263.
66. Unger M. Scalp reduction. In: Unger WP, ed. *Hair Transplantation*. 3rd ed. New York, NY: Marcel Dekker; 1995:549-569.
67. Epstein JS, Kabaker SS, Puig C, et al. Scalp extension in the treatment of male pattern baldness. *Am J Cosmet Surg.* 1996;13:135-139.
68. Frechet P. Scalp extension. In: Unger WP, ed. *Hair Transplantation*. 3rd ed. New York, NY: Marcel Dekker; 1995:662-642.
69. Mangubat EA. Scalp reconstruction and repair. *Facial Plast Surg.* 2008;24:428-445.
70. Perez-Meza D, Niedbalski R. Complications in hair restoration surgery. *Oral Maxillofac Surg Clin North Am.* 2009;21:119-148.
71. Vogel JE. Hair restoration complications: an approach to the unnatural-appearing hair transplant. *Facial Plast Surg.* 2008;24:453-461.
72. Cooley J, Vogel J. Loss of the dermal papilla during graft dissection and placement: another cause of x-factor? *Hair Transplant Forum Int.* 1997;7:20-21.
73. Avram MR, Leonard RT Jr, Epstein ES, et al. The current role of laser/light sources in the treatment of male and female pattern hair loss. *J Cosmet Laser Ther.* 2007;9:27-28.
74. Hamblin MR, Demidova TN. Mechanisms of low level light therapy. *Proc Int Soc Opt Eng.* 2006;6140:614001-6140012.
75. Leavitt M, Charles G, Heyman E, et al. HairMax LaserComb laser phototherapy device in the treatment of male androgenetic alopecia: a randomized, double-blind, sham device-controlled, multicentre trial. *Clin Drug Investig.* 2009;29:283-292. ■