

# New Uses for Fillers

Cameron Chesnut, MD; Jennifer Hsiao, MD; Jenny Kim, MD, PhD; David Beynet, MD

The rapid and continuous progression of aesthetic dermatology has fostered advanced techniques using dermal fillers as noninvasive alternatives in an arena that previously was dominated by cosmetic surgery. The safety and properties of available dermal filler formulations have improved. In this article, new and emerging uses for fillers and injection techniques utilized by dermatologists are reviewed including emerging facial applications, use of microcannulas and full-face restoration, chest and breast rejuvenation, correction of atrophy and scarring, and augmentation of the forefoot fat pad.

*Cosmet Dermatol.* 2012;25:176-182.

**A**esthetic dermatology has drastically progressed in recent years, leading to new and effective noninvasive techniques that are disrupting the status quo. Surgical options once were the first consideration for battling the aesthetic aspects of aging, but noninvasive techniques increasingly are filling the role as the first option for cosmetic rejuvenation. Dermal fillers are among the cost-effective, noninvasive, outpatient options offered by dermatologists that can substantially improve the appearance of the aging body. What started as a treatment option for facial rhytides has steadily progressed, leading to advanced techniques that parallel the improved formulations and safety of the fillers used. In this article, we review the emerging and novel uses of dermal fillers as well as the injection techniques utilized by dermatologists.

---

*From the Division of Dermatology, Department of Medicine, David Geffen School of Medicine at the University of California, Los Angeles, and the Department of Dermatology, Veterans Affairs Greater Los Angeles Healthcare System.*

*Drs. Chesnut, Hsiao, and Beynet report no conflicts of interest in relation to this article. Dr. Kim is a consultant for Allergan, Inc, and Medicis Pharmaceutical Corporation. Dr. Kim's spouse also is an employee and stockholder for Allergan, Inc.*

*Correspondence: Cameron Chesnut, MD, UCLA Division of Dermatology, 52-121 CHS, 10833 Le Conte Ave, Los Angeles, CA 90095 (chesnut@mednet.ucla.edu).*

## EMERGING FACIAL APPLICATIONS

With improvements in dermal fillers have come emerging techniques that utilize the unique properties of these products. There has been a creative and continuous evolution in the cosmetic application of fillers to utilize the volumizing properties of these fillers to replace lost subcutaneous tissue caused by atrophy of fat, muscle, and bone. Although initial indications for fillers mainly were in the nasolabial folds and perioral areas, new off-label techniques allow the use of fillers for enhancement of facial cosmesis in the nose, brow, chin, ear lobe, and tear trough.

### Nasal Augmentation

Nasal augmentation with dermal fillers has been growing as an alternative to surgical rhinoplasty for patients who desire a noninvasive method of improving the aesthetic appearance of the nose. Fillers also can be used to correct nasal deformities caused by less than optimal results from cosmetic rhinoplasty or skin cancer surgery. The numerous potential aesthetic defects caused by the complex anatomy of the nose along with our generally astute perception of nasal aesthetics can make nasal augmentation especially challenging. Bray et al<sup>1</sup> described their approach and technique for performing noninvasive nasal augmentation procedures utilizing injection of hyaluronic acid (HA) in the subcutaneous plane just superficial to the perichondrium or periosteum, avoiding any injection superficial to the deep dermis to prevent ischemia caused by arterial embolism. Injection techniques varied from linear threading to serial puncture and fanning, depending on the area


being treated. When treating the combination of a dorsal hump and ptosis of the nasal tip, Bray et al<sup>1</sup> injected at the columella base, supratip area, and nasal root. To correct a saddle deformity near the nasal bridge, Bray et al<sup>1</sup> injected at the nasal root (Figure 1). They also noted the efficacy of injection at the supratip to soften a supratip depression or break.<sup>1</sup> A 2009 study showed pleasing results of nasal bridge deformities treated with calcium hydroxylapatite (CaHA).<sup>2</sup> In a Japanese study, Tanaka et al<sup>3</sup> described the westernization of the Asian nose via elongation of the columella with HA injections between the medial crura and the anterior nasal spine.

Despite the growing practice of nasal augmentation with dermal fillers, it is important to be aware of the potential adverse effects that are associated with these procedures. The risk for various complications may be reduced by having a thorough understanding of the nasal arterial and cartilaginous anatomy as well as practicing a meticulous injection technique. Potential complications also may be prevented with the use of HA fillers because they are reversible with hyaluronidase as opposed to other dermal fillers that are nonreversible. Major complications

associated with dermal fillers include necrosis, either from intra-arterial injection or external arterial compression from overinjection of the nasal tip, osteophyte formation from periosteal injection, and infection of the treatment site.<sup>1</sup> Aspiration prior to injection to check for the return of any blood will help avoid intra-arterial injections. Furthermore, injections in the upper third of the nose should be placed more medially to avoid intra-arterial injection of the dorsal and lateral nasal arteries.<sup>1</sup> Care must be taken not to overinject filler into the nasal tip, especially in patients who have had prior nasal surgery, including cosmetic rhinoplasty, as there already may be compromised vascular supply related to underlying scarring from the surgery.<sup>4</sup>

### Brow Ptosis

With photoaging and the repetitive inferior movement of the orbicularis oculi muscle, the lateral brow fat pad shrinks over time, causing ptosis of the brow and loss of the anterior brow projection.<sup>5</sup> Dermal fillers are excellent options for restoring both the lift and anterior projection of the brow. Carruthers and Carruthers<sup>6</sup> described HA to lift the lateral brow with a push-ahead technique,



**Figure 1.** Saddle deformity of the nasal bridge before treatment (A) and after correction with hyaluronic acid filler injected at the nasal root (B). Photographs courtesy of Christopher T. Ho, MD, Los Angeles, California.

## NEW USES FOR FILLERS

utilizing a bevel up, 27- or 30-gauge needle with a 25° to 45° bend. Hyaluronic acid is injected into the subdermal space starting at the lateral brow cilia and advancing to the palpable supraorbital notch. Care is taken to keep all injections medial to the supraorbital notch to avoid disrupting the supraorbital nerve and vessels. The push-ahead technique allows the HA to dissect through the subdermal plane ahead of the advancing needle, which reduces the risk for bruising caused by the needle tip.<sup>6</sup> A total volume of 0.3 to 0.4 cc is typical, though some authors have reported as much as 2 cc injected on each side at each of 3 visits.<sup>7</sup> Taking time to mold the filler gives the best results with respect to symmetry and the desired anterior projection.<sup>6</sup>

The literature on oculoplastic surgery also endorses the use of HA for volume loss, including postblepharoplasty volume loss. Morley et al<sup>8</sup> treated 27 patients with upper eyelid and brow volume deficiencies. They injected HA in a preperiosteal plane with a serial puncture technique along the entire brow at the superior orbital rim, utilizing an average of 0.4 cc per brow. An improved brow contour was observed in 85% (23/27) of participants, and 96% (26/27) of participants reported that they were satisfied with the results; however, the authors noted that HA did not obviate the need for surgical intervention in patients with volume loss in the subbrow region, leading to upper eyelid hooding.<sup>8</sup>

A recently described technique termed the *tower technique* is purported to be especially effective in the lateral brow region. A variation of the depot and layering techniques, *towering* is described as the perpendicular injection of HA into the deep soft tissue with gradual tapering as the needle is withdrawn to create struts to support the overlying soft tissue.<sup>9</sup>

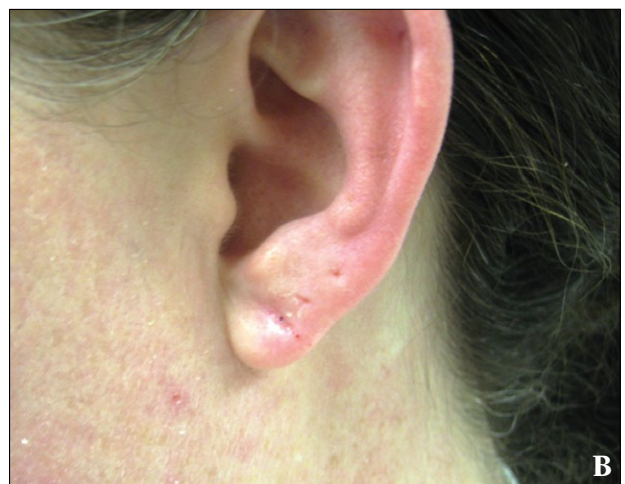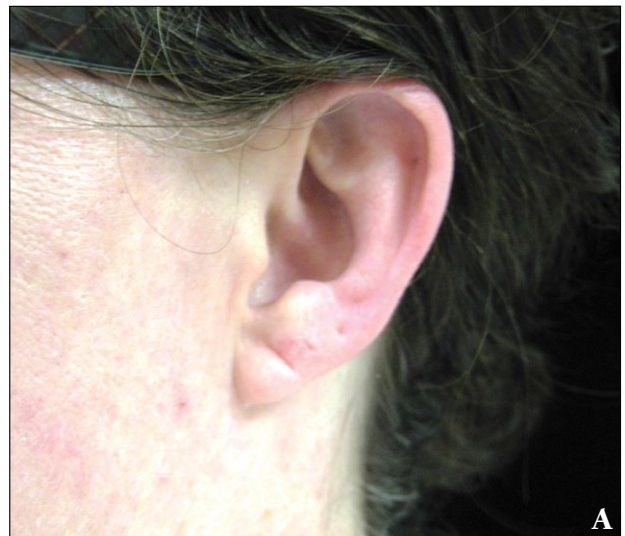### Hollow Chin

Volume loss in the chin (mentum) alters the oval outline of the jawline and face when viewed anteriorly.<sup>7</sup> Loss of anterior projection also causes alteration in the profile view, especially when contrasted against a projecting lower lip. The chin's dense fibrous tissue creates naturally occurring pockets that make this area especially well-suited for volumization and rejuvenation.<sup>10</sup> Subdermal injections superior and lateral to the protrusion of the chin in volumes of 0.2 to 0.4 cc<sup>6</sup> can utilize these naturally occurring pockets to restore the chin's natural projection.

### Ear Lobe Rejuvenation

Ear lobe aesthetics are affected by both volume and the free-margin length of the lobe.<sup>11</sup> Volume loss in the ear lobe occurs with time, and ptosis can occur secondary

to wearing earrings or as a result of minor lobe alterations from a surgical face-lift.<sup>12</sup> Dermal fillers provide an excellent option for restoring volume loss and correcting ptosis in the ear lobe (Figure 2). Although it has not been discussed often, a simple technique utilizing HA and larger-gauge needles has previously been described in the literature.<sup>13</sup> This technique takes advantage of the simple anatomy of the ear lobe and utilizes the decreased resistance of a larger-gauge needle to increase the ease and speed of volume restoration in the tight lobe. The injection of the filler can be administered using a serial puncture method with just 2 to 3 injections with deposition of the filler starting at the inferior area of the ear lobe and injection of less volume while moving superiorly to create a gradual taper of the ear lobe.<sup>13</sup>



**Figure 2.** Ear lobe volume loss and crease before (A) and after hyaluronic acid filler injection (B).

### Tear Trough Deformity

The tear trough deformity is a depression extending from the medial canthus to approximately the midpupillary line and is caused by the loss of subcutaneous fat as well as the descent of the malar fat pad. The tear trough deformity along with the infraorbital hollow, which is another depression that lies just beneath the lower eyelid margin and above the tear trough deformity, creates a “double bubble” contour that interrupts the smooth transition from the lower lid to the cheek. Filler injection along the tear trough deformity, posterior to the orbicularis oculi muscle and anterior to the thickened orbital septum (arcus marginalis), which abuts the periosteum, can restore this contour.<sup>6</sup> With the thin overlying epidermis and soft tissue, extra care should be taken to avoid superficial injections and to massage the treatment area after injection.

### USE OF MICROCANNULAS AND FULL-FACE RESTORATION

The first published report of using microcannulas instead of needles to inject dermal fillers was in 2009.<sup>14</sup> For HA injection, the author described using a blunt 5-cm, 20-gauge (0.9-mm), fat-injection cannula with a Luer-Lok instead of the standard 0.5-in, 28- or 30-gauge needles. The author noted that the blunt cannulas allowed for the injection of an entire lip or nasolabial fold through one puncture site. Other noted benefits included less plunger pressure, pain, edema, and bruising. The single entry point was created with an 18-gauge needle, and the filler was injected into the nasolabial fold or lip using a linear threading motion in either a retrograde or an antegrade fashion. The author noted that the cannula was ideal for treating deeper folds, lips, and other areas that required deep injections at high volumes; however, the traditional needle was more adept to intradermal or more superficial injections, as the cannula cannot navigate intradermally or reliably in superficial planes. It also was advised that the injector pinch the initial 18-gauge puncture site and massage away from the site when homogenizing the filler to prevent extrusion through the puncture site.<sup>14</sup>

A presentation by Salti<sup>15</sup> at the 2011 American Society for Dermatologic Surgery (ASDS) annual meeting also described the use of microcannulas to inject large amounts of HA gel to achieve full face–lifting and volume restoration. The author injected a total of 66 patients to address volume loss, not wrinkles. Each patient received an average of 8 cc of HA filler total over the course of 2 to 3 sessions, each 30 days apart. The author’s injection technique utilized special microcannulas and resembled fat transfer. This technique addressed volume deflation in the midface, periorbital area, and jawline, with the ultimate

end point of obtaining a nonsurgical lifting effect. Sixty-three of 66 (95%) patients had satisfactory results; there were no serious adverse events, but 2 cases of notable long-term swelling and 1 infection were managed without long-term sequelae. The author also concluded that the use of microcannulas helped to reduce the trauma associated with needles, and thus allowed larger total injection volumes to achieve a more realistic lifting effect.<sup>15</sup>

Also at the 2011 ASDS meeting, Goodman et al<sup>16</sup> presented an 18-month, long-term, observational study that examined the safety and efficacy of midface volume deficit correction with HA after 104 weeks. The study demonstrated excellent efficacy, long-term durability, and safety over the 18-month follow-up period, with 95% (98/103) of participants reporting that they were satisfied or very satisfied and willing to recommend the treatment to others. The authors noted some mild to moderate injection site reactions that resolved over time without consequence. None of the participants experienced any substantial adverse events.<sup>16</sup>

### CHEST AND BREAST REJUVENATION

Poly-L-lactic acid (PLLA) was first approved by the US Food and Drug Administration for human immunodeficiency–related lipoatrophy in 2004. Since then, it has demonstrated efficacy and has been widely accepted for use in the correction of facial rhytides and contour deficiencies, an indication that was approved by the US Food and Drug Administration in 2009; however, its uses in other body sites are off label and infrequently reported.<sup>17</sup> The treatment of chest rhytides with PLLA was recently described in a retrospective study by Fabi et al<sup>18</sup> at the ASDS annual meeting in Washington, DC. Currently, all measures of wrinkle severity described in the literature are based on facial wrinkles; thus, to more objectively assess wrinkle severity in the chest area, the authors developed a validated 5-point wrinkle scale to specifically evaluate chest rhytides called the Fabi-Bolton 5-point chest wrinkle scale. Chest rhytides that were rated with Fabi-Bolton scores greater than 3 were considered moderate to severe and these patients were considered candidates for PLLA injection. Data were collected from a total of 28 female patients. The PLLA injection technique in the décolletage was similar in all patients, starting with the most inferomedial rhytides and progressing both superiorly and laterally to treat all visible rhytides and areas of shallowing. A 16-cc total dilution consisting of 14 cc bacteriostatic water and 2 cc lidocaine added to a single vial of PLLA was used in the majority of patients. No topical or regional anesthetic was used. The patients received an average of 2.2 treatments with an average total of 40.5 cc of diluted PLLA over the

course of treatment. The authors noted an improvement in rhytides, texture, contour, and laxity of chest skin that amassed to an average of 1 to 2 points in improvement on the Fabi-Bolton scale. Patients who demonstrated the most improvement received at least 3 PLLA injections at a 16-cc dilution with 16 cc injected per treatment. No adverse events, including nodule formation, were reported during the 6-month study period. The authors did not formally evaluate the subjective satisfaction of their patients in this study.<sup>18</sup>

In 2009, Mazzuco and Hexsel<sup>19</sup> published the first study addressing the use of PLLA to treat the aging chest and neck. The authors treated 36 patients with wrinkles, atrophy, and flaccidity of the chest and neck region using diluted PLLA. One vial (150 mg) of PLLA was diluted with 10 cc of sterile water, and 0.1 cc of lidocaine 2% was added to each 0.9 cc of diluted PLLA prior to injection. Evaluation included preprocedural and postprocedural photographs of the treatment sites in addition to patient satisfaction assessment. Only 21 of 36 (58%) patients who were treated demonstrated visible alterations in preprocedure photographs and were included in the analysis; the photographic analysis revealed that 81% to 100% of these 21 patients improved. Patient satisfaction in all 36 patients also was evaluated and 91.6% (33/36) reported that they were satisfied with the results and would undergo the procedure again. Eighteen-month follow-up revealed maintained results; 1 of 36 (3%) patients had the complication of visible subcutaneous nodule formation, which likely was a reflection of the skin qualities at the injection site.<sup>19</sup>

The formation of nodules at the injection site most commonly occurs in the hands and other areas of thin skin and is the most common adverse effect of PLLA, though the nodules usually are not visible.<sup>20</sup> Practitioners should consider this effect when applying their knowledge of injection techniques from other body sites to the chest. Peterson and Goldman<sup>17</sup> described their techniques for avoiding nodule formation resulting from PLLA injections in the chest. They advocated using a 16-cc dilution and reconstituting the PLLA overnight. Patients were instructed to massage vigorously after injection, following the "5-5-5" rule (5 minutes of massage, 5 times per day for 5 days). Using this method, overcorrection and excessive quantities of PLLA were avoided by administering injections over a period of 3 to 4 treatments set no less than 4 weeks apart.<sup>17</sup>

Poly-L-lactic acid also has been used to correct chest defects unrelated to aging and rhytides. Vleggaar<sup>21</sup> treated a 33-year-old woman with pectus excavatum over the course of 3 injections set 1 month apart using a dilution of 1 vial (150 mg) of PLLA that was reconstituted with 5 cc of saline. Schulman et al<sup>22</sup> also reported using PLLA

to correct a persistent "step-off" deformity and conspicuous intercostal spaces following a mastectomy and reconstruction with breast implants in a 63-year-old woman. The use of acellular cadaveric dermis previously had failed to improve the appearance of the patient's chest wall. The PLLA was injected into the subcutaneous and deep dermal layers of the chest wall over the course of 4 treatments at 1-month intervals. Two vials (150 mg each) of PLLA, each reconstituted with 5.5 cc of bacteriostatic saline, were injected at each session utilizing a macrodroplet technique of 0.6 cc per injection site. The step-off deformity improved and was maintained throughout the 9-month follow-up period following the patient's final injection.<sup>22</sup>

In addition to PLLA, Peterson and Goldman<sup>17</sup> reported the use of HA for correction of chest rhytides. With a 1:4 dilution of HA in saline, a threading technique can be used to inject a total of 2 to 3 cc of HA. Again, the authors advocated that correction should be spread out over multiple treatments totaling 6 to 8 months with HA.<sup>17</sup> Dermal fillers also have been used in the correction of aesthetic problems in the male breast, such as chest asymmetry treatment and body sculpturing.<sup>23</sup>

Nipple contouring after mastectomy using HA was described by Lennox and Beer<sup>24</sup> in 2007 and elaborated on a prior description of the technique by Panettiere et al.<sup>25</sup> Panettiere et al<sup>25</sup> noted that the chief concern from patients regarding the nipple-areola complex postmastectomy was a lack of projection. The authors injected 90 nipples in 70 patients who had reconstructed nipples after mastectomy for breast cancer. Nipples were reconstructed either with a labia minora wedge or via nipple sharing and were initially injected 2 months after reconstruction. The authors used a semipermanent filler consisting of hydroxyethyl methacrylate and ethyl methacrylate in an HA suspension in volumes dependent on the desired projection. A second injection 2 months after the first was performed in all patients, and 66 nipples were injected a third time 3 months later, with an average overall volume of 0.5 cc per nipple. With a contralateral unaffected nipple, injected volumes were intended to match that nipple with no more than 10% overprojection. Injection technique involved a primary injection directly into the reconstructed nipple and a second separate injection at the base of the reconstruction with a 27.5-gauge needle. They achieved excellent results with nearly ideal nipple projections of 5.4 and 5.2 mm at 6 and 12 months, respectively, and a large majority of nipples measured within 1 mm of the contralateral unaffected nipple. This technique proved to be more accurate and adjustable and achieved better results than other techniques reported in the literature. It also was notable that reconstructions

using a wedge from the labia minora responded better than those reconstructed with nipple sharing.<sup>25</sup>

## CORRECTION OF ATROPHY AND SCARRING

Hyaluronic acid has been gaining steam within cosmetic dermatology as another treatment option for atrophy and scarring since the 2008 case series that reported the use of HA filler to treat depressed scars after Mohs micrographic surgery with excellent cosmetic results.<sup>26</sup> Since then, the application of fillers to other varieties of atrophy and scarring has been expanding. In 2010, Elliott et al<sup>27</sup> published the first report of HA filler use in the treatment of steroid atrophy. The authors treated a 32×8-mm atrophic defect that was 6 mm in depth with 2 cc of HA by injecting into the peripheral edge of the defect and massaging the filler into place. There were no complications, and the area continued to gain volume and reached its original size after 3 months of continued follow-up.<sup>27</sup>

A 2011 study by Choksi and Orringer<sup>28</sup> and a presentation by Cruz and Dufresne<sup>29</sup> at the 2011 ASDS meeting described the use of HA to treat the *en coup de sabre* atrophy pattern of linear morphea. To correct the forehead defect, Choksi and Orringer<sup>28</sup> utilized a linear threading technique after local anesthesia with lidocaine 1% to inject a total of 1 cc of HA initially and an additional 1 cc 5 months later. The authors estimated a greater than 90% improvement in the original atrophic defect, and the patient was satisfied with the results.<sup>28</sup> Cruz and Dufresne<sup>29</sup> found similar and favorable cosmetic results in a patient who received 2 separate injections of HA administered 4 months apart. In addition to the depressed forehead defect, the patient had an ipsilateral perioral depression that also was treated with HA. Results were favorable with a restored natural contour and no reported complications.<sup>29</sup> With current treatment options for *en coup de sabre* mainly consisting of surgical excision and repair, autologous fat transfer, and bone grafting, HA fillers provide a much less invasive and possibly more cosmetically favorable treatment option.

Goldberg et al<sup>30</sup> examined the use of CaHA for the treatment of atrophic acne scars in a prospective trial of 10 patients. The authors injected into the mid to deep dermis to treat both ice-pick and saucerized atrophic acne scars utilizing 0.1 to 0.3 cc of CaHA. Three of 10 patients subsequently received a second treatment 1 month after the initial injection. Patients were followed for a total of 12 months. The authors found that saucerized acne scars responded well to treatment, while ice-pick scars showed no improvement. Some degree of improvement was observed in the saucerized scars throughout the entire 12-month follow-up period.<sup>30</sup> In another study, Sage et al<sup>31</sup>

found that atrophic and rolling acne scars responded to a collagen dermal filler. In their prospective, randomized, single-blinded, split-faced study, the authors compared subcuticular incision to collagen filler. Both treatments produced positive results, and no difference was noted by blinded physician evaluators; however, patients rated subcuticular incision as superior to treatment with collagen filler at 3- and 6-month follow-ups.<sup>31</sup>

Cooper and Lee<sup>32</sup> addressed the different filler options and techniques available when attempting to treat atrophic facial scarring. The authors noted that when administering HA they preferred to use the linear threading technique in the perioral area and the fanning technique when treating larger scar areas. For deep contracted scars in the periocular and perioral regions, their filler of choice was CaHA. When administering CaHA, the authors aimed for injection into the supraperiosteal plane to avoid superficial dermal injections.<sup>32</sup>

## AUGMENTATION OF FOREFOOT FAT PAD

A simple search of the Internet will provide a multitude of Web sites and mainstream media publications advocating the use of dermal fillers for augmentation of the forefoot fat pad. Women who wear high heels, patients with metatarsalgia, or even patients with diabetic foot ulcers may desire such augmentation. In 2010, a group of foot and ankle surgeons published a report that described a woman who failed treatment with dermal collagen injections for metatarsalgia and reviewed the evidence of its efficacy.<sup>33</sup> The authors of this report did not find any peer-reviewed articles documenting the use of collagen injections to the forefoot<sup>33</sup>; a literature review we performed utilizing PubMed for articles indexed for MEDLINE using the search terms *filler*, *forefront*, and *metatarsalgia* also did not produce articles regarding collagen or newer dermal fillers used for forefoot injection. Injectable silicone has been used in the foot for more than 40 years and has been reported to be safe and effective, but its use and potential adverse reactions have been and continue to be controversial.<sup>34,35</sup>

## CONCLUSION

Rapid advancements in cosmetic science and the development of safe and effective dermal fillers have provided dermatologists with the armamentarium needed to offer rejuvenation options that extend far beyond the traditional uses of fillers. The improved properties of today's fillers allow for volumizing and lifting treatments that serve as noninvasive rejuvenation options in an arena traditionally dominated by cosmetic surgery. Although the emerging uses and injection techniques for fillers reviewed in this article are innovative and exciting, it is

important to keep in perspective that most of the studies described have not been supported by evidence-based medicine. To date, few randomized, controlled, and blinded studies for off-label use of dermal fillers have been performed, and such studies are needed to ensure the safety and efficacy of new filler applications.

REFERENCES

1. Bray D, Hopkins C, Roberts DN. Injection rhinoplasty: non-surgical nasal augmentation and correction of post-rhinoplasty contour asymmetries with hyaluronic acid: how we do it. *Clin Otolaryngol.* 2010;35:227-230.
2. Siclovan HR, Jomah JA. Injectable calcium hydroxylapatite for correction of nasal bridge deformities [published online ahead of print December 9, 2008]. *Aesthetic Plast Surg.* 2009;33:544-548.
3. Tanaka Y, Matsuo K, Yuzuriha S. Westernization of the Asian nose by augmentation of the repositioned anterior nasal spine with an injectable filler. *Eplasty.* 2011;11:e7.
4. Grunebaum LD, Bogdan Allemann I, Dayan S, et al. The risk of alar necrosis associated with dermal filler injection. *Dermatol Surg.* 2009;35(suppl 2):1635-1640.
5. Knize DM. An anatomically based study of the mechanism of eyebrow ptosis. *Plast Reconstr Surg.* 1996;97:1321-1333.
6. Carruthers JD, Carruthers A. Facial sculpting and tissue augmentation. *Dermatol Surg.* 2005;31(11, pt 2):1604-1612.
7. Andre P. New trends in face rejuvenation by hyaluronic acid injections. *J Cosmet Dermatol.* 2008;7:251-258.
8. Morley AM, Taban M, Malhotra R, et al. Use of hyaluronic acid gel for upper eyelid filling and contouring. *Ophthal Plast Reconstr Surg.* 2009;25:440-444.
9. Bartus CL, Sattler G, Hanke CW. The tower technique: a novel technique for the injection of hyaluronic acid fillers. *J Drugs Dermatol.* 2011;10:1277-1280.
10. Belmontesi M, Grover R, Verpaele A. Transdermal injection of Restylane SubQ for aesthetic contouring of the cheeks, chin, and mandible. *Aesthet Surg J.* 2006;26(15):S28-S34.
11. Mowlavi A, Meldrum DG, Wilhelmi BJ, et al. The aesthetic ear lobe: classification of lobule ptosis on the basis of a survey of North American Caucasians. *Plast Reconstr Surg.* 2003;112:266-272; discussion 273-274.
12. Mowlavi A, Meldrum DG, Wilhelmi BJ, et al. Effect of face lift on ear lobe ptosis and pseudoptosis. *Plast Reconstr Surg.* 2004;114:988-991.
13. de Oliveira Monteiro E. Hyaluronic acid for restoring ear lobe volume. *Skinmed.* 2006;5:293-294.
14. Niamtu J 3rd. Filler injection with micro-cannula instead of needles. *Dermatol Surg.* 2009;35:2005-2008.
15. Salti G. Full face soft restoration with hyaluronic acid gel fillers and microcannulas. Abstract presented at: American Society for Dermatologic Surgery Annual Meeting; November 3-6, 2011; Washington, DC.
16. Goodman GJ, Goodman G, Carlisle I, et al. A prospective, long-term observational study of the efficacy & safety of an hyaluronic acid (HA) filler in the correction of mild to severe mid-face volume deficits: 18 month interim analysis. Abstract presented at: American Society for Dermatologic Surgery Annual Meeting; November 3-6, 2011; Washington, DC.

17. Peterson JD, Goldman MP. Rejuvenation of the aging chest: a review and our experience [published online ahead of print April 4, 2011]. *Dermatol Surg.* 2011;37:555-571.
18. Fabi SG, Bolton J, Peterson J, et al. Poly-L-lactic acid for chest rejuvenation: a retrospective study of 28 cases using a 5-point chest wrinkle scale. Abstract presented at: American Society for Dermatologic Surgery Annual Meeting; November 3-6, 2011; Washington, DC.
19. Mazzucco R, Hexsel D. Poly-L-lactic acid for neck and chest rejuvenation [published online ahead of print May 12, 2009]. *Dermatol Surg.* 2009;35:1228-1237.
20. Palm MD, Woodhall KE, Butterwick KJ, et al. Cosmetic use of poly-L-lactic acid: a retrospective study of 130 patients [published online ahead of print December 21, 2009]. *Dermatol Surg.* 2010;36:161-170.
21. Vleggaar D. Soft-tissue augmentation and the role of poly-L-lactic acid. *Plast Reconstr Surg.* 2006;118(suppl 3):46S-54S.
22. Schulman MR, Lipper J, Skolnik RA. Correction of chest wall deformity after implant-based breast reconstruction using poly-L-lactic acid (Sculptra). *Breast J.* 2008;14:92-96.
23. Wollina U, Goldman A. Minimally invasive esthetic procedures of the male breast. *J Cosmet Dermatol.* 2011;10:150-155.
24. Lennox K, Beer KR. Nipple contouring with hyaluronics postmastectomy. *J Drugs Dermatol.* 2007;6:1030-1033.
25. Panettiere P, Marchetti L, Accorsi D. Filler injection enhances the projection of the reconstructed nipple: an original easy technique. *Aesthetic Plast Surg.* 2005;29:287-294.
26. Kasper DA, Cohen JL, Saxena A, et al. Fillers for postsurgical depressed scars after skin cancer reconstruction. *J Drugs Dermatol.* 2008;7:486-487.
27. Elliott L, Rashid RM, Colome M. Hyaluronic acid filler for steroid atrophy. *J Cosmet Dermatol.* 2010;9:253-255.
28. Choksi AN, Orringer JS. Linear morphea-induced atrophy treated with hyaluronic acid filler injections. *Dermatol Surg.* 2011;37:880-883.
29. Cruz A, Dufresne R. A novel use of dermal fillers for linear morphea associated "en coup de sabre" and hemifacial atrophy. Poster presented at: American Society for Dermatologic Surgery Annual Meeting; November 3-6, 2011; Washington, DC.
30. Goldberg DJ, Amin S, Hussain M. Acne scar correction using calcium hydroxylapatite in a carrier-based gel. *J Cosmet Laser Ther.* 2006;8:134-136.
31. Sage RJ, Lopiccolo MC, Liu A, et al. Subcuticular incision versus naturally sourced porcine collagen filler for acne scars: a randomized split-face comparison [published online ahead of print March 9, 2011]. *Dermatol Surg.* 2011;37:426-431.
32. Cooper JS, Lee BT. Treatment of facial scarring: lasers, filler, and nonoperative techniques [published online ahead of print December 18, 2009]. *Facial Plast Surg.* 2009;25:311-315.
33. Dhinsa BS, Bowman N, Morar Y, et al. The use of collagen injections in the treatment of metatarsalgia: a case report [published online ahead of print September 18, 2010]. *J Foot Ankle Surg.* 2010;49:565.e5-565.e7.
34. Balkin SW. Injectable silicone and the foot: a 41-year clinical and histologic history. *Dermatol Surg.* 2005;31(11, pt 2):1555-1559; discussion 1560.
35. Bowling FL, Metcalfe SA, Wu S, et al. Liquid silicone to mitigate plantar pedal pressure: a literature review. *J Diabetes Sci Technol.* 2010;4:846-852. ■