

# Page Kidney Successfully Treated With Intrarenal Artery Embolization

Jorge Lamarche, MD; Alfredo Peguero, MD; and Craig Courville, MD

Based on the frail health of an elderly male patient, physicians initially cautioned against using invasive procedures to manage his renal compression, but later decided to perform intrarenal artery embolization after noninvasive treatment did not produce the needed results.

**E**xternal compression of the kidney is known as Page kidney.<sup>1</sup> Compression of the renal parenchyma clinically manifests as new-onset high blood pressure (BP) or less commonly as acute renal failure as originally described and demonstrated by Dr. Irwin Page in human case reports and animal models, respectively.<sup>2</sup> The condition usually occurs by a subcapsular hematoma caused by a traumatic or iatrogenic event. Management of Page kidney has evolved over the last 5 to 6 decades since its initial description in an American football player in 1955. Initially, as in the example just mentioned, its management consisted of radical nephrectomy. Other techniques followed, such as open surgery to evacuate the hematoma.<sup>3</sup> Later, procedures such as radiology-assisted and laparoscopic-assisted drainage of hematoma were performed.<sup>1</sup> Last, in cases with no evidence of acute renal injury, medical management with antihypertensive agents, typically including the use of angiotension-converting-enzyme (ACE) inhibitors and angiotensin receptor blockers (ARBs) along with observation of the hemoglobin (Hb) levels, has become the

standard of care.

The choice of therapy depends on the clinical presentation of each case. In cases with acute renal injury involving a renal allograft or a native solitary functioning kidney, open surgical hematoma evacuation or percutaneous drainage is performed to restore renal function.<sup>1,4</sup> Whereas, in cases where high BP is the main pathophysiologic manifestation, medical therapy with BP-lowering medications and observation typically suffice. The following case presentation demonstrates the successful management of acute renal failure caused by Page kidney via coil embolization of a distal intrarenal artery aneurysm, which developed after a native renal biopsy. To date, this is the first reported successful use of this intervention for the management of Page kidney in an adult patient.

## CASE REPORT

A 75-year-old white male with a medical history of stable chronic kidney disease (CKD), hypertension (HTN), and diabetes mellitus was admitted to the hospital for an elective computed tomography (CT)-guided renal biopsy. The patient's renal function had been stable with an estimated glomerular filtration rate (e-GFR) of 45 mL/min for years. His CKD was thought to be secondary to his long-

standing history of HTN. The rationale for the biopsy was that 6 months before the date of the biopsy, he was found to have developed a new-onset nephrotic range proteinuria. Subsequently, the patient also began to have a progressive decline in his e-GFR. At the time of the biopsy, his e-GFR was 35 mL/min, his BP was 136/74 mm Hg, and he has been advised not to take any anticoagulant medications for at least 7 days. His preprocedural Hb was 9.9 g/dL.

The CT-guided biopsy was performed after informed consent was obtained. The patient was placed in the CT gantry in the prone position. A noncontrast CT image of the lower poles of both kidneys was obtained. The lower pole of the left kidney was chosen. The patient's left back was sterilized with an iodine solution. A xylocaine solution of 1% was used for local anesthesia and 12.5 mcg of fentanyl was administered intravenously for sedation. Under CT guidance, a 17-gauge introducer needle was advanced to the cortex of the lower pole of the left kidney. After confirmation of the introducer needle location, two 18-gauge core biopsy specimens were obtained.

After the biopsy, a hemostatic agent was injected along the biopsy tract. A postbiopsy CT image revealed fullness within the left lower pole at

**Dr. Lamarche, Dr. Peguero, and Dr. Courville** are nephrologists at the James A. Haley Veterans' Hospital in Tampa, Florida, and are professors at the University of South Florida in Tampa, Florida.

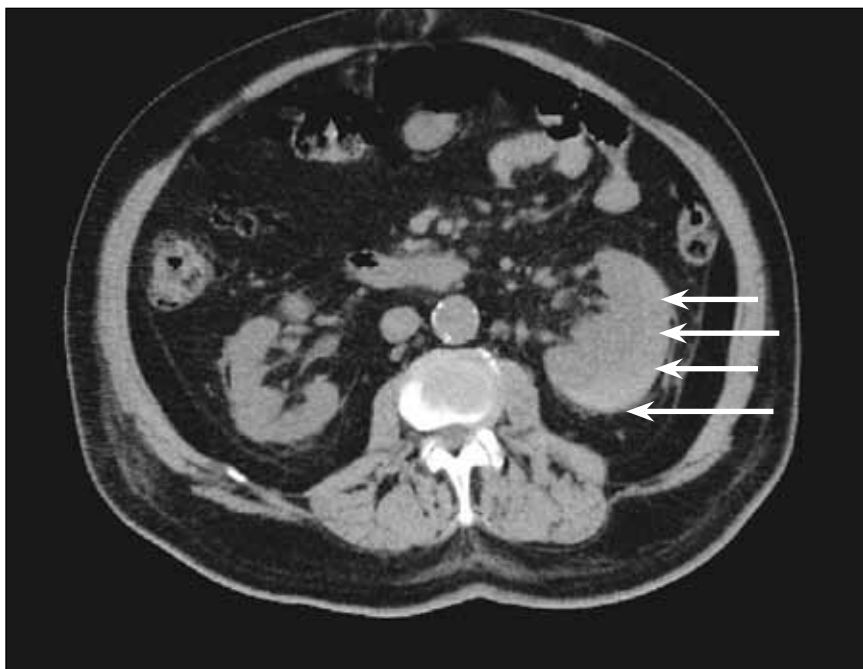

Figure 1. Noncontrast computed tomography slice of the abdomen. The white arrows indicate the area of the subcapsular hematoma as a high-attenuation mass.

the biopsy site, which represented an intrarenal hematoma along with the hemostatic agent. There was no visual evidence of a perinephric hematoma. The patient was then admitted to the hospital for a 23-hour observation period. Immediately following the procedure, he was placed in the supine position with strict bed rest for 6 hours. Vital signs were monitored every 30 minutes for the first 4 hours and, if stable, then every 4 hours. Complete blood cell counts (CBCs) were ordered for 6 hours and 20 hours after the procedure.

Within 3 hours after the procedure, the patient's BP rose to 167/73 mm Hg. The patient did not report feeling pain and did not seem to be in any distress. The first post-biopsy CBC revealed a stable Hb of 10.1 g/dL. For the next 24 hours the patient was completely asymptomatic, but the BP readings were in the range of 167 mm Hg to 194/70 mm Hg. The next CBC, which was 20

hours postprocedure, revealed an Hb value of 9.8 g/dL. There were also no episodes of macroscopic hematuria throughout the observation period. The patient's expected discharge was delayed, however, as the serum creatinine (SCr) rose from his baseline of 1.9 mg/dL to 2.8 mg/dL.

Results from a bladder scan, performed to check a postvoid residual, were normal. Despite intensive medical therapy, the BP was difficult to manage. The next day a CBC revealed a decrease in Hb to 8.6 g/dL. At the same time, the SCr continued to rise. At this point a noncontrast CT scan of the abdomen and pelvis was performed (Figure 1). A renal subcapsular hematoma was found. A clinical diagnosis of Page kidney was made as the patient had a new-onset difficult-to-control high BP and acute renal failure associated with the onset of the hematoma.

The patient was initially treated medically with antihypertensive

medications and blood transfusions. Despite 9 days of medical therapy, the patient's renal function continued to deteriorate and his SCr had risen to 4.8 mg/dL. In addition, he required several packed red blood cell (RBC) transfusions during this time. As medical therapy failed, a decision was made to evacuate the hematoma. However, with the concern that the hematoma may have organized during the observation period, the decision was to undergo selective angiogram of the left renal artery as an attempt to embolize the bleeding vessel. Thus, the patient underwent a selective left renal artery angiogram with successful coil embolization of an aneurysm located at the distal inferior polar left renal artery (Figure 2).

The patient was discharged 2 days after the procedure when his Hb had stabilized and the renal function began to show signs of improvement. A noncontrast CT scan repeated 12 weeks later showed a near complete resolution of the hematoma. At this time his SCr had decreased to 2.6 mg/dL. The renal biopsy showed a picture of idiopathic focal and segmental glomerulosclerosis (FSGS). His renal function did not completely return to baseline, possibly owing to a permanent parenchymal injury after the Page kidney and progression of his FSGS.

## DISCUSSION

Page kidney is the external compression of a kidney. Anatomically, the kidney is a poorly protected retroperitoneal organ. The organ is surrounded by 2 envelopes. The first is the Gerota's fascia, which is a large space, and a large hematoma in this space would be needed to compress the kidney. The second is the kidney capsule. The capsule provides only a small potential space in which a small amount of blood suffices to

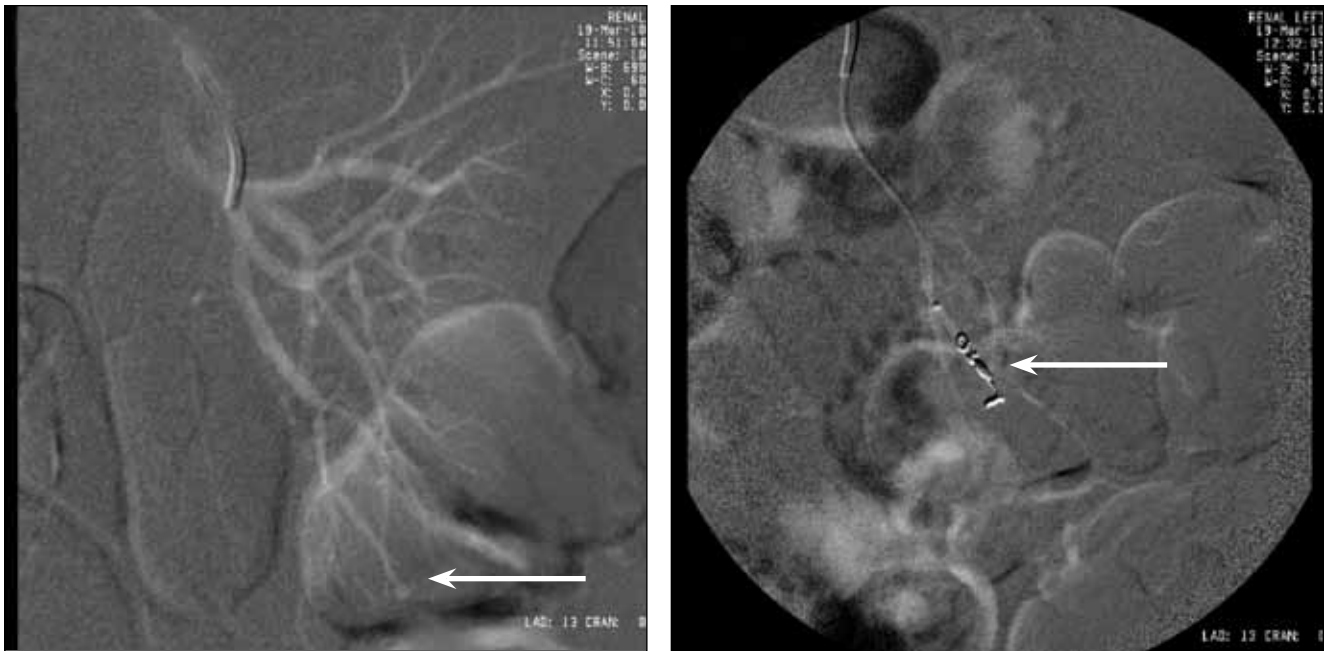

Figure 2. (Left) Selective left renal artery angiography. The white arrow indicates the aneurysm of the distal inferior polar left renal artery. This aneurysm developed as a consequence of the renal biopsy resulting in hemorrhage within the renal capsule. (Right) Selective left renal artery angiography. The white arrow indicates the coil after deployment resulting in embolization of the distal arterial segment and aneurysm.

cause compression. Compression of the parenchyma may lead to high BP and renal injury. Subcapsular hematoma most commonly occurs after renal biopsy or extracorporeal shock wave lithotripsy.<sup>2</sup> Subcapsular bleeding also occurs secondary to trauma or surgery. Spontaneous bleeding has also been reported in patients on warfarin therapy, renal tumors, or from polyarteritis nodosa.<sup>5</sup> Increased mass effect on the renal parenchyma has also resulted from lymphoceles, cysts, urinomas, and retroperitoneal paragangliomas.

A clinical scenario with the adequate imaging modality demonstrating a mass effect on the renal parenchyma in a patient with new-onset high BP and renal insufficiency provides a strong clinical ground to diagnose Page kidney. Although there are no specific guidelines for the management of Page kidney in the literature, the aim of therapy is to

treat the high BP and to expeditiously relieve the compression if renal injury is occurring. If HTN, which is theorized by Goldblatt and colleagues to be caused by renal ischemia as a consequence of renal arterial tree compression, is the major clinical manifestation without renal failure, then medical management with anti-hypertensive agents and observation of the Hb levels are sufficient.<sup>6</sup> External compression of the parenchyma in Page kidney causes renal ischemia and subsequent renin-induced HTN. The use of ACE inhibitors or ARBs has been advocated to be part of the drug regimen included in cases of medical management.<sup>7</sup> If renal function declines, most reports in the literature strongly advocate that prompt relief of the external compression within 24 to 72 hours after the diagnosis of Page kidney leads to successful restoration of renal function.<sup>2,8-10</sup>

Renal insufficiency is typically

not present in reported cases of Page kidney. If the contralateral kidney is normal, renal function remains stable, and high BP is the main clinical manifestation.<sup>4</sup> However, in cases of renal allograft or a solitary native functioning kidney, renal insufficiency may occur. In this case report, the patient had been experiencing progressive decline of his renal function perhaps caused by the newly diagnosed FSGS. In addition, the patient already had stage III CKD presumably from HTN nephrosclerosis. Therefore, the patient likely developed acute renal failure as the contralateral kidney already had architectural damage from long-standing HTN and FSGS. If renal failure occurs, prompt decompression must be attempted to preserve function as much as possible.

A multitude of decompressing procedures have been described in the past, including open surgical hematoma drainage, laparoscopy,

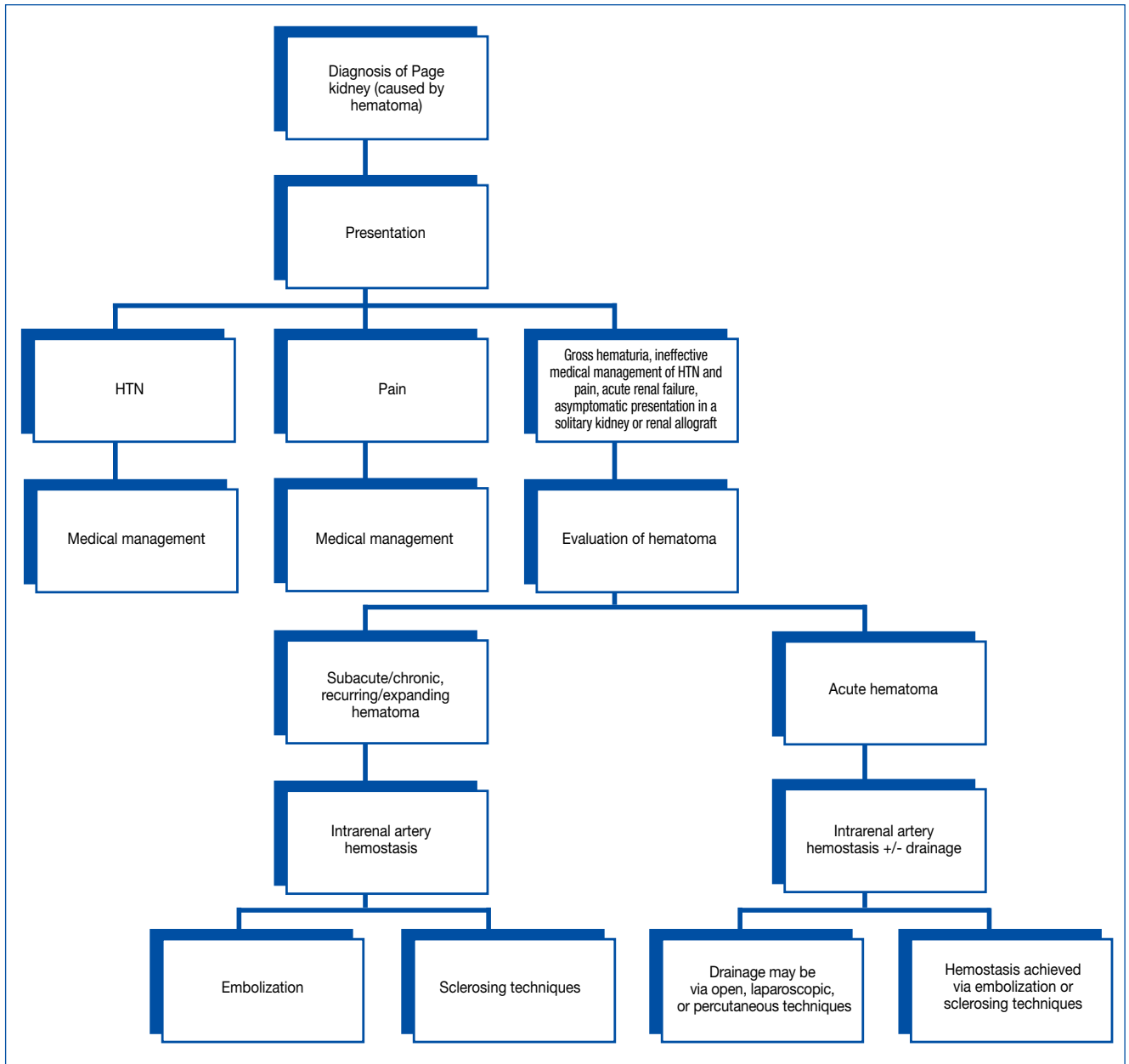


Figure 3. A proposal algorithm of the management of Page kidney caused by subcapsular hematoma, based on the recent review of the literature.

HTN = hypertension.

and radiology-assisted percutaneous hematoma evacuation.<sup>1</sup> Due to the patient's advanced age and medical comorbidities, the initial decision was to manage medically and to avoid an open surgical technique. However, as the renal function continued to de-

teriorate and the Hb kept decreasing despite multiple packed RBC transfusions, invasive management was used. After 9 days of medical observation, there was a strong concern that the hematoma may have begun to organize, making percutaneous drain-

age less feasible.<sup>11,12</sup> Literature from the radiologic field demonstrates that hematomas typically begin to show signs of organization after 7 days.<sup>13</sup> Therefore, a consensus was reached to attempt coil embolization of the injured segment of the renal artery in

order to arrest the hemorrhage. The procedure was successful, and the patient's clinical status was stabilized. Based on the literature reviewed for this article, Figure 3 was constructed as a proposal plan for the management of Page kidney caused by subcapsular hematomas.<sup>1-16</sup>

To date, this is the first reported use of arterial coil embolization as a potential tool to manage Page kidney presumably caused by a subcapsular hematoma in an adult patient. Although decompression would be the faster and preferred method of management in patients having acute renal dysfunction, coil embolization may become a suitable alternative in certain individuals especially if the bleeding is ongoing. Embolization is often less invasive than open or percutaneous drainage while the source of hemorrhage is localized and sealed. According to Rivera and colleagues, selective coil embolization is the treatment of choice as it permits accurate deployment of metallic coils directly into the artery that leads to the hemorrhage while mimimizing the vascular territory at risk for infarction.<sup>14</sup> If performed early, the procedure may also be effective in preventing the progression of Page kidney. In cases of new-onset or difficult-to-control high BP occurring after a renal biopsy sus-

pected to be secondary to compression from a subcapsular hematoma, early hemostasis of the injured renal vessel with coil embolization may obviate the need for subsequent hematoma drainage and prevent ensuing renal injury. ●

**Author disclosures**

*The authors reports no actual or potential conflicts of interest with regard to this article.*

**Disclaimer**

*The opinions expressed herein are those of the authors and do not necessarily reflect those of Federal Practitioner, Quadrant HealthCom Inc., the U.S. Government, or any of its agencies. This article may discuss unlabeled or investigational use of certain drugs. Please review complete prescribing information for specific drugs or drug combinations—including indications, contraindications, warnings, and adverse effects—before administering pharmacologic therapy to patients.*

**REFERENCES**

1. Suckling R, Uddin F, Pilcher J, MacPhee IA, Eastwood JB, Banerjee D. Page kidney: Successful radiological management of acute renal failure. *Nephrol Dial Transplant.* 2006;21(6):1740.
2. Mathew A, Brahmabhatt B, Rajesh R, Kurian G, Unni VN. Page kidney. *Indian J Nephrol.* 2009;19(4):170-171.
3. Dopson SJ, Jayakumar S, Velez JC. Page kidney as a rare cause of hypertension: Case report and review of

- the literature. *Am J Kidney Dis.* 2009;54(2):334-339.
4. Chung J, Caumartin Y, Warren J, Luke PP. Acute Page kidney following renal allograft biopsy: A complication requiring early recognition and treatment. *Am J Transplant.* 2008;8(6):1323-1328.
5. Pintar TJ, Zimmerman S. Hyperreninemic hypertension secondary to a subcapsular perinephric hematoma in a patient with polyarteritis nodosa. *Am J Kidney Dis.* 1998;32(3):503-507.
6. Goldblatt H, Lynch J, Hanzal RF, Summerville WW. Studies on experimental hypertension: I. The production of persistent elevation of systolic blood pressure by means of renal ischemia. *J Exp Med.* 1934;59(3):347-379.
7. Myrianthefs P, Aravosita P, Tokta R, Louizou L, Boutzouka E, Baltopoulos G. Resolution of Page kidney-related hypertension with medical therapy: A case report. *Heart Lung.* 2007;36(5):377-379.
8. Vo NJ, Hanevold CD, Edwards R, Hoffer FA, Koyle MA. Recurrent Page kidney in a child with a congenital solitary kidney requiring capsular artery embolization. *Pediatr Radiol.* 2010;40(11):1837-1840.
9. Maurya KK, Bhat HS, Mathew G, Kumar G. Page kidney following renal allograft biopsy—Early recognition and treatment. *Saudi J Kidney Dis Transpl.* 2011;22(5):1012-1013.
10. Posadas MA, Yang V, Ho B, Omer M, Batlle D. Acute renal failure and severe hypertension from a Page kidney post-transplant biopsy. *ScientificWorldJournal.* 2010;10:1539-1542.
11. Babel N, Sakpal SV, Chamberlain RS. The Page kidney phenomenon secondary to a traumatic fall. *Eur J Emerg Med.* 2010;17(1):24-26.
12. Haydar A, Bakri RS, Prime M, Goldsmith DJ. Page kidney—A review of the literature. *J Nephrol.* 2003;16(3):329-333.
13. Kransdorf MJ, Murphey MD. *Imaging of Soft Tissue Tumors.* 2nd ed. Philadelphia, PA: Lippincott Williams and Wilkins; 2006:544-546.
14. Rivera M, Villacorta J, Jimenez-Alvaro S, Quereda C. Asymptomatic large extracapsular renal pseudoaneurysm following kidney transplant biopsy. *Am J Kidney Dis.* 2011;57(1):175-178.
15. Chiang K-H, Chang P-Y, Liu Y-X, et al. Chronically rejected renal allograft replaced by a huge organized hematoma mimicking malignancy. *Tzu Chi Med J.* 2006;18(3):211-215.
16. Rashid M, Abbas SZ, Haque F, Rizvi SA, Ali WM. Intrarenal post-traumatic pseudoaneurysm-USG colour Doppler diagnosis: A case report with review of literature. *Emerg Radiol.* 2007;14(4):257-260.