

Accuracy and Safety of the Placement of Thoracic and Lumbar Pedicle Screws Using the O-arm Intraoperative Computed Tomography System and Stealth Stereotactic Guidance

Donald A. Ross, MD; and Neil Roundy, MD

In this retrospective review, the authors bring to light the technologic advances that have resulted in 100% acceptable pedicle screw placement in the lumbar spine without the need of the patient's return to the operating room.

Placement of lumbar and thoracic pedicle screws must be performed precisely to avoid nerve root injury, cerebrospinal fluid leak, or inadequate screw fixation leading to dislodgement. Even with extensive experience and careful fluoroscopic guidance, the surgeon will have a percentage of screws violate the cortex, some of which will require revision.¹ Often, the error is not discovered until postoperatively and requires reoperation to correct the problem.² With the advent of intraoperative computed tomography (CT) scanning with the O-arm[®] Surgical Imaging System (O-arm) and the StealthStation[®] surgical navigation system (Medtronic, Inc., Minneapolis, Minnesota), verifying

Dr. Ross is an assistant professor of neurological surgery and **Dr. Roundy** is a chief resident in neurological surgery, both in the Department of Neurological Surgery at the Oregon Health & Science University in Portland. Dr. Ross is also an attending neurosurgeon at the PVAMC in Portland, Oregon.

screw placement on the operating table and correcting the position of any imperfect placement before the end of the procedure is now possible. This review contains the results of consecutive pedicle screw fusions of the thoracic and lumbar spines performed by a single surgeon in the first 18 months since acquisition of the O-arm device at the Portland Veterans Affairs Medical Center (PVAMC).

METHODS

For 1- or 2-level fusions, the following paramedian technique was most often used. For longer constructs, open midline incisions were most often used. After establishment of electromyography (EMG) monitoring of the lower extremities, patients were positioned prone on a Mizuho OSI Jackson Table (Union City, California). All Stealth-guided instrumentation, including probes, pedicle awls, taps, and screwdrivers,

were registered to the Stealth system by the scrub technician. After skin preparation and sterile draping of the patient, if the intended fusion was below the L3 level, the sterilely draped O-arm was used as a fluoroscope to establish the location of the medial aspect of the right iliac crest. With care to avoid the cluneal nerves, a 1-cm skin incision was made, and the guide tube for the Stealth antenna was impacted into the iliac crest with fluoroscopic guidance.³

It was important to angle the guide tube medially and inferiorly so the antenna did not overhang the skin incision on the ipsilateral side or positioned such that the surgeon's hands or instrumentation would obstruct the view of the antenna by the infrared camera. A Jamshidi[®] needle was then passed down the guide tube and used to harvest bone marrow blood used to soak the fusion grafts. The Stealth antenna was then impacted into the iliac crest. Be-

cause the fusion was to be at L3 or above, to keep the antenna close to the working area, the Stealth antenna was attached to an appropriate spinous process through a small midline incision. Anterior, posterior, and lateral fluoroscopic images were then obtained to center the subsequent CT scan on the appropriate anatomy. The surgical team then briefly exited the operating room while a CT scan was obtained, taking 13 or 26 seconds in regular or high-definition mode. The CT was transferred automatically to the StealthStation, and no further registration was required.

A Stealth probe was then used to localize the skin incisions over the midpoints of the transverse processes or sacral alae. For a single-level fusion, a 5-cm incision was made and carried sharply through the lumbarodorsal fascia. Blunt dissection with a finger was used to split the paraspinal muscle fibers longitudinally and palpate the transverse processes, the identities of which were confirmed with the Stealth probe. Dilators from the Minimal Exposure Tubular Retractor (METRx®) System (Medtronic, Inc.) retractor set were then used to place the vertical MAST QUADRANT™ (Medtronic, Inc.) Retractor System. Fiber optic light sources were occasionally attached, but the expense of these disposables resulted in less use of this adjunct. A horizontal retractor was then placed with a blade 2-cm longer on the lateral side at the level of the transverse processes rather than the medial side, which was at the level of the facet. The microscope was brought in to aid the assistant surgeon in seeing into the wound. The transverse processes and lateral facets were denuded of soft tissue. The Stealth probe was used to identify the appropriate screw entry points. A small cutting bur was used to make

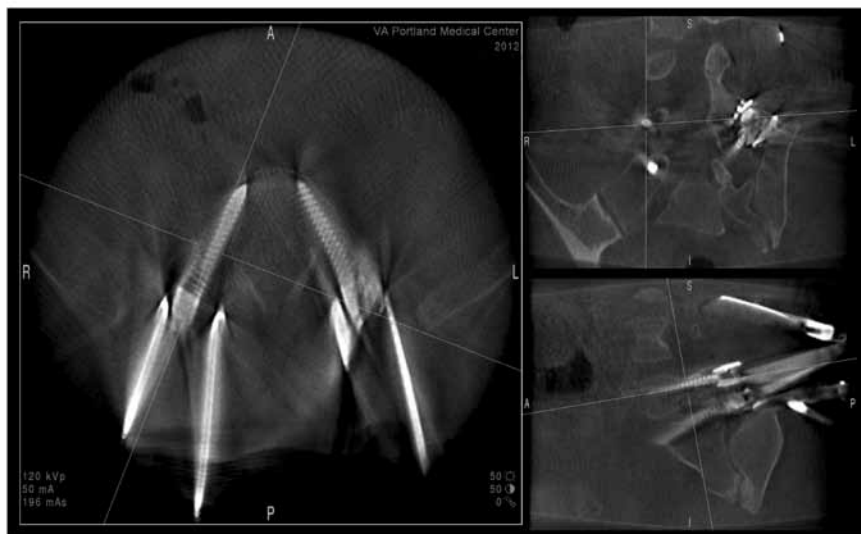


Figure 1. Actual screen capture from the O-arm/Stealth showing reformatted computed tomography images in the axial plane of the screws with associated sagittal and coronal images.

a pilot hole at this point. The pilot hole location was verified with the Stealth probe. An active pedicle awl was used early in this series but later abandoned as unnecessary. A Stealth-guided tap of appropriate size was then used to tap the pedicle and body under continuous image guidance. The hole was palpated for breeches with a ball-tip probe and electrically stimulated up to 30 mA. Depth measurements were taken, and the appropriate length screws were placed with a Stealth-guided screwdriver. Care was taken to ensure that the screw was affixed to the screwdriver without angulation, or an error could be introduced. The screws were electrically stimulated again. The wound was copiously irrigated, and the retractor left in place.

Attention was then turned to the contralateral side, where the identical process was repeated. When all the screws were placed, the patient was covered with 2 longitudinally directed half sheets, leaving only the Stealth antenna protruding between the sheets. A clear fluoroscopy drape

was cut open and placed over the field to cover the antenna, which allowed it to be tracked by the Stealth camera. The O-arm was then used without draping it to obtain another scan verifying the screw locations. After the scan was acquired, multiplanar images were reviewed after tilting or rotating the images so the screws were entirely within the plane of the images on axial, coronal, and sagittal images (Figures 1, 2, and 3). Rods and bone graft fusion constructs were then placed in routine fashion, and the wounds were closed with absorbable sutures.

RESULTS

Over an 18-month period ending October 2013, 48 patients underwent lumbar or thoracolumbar fusion procedures as described earlier by a single surgeon:

- One procedure was for trauma and involved a T11 to L3 fusion
- Two procedures were for malignancy or infection involving 6 and 8 levels of instrumentation
- Thirty-eight procedures were for

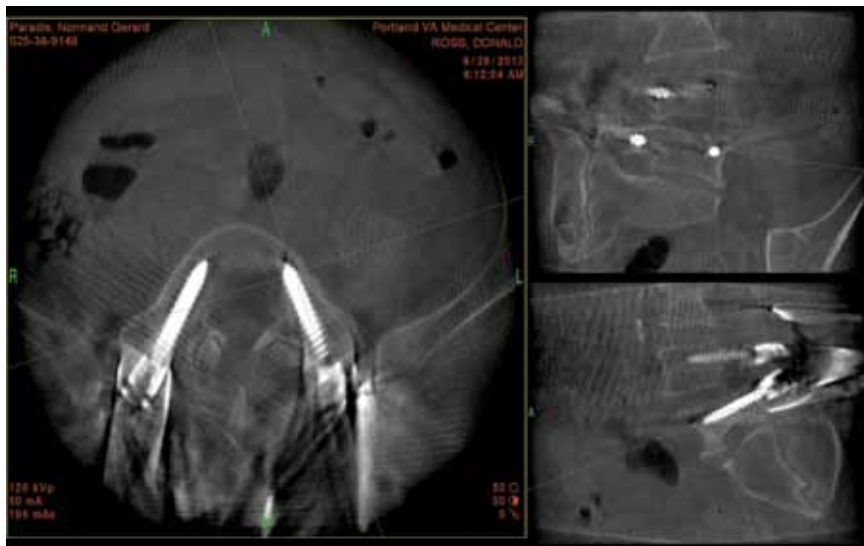


Figure 2. Axial (left) and coronal (right upper) and sagittal (right lower) intra-operative O-arm CT scan reformatted to the plane of the screws.

symptomatic spondylolisthesis, refractory foraminal stenosis, or repair of a symptomatic pseudarthrosis after a posterior interbody fusion with cages done elsewhere

- Thirty-eight procedures were single-level fusions; 7 were 2-level fusions; 1 was a 5-level fusion; and 2 were 6- and 8-level fusions

A total of 232 pedicle screws were placed. In no case was any screw removed or replaced for malpositioning on intraoperative CT, indicating a high degree of accuracy with this system using imaging in the position of surgery and the Stealth stereotactic system. Three screws were carefully inspected and determined to be acceptable but very close to the cortical margin. Stimulation of the screws produced no unacceptably low amperage thresholds (< 10 mA). Loss of registration on the contralateral side was noted in 2 cases when the landmarks indicated by the Stealth probe did not correlate with the surgeon's anatomical knowledge. This was corrected by repeating the CT with restoration of anatomic correlation. Technical problems with the O-arm

delayed 3 cases, but in no case did the device fail to operate after problems were corrected. There were no wound infections, no new neurologic deficits, and no transfusions. A single patient was returned to the operating room for what was recognized as a sterile fluid collection related to bone morphogenetic protein. Operating time for a single-level fusion was about 150 minutes; additional levels added about 30 minutes each to the procedure. Hospitalization for a single-level elective fusion averaged 1.8 days.

DISCUSSION

In 1993, a survey of 617 cases described a rate of unrecognized pedicle screw misplacement of 5.2%.⁴ By 2010, in a review by Sansur and colleagues of 10,242 surgeries for spondylolisthesis, there were 75 (0.7%) implant-related complications, not otherwise defined.¹ There were 118 neurologic complications, of which at least 26 (0.25%) resulted in an implant removal.¹ Very high rates of screw placement accuracy can be achieved. Idler and colleagues re-

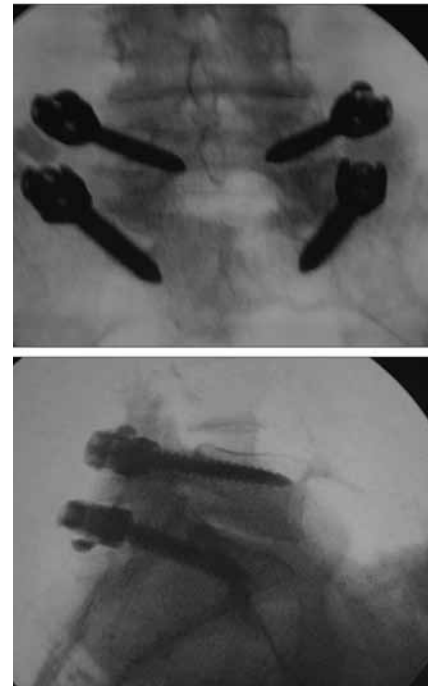


Figure 3. Anterior, posterior, and lateral plain X-rays of the fusion construct shown in Figure 1.

ported that 5 of 326 screws breached the cortex, all by < 2 mm, for an accuracy of placement of 98.5%; no neurologic problems resulted.⁵

Robotic-assisted pedicle screw placement of 3,271 screws was reported to result in a 98% acceptable placement rate with no permanent neurologic morbidity.⁶ Alternatively, free-hand placement without fluoroscopy of 6,816 screws in 964 patients over 7 years has been reported.⁷ One-hundred fifteen screws (1.7%) breached the pedicle in 87 patients (9.0%); 8 patients (0.8%) required revision surgery for malpositioned screws.⁷ However, not all recent research have reported a rate this low. In a review by Lotfinia and colleagues of postoperative CT scans, 247 pedicle screws were inserted in 53 patients.² Lateral screw misplacement was observed in 59 screws (23.9%) and medial pedicle wall vio-

lation in 28 screws (11.3%). Of the 87 misplaced screws, 41 cases were classified as minor (cortical perforation ≤ 2 mm), 41 cases as moderate (2.1 mm to 4 mm), and 5 cases as severe penetration (> 4 mm).² Nerve root injury with radicular pain and neurologic deficits was observed in 8 patients with malpositioned screws (15.1% of all patients).² Other reports have suggested pedicle screw misplacement rates of 4.2% in degenerative spine disease and up to 25% in scoliosis procedures.⁸ In a review of 4,570 pedicle screws in 1,666 adolescent patients with scoliosis, the screw malpositioning rate when determined by CT was as high as 15.7%.⁹ In the thoracic spine, both in clinical and cadaveric studies, pedicle cortex violation has been reported in 10% to 50% of screws when guided by anatomic landmarks or fluoroscopy.¹⁰ A recent review of transforaminal lumbar interbody fusions at the University of Pittsburgh in Pennsylvania reported a 2.1% rate of symptomatic screw misplacement.¹¹

Use of intraoperative electrophysiologic monitoring has been useful in detecting nerve root impingement by pedicle screws and may improve the safety of surgery.^{12,13} As reported by others, it has been this author's experience that high-stimulation thresholds can be misleading, with a significant false negative rate. The only reliable result seems to be a very low stimulation threshold, eg, lower than 8 mA, which usually heralds a cortical breach and deserves careful investigation. Gunnarsson and colleagues noted that intraoperative EMG activity in a series of 213 patients was 100% sensitive but only 28.6% specific for new postoperative neurologic deficit.¹²

In another recent report by Oertel and colleagues, which described

the use of O-arm and Stealth technology, 278 screws were placed in 139 vertebrae.¹⁴ Pedicle perforations were noted in 3.2% of all the screws and in 12.5% of 40 percutaneously placed screws, but criteria for calling a breach were very liberal. No neurologic injuries were incurred, and no returns to the operating room were required. Oertel and colleagues pointed out that O-arm advantages included imaging the patient in the position of surgery, no need for additional registration, and relatively high-quality imaging. They attributed some inaccuracy to wiggling at the interface of the Stealth-guided screwdriver and polyaxial screws.

In this study, the authors did not find that the use of the O-arm slowed down surgery. The machine was mobile and in the same fashion as a C-arm required no remodeling of the operating room for use. Obtaining the initial scan was rapid, and no further registration was required to begin the procedure. The O-arm may then be moved to another operating room for parallel use if needed.

Use of Stealth-guided instrumentation avoided the need for additional fluoroscopy during the procedure, both for verifying the levels exposed by minimally invasive techniques and for screw placement, saving both time and radiation exposure to the operating room personnel. Avoiding redraping of the O-arm for the confirmation scan also saved time and expense. It was critical to position the Stealth antenna in such a way that the surgeon's hands and instruments did not obstruct the view of the antenna by the infrared camera. Reformatted imaging after screw placement, which fully visualized the screws in the axial, sagittal, and coronal planes, was very useful in assessing potential cortical breaches.

A quality and cost review of a re-

turn to the operating room for revision of misplaced pedicle screw cases at the Oregon Health and Science University in Portland, Oregon, from 2009 to 2011 revealed 11 cases. These 11 cases resulted in gross charges of \$507,721, and in the 10 cases for which a payment was made, there were subsequent collections of \$269,070.

CONCLUSION

The data presented here indicate that the O-arm and Stealth technology can result in 100% accuracy in pedicle screw placement in the lumbar spine with no need to return to the operating room for screw impingement on nerve roots or screw placement outside the pedicle or vertebral body. Intraoperative CT has also been reported to be useful and cost-effective in detecting cervical spinal instrumentation misplacement.¹⁵ If payers soon cease to compensate hospitals and surgeons for complications, then it will become critical to avoid symptomatic misplaced pedicle screws. With the array of currently available technology, returning to the operating room for misplaced pedicle screws could soon become a very rare procedure. ●

Acknowledgements

The authors thank Shirley McCartney, PhD, for editorial assistance and Andy Rekito, MS, for illustrative assistance.

Author disclosures

The authors report no actual or potential conflicts of interest with regard to this article.

Disclaimer

The opinions expressed herein are those of the authors and do not necessarily reflect those of Federal Practitioner, Quadrant HealthCom Inc., a division of Frontline Medical Communications

Inc., the U.S. Government, or any of its agencies. This article may discuss unlabeled or investigational use of certain drugs. Please review complete prescribing information for specific drugs or drug combinations—including indications, contraindications, warnings, and adverse effects—before administering pharmacologic therapy to patients.

REFERENCES

1. Sansur CA, Reames DL, Smith JS, et al. Morbidity and mortality in the surgical treatment of 10,242 adults with spondylolisthesis. *J Neurosurg Spine*. 2010;13(5):589-593.
2. Lotfinia I, Sayahmelli S, Gavami M. Postoperative computed tomography assessment of pedicle screw placement accuracy. *Turk Neurosurg*. 2010;20(4):500-507.
3. Tubbs RS, Levin MR, Loukas M, Potts EA, Cohen-Gadol AA. Anatomy and landmarks for the superior and middle cluneal nerves: Application to posterior iliac crest harvest and entrapment syndromes. *J Neurosurg Spine*. 2010;13(3):356-359.
4. Esses SI, Sachs BL, Dreyzin V. Complications associated with the technique of pedicle screw fixation. A selected survey of ABS members. *Spine (Phila Pa 1976)*. 1993;18(15):2231-2238.
5. Idler C, Rolfe KW, Gorek JE. Accuracy of percutaneous lumbar pedicle screw placement using the oblique or "owl's-eye" view and novel guidance technology. *J Neurosurg Spine*. 2010;13(4):509-515.
6. Devito DP, Kaplan L, Dietl R, et al. Clinical acceptance and accuracy assessment of spinal implants guided with SpineAssist surgical robot: Retrospective study. *Spine (Phila Pa 1976)*. 2010;35(24):2109-2115.
7. Parker SL, McGirt MJ, Farber SH, et al. Accuracy of free-hand pedicle screws in the thoracic and lumbar spine: Analysis of 6816 consecutive screws. *Neurosurgery*. 2011;68(1):170-178.
8. Pechlivanis I, Kiriyanthan G, Engelhardt M, et al. Percutaneous placement of pedicle screws in the lumbar spine using a bone mounted miniature robotic system: First experiences and accuracy of screw placement. *Spine (Phila Pa 1976)*. 2009;34(4):392-398.
9. Hicks JM, Singla A, Shen FH, Arlet V. Complications of pedicle screw fixation in scoliosis surgery: A systematic review. *Spine (Phila Pa 1976)*. 2010;35(11):E465-E470.
10. Scheffler KM, Franke J, Eckardt A, Dohmen H. Accuracy of image-guided pedicle screw placement using intraoperative computed tomography-based navigation with automated referencing, part I: Cervicothoracic spine. *Neurosurgery*. 2011;69(4):782-795.
11. Tormenti MJ, Maserati MB, Bonfield CM, et al. Perioperative surgical complications of transforaminal lumbar interbody fusion: A single-center experience. *J Neurosurg Spine*. 2012;16(1):44-50.
12. Gunnarsson T, Krassioukov AV, Sarjeant R, Fehlings MG. Real-time continuous intraoperative electromyographic and somatosensory evoked potential recordings in spinal surgery: Correlation of clinical and electrophysiologic findings in a prospective, consecutive series of 213 cases. *Spine (Phila Pa 1976)*. 2004;29(6):677-684.
13. Krassioukov AV, Sarjeant R, Arkia H, Fehlings MG. Multimodality intraoperative monitoring during complex lumbosacral procedures: Indications, techniques, and long-term follow-up review of 61 consecutive cases. *J Neurosurg Spine*. 2004;1(3):243-253.
14. Oertel MF, Hobart J, Stein M, Schreiber V, Scharbrodt W. Clinical and methodological precision of spinal navigation assisted by 3D intraoperative O-arm radiographic imaging. *J Neurosurg Spine*. 2011;14(4):532-536.
15. Hecht AC, Koehler SM, Laudone JC, Jenkins A, Qureshi S. Is intraoperative CT of posterior cervical spine instrumentation cost-effective and does it reduce complications? *Clin Orthop Relat Res*. 2011;469(4):1035-1041.

To our readers of this special issue:
 Kindly help! Please give us your valued feedback by taking our brief online survey at <https://www.surveymonkey.com/s/FedPracOctSuppStudy>. Or, scan the



QR code below with your smartphone or tablet for direct access to the survey. Thank you in advance for your input!

