

# Traumatic Disruption of Pubis Symphysis With Accompanying Posterior Pelvic Injury After Natural Childbirth

Christian Hierholzer, MD, Arif Ali, MD, Jose B. Toro-Arbelaez, MD, Michael Suk, MD, JD, MPH, and David L. Helfet, MD

**P**arturition-induced pelvic instability is a rare pathogenetic entity. Reports of the incidence of symphyseal rupture after vaginal delivery have varied from 1 in 300 to 1 in 30,000 deliveries.<sup>1-6</sup> The extent of symphyseal changes during pregnancy and delivery may vary significantly. Peripartum ligamentous relaxation with moderate widening of symphysis pubis and sacroiliac (SI) joints is physiologic and occurs regularly.<sup>7,8</sup> Anterior separation of the pubic symphysis of more than 2.5 cm progressively causes injury to the posterior pelvic ring, including disruption of the SI joint or sacral fractures.<sup>9</sup>

When symphyseal rupture does occur, it typically happens during delivery or shortly after labor and is characterized by a sharp and immediate onset of severe pain over the pubic symphysis and may extend posteriorly into the SI joint region accompanied by an audible crack.

Treatment of a ruptured pubic symphysis is predominately nonoperative and consists of pelvic binder application, immobilization and bed rest, analgesia, and physical therapy.<sup>10</sup> Operative treatment has been described in selected cases, particularly when nonoperative treatment is unsuccessful.<sup>1,11,12</sup>

Symphyseal rupture that may indicate posterior pelvic arch instability requires reduction and stable fixation. These injuries result in an unstable pelvic disruption and

may correspond to traumatic anteroposterior compression (APC) II or III or Tile type B or C pelvic injuries.<sup>9,13</sup>

These women should be managed as one would a trauma patient with a pelvic fracture—including vigilant monitoring of hemodynamic status and aggressive resuscitation, appropriate diagnostic imaging studies, and timely operative reduction and fixation of the pelvis.

In this report, we present the case of a woman in her early 30s suffering from traumatic symphysis diastasis with accompanying disruption of left and right SI joints after natural childbirth. The patient, who was successfully treated with open reduction and internal fixation (ORIF) of the symphysis and percutaneous screw fixation of the SI joints, recovered from this disabling injury.

## CASE REPORT

The patient was a woman in her early 30s who presented to the Hospital for Special Surgery 3 days after natural vaginal delivery of her second child at an outside hospital. Past medical history was unremarkable. The patient's previous vaginal delivery, approximately 15 months before the recent delivery, had been uneventful. The patient was asymptomatic before and during her second pregnancy. Delivery of the second child was uncomplicated. The patient received peripartum, epidural anesthesia for pain control. Abnormal or hyperabducted maternal positioning was not recalled. Delivery was not prolonged; it lasted approximately 60 to 90 minutes. The newborn was healthy, birth weight was 4513 g (mean US birth weight, 3446 g; SD, 543 g),<sup>14</sup> and length was 22.5 inches. Forceps and vacuum extraction were not used during delivery.

Thirty minutes after delivery, the patient suddenly developed severe pain over the pubic symphysis and the lower back, with pain radiating into the left leg. She did not suffer additional injuries to abdominal or urogenital organs or nerve roots. Conservative treatment with pelvic binder, bed rest, and analgesia was initiated. The patient was limited to transfers from bed to wheelchair; she could not tolerate a standing position or ambulation with walking aids. Subjective pain on analog pain scale was rated 10 of 10 (maximum pain score).

Because of the persistence of severe symptoms (pain in the anterior symphysis and posterior aspect of the pelvis), the patient was referred to our institution for definitive treatment 3 days after delivery.

The diagnostic workup included standard pelvic anteroposterior (AP), inlet, and outlet x-rays, which showed sym-

Dr. Hierholzer is Attending Orthopedic Surgeon, BG-Unfallklinik Murnau, Murnau, Germany.

Dr. Ali is Attending Orthopedic Surgeon, Division of Orthopedics, Lutheran General Hospital, Park Ridge, Illinois.

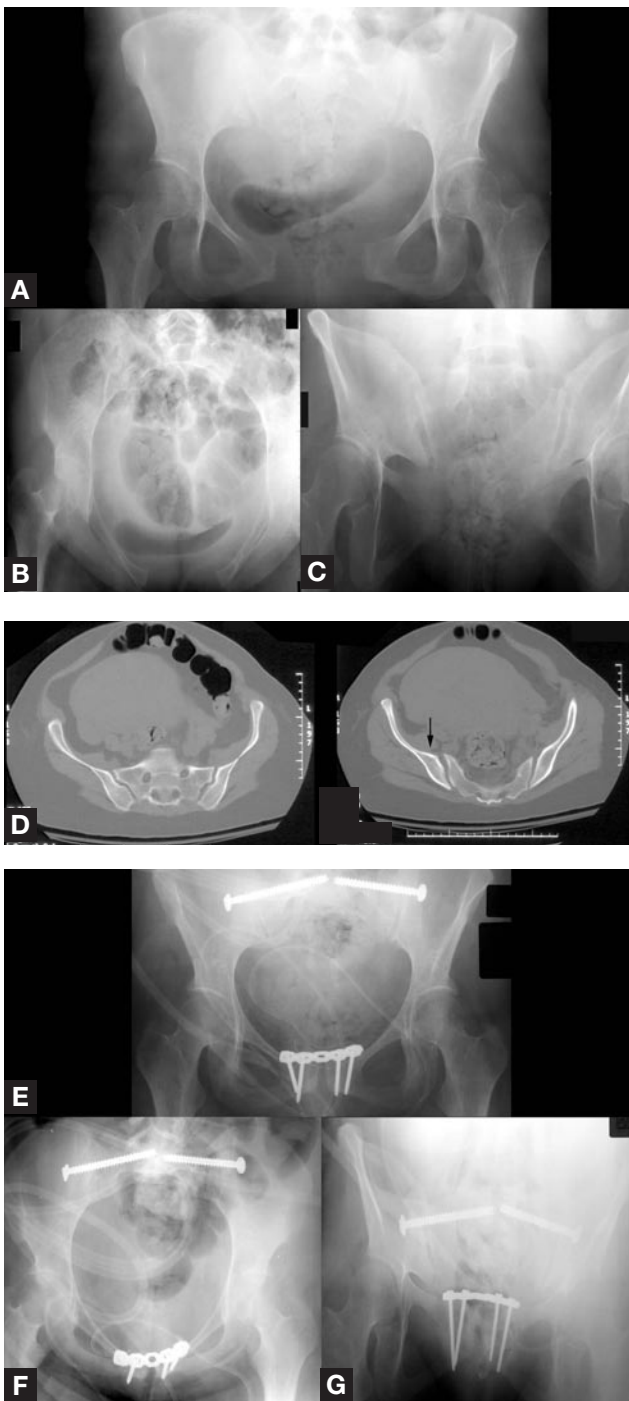
Dr. Toro-Arbelaez is Assistant Professor of Orthopedics, Albert Einstein College of Medicine, and Attending Orthopedic Surgeon, Jacobi Medical Center, Bronx, New York.

Dr. Suk is Assistant Professor of Orthopedics, University of Florida College of Medicine, and Director of the Orthopaedic Trauma Service, The Bone & Joint Institute at Shands, Jacksonville, Florida.

Dr. Helfet is Professor of Orthopaedic Surgery, Weill Medical College of Cornell University, New York, New York, and Director, Orthopaedic Trauma Service, the Hospital for Special Surgery and New York Presbyterian Hospital, New York, New York.

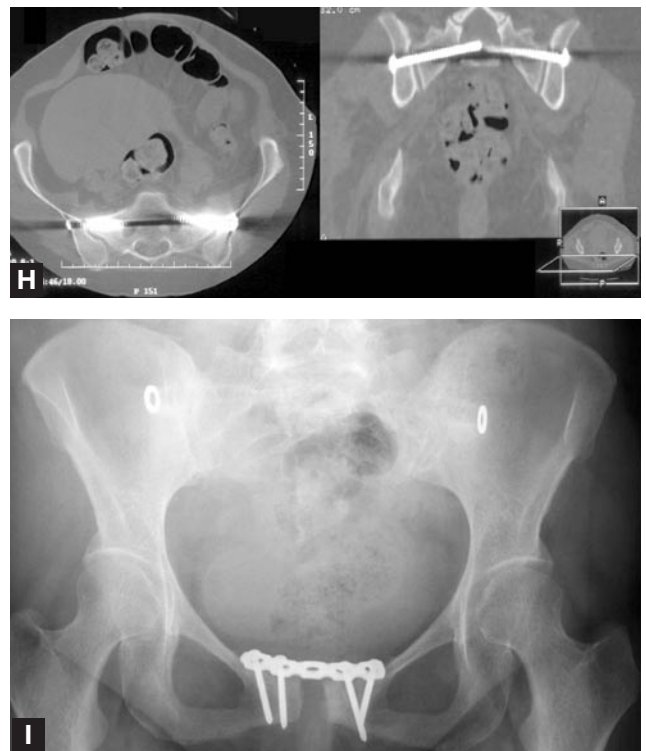
Requests for reprints: David L. Helfet, MD, Department of Orthopaedic Surgery, Weill Medical College of Cornell University/Hospital for Special Surgery, 535 E 70th St, New York, NY 10021 (tel, 212-606-1888; fax, 212-628-4473; e-mail, helfetd@hss.edu).

*Am J Orthop.* 2007;36(11):E167-E170. Copyright Quadrant HealthCom Inc. 2007. All rights reserved.



metric widening of the symphysis pubis of 9 cm and opening of both SI joints posteriorly (Figure, A-C). To evaluate the posterior pelvic ring and SI joints, we obtained a computed tomography (CT) scan with 2-mm slice thickness. The scan showed SI joint dislocation on both sides combined with posterior displacement of the right iliac wing, suggesting disruption of the posterior SI ligament (Figure, D, black arrow). Imaging studies illustrated significant symphyseal widening and disruption of the posterior pelvis equivalent to an APC III or Tile type C pelvic injury.

The patient was placed under anesthesia, and pelvic stability was evaluated. Initially, 2 Schanz pins were placed in



**Figure.** (A,B,C) Three days after vaginal delivery, pelvic anteroposterior (AP), inlet, and outlet x-rays (from counterclockwise) showed separation of the symphysis pubis. The symphysis was separated 9.5 cm, and the sacroiliac (SI) joints were widened. No fractures were identified. (D) Computed tomography (CT) scans of the pelvis were obtained using 2-mm contiguous axial sections (shown in part). Additional sagittal and coronal reformatted images were also obtained (data not shown). CT findings included symphysis diastasis of 9.5 cm and widening of both SI joints. The left SI joint was widened 9 mm, the right SI joint 8 mm, with posterior subluxation indicating disruption of the entire right SI joint. A hairline fracture was noted arising from the right pubic symphysis. (E,F,G) Immediate postoperative AP, inlet, and outlet x-rays (from counterclockwise) showed anatomical reduction of the symphysis pubis and symphysiodesis using anterior plating. SI joint reduction and arthrodesis using 7.3-mm cannulated screws had been performed bilaterally. (H) Postoperative CT scans of the pelvis were obtained using 2-mm contiguous axial sections. Additional sagittal and coronal reformatted images were also obtained (data shown in part). CT scans showed reduction of the pubic symphysis and SI joints. Percutaneously inserted 7.3-mm screws were correctly positioned in the body of S1. (I) The patient returned 25.5 months after initial surgery (2.5 months after hardware removal) with excellent clinical and radiographic results, including return to preinjury physical activity.

the supra-acetabular region. On the right side, translational instability was observed, and on the left side, rotational instability. A pelvic external fixator was used to reduce pubic diastasis. Reduction of the pelvic ring and closure of the pubic symphysis separation were performed using manual posterolateral compression by a combination of bilateral compression over the trochanteric region and using the Schanz pins as joysticks. The external fixator was tightened to maintain anterior reduction at the symphysis as confirmed by fluoroscopy. After initial stabilization with a temporary external fixator, ORIF of the pubic symphysis was performed. For the anterior approach, a Pfannenstiel

skin incision followed by lower abdominal midline fasciotomy was used. The symphysis was fused using a 5-hole, 3.5-mm pelvic reconstruction plate contoured to fit the anterior pelvic ring. Intraoperative fluoroscopic controls using pelvic AP, inlet, and outlet views showed reduction and stable fixation of the anterior pelvic ring and good alignment of both SI joints.

Our treatment protocol is to fix both front and back of the pelvis when there is no uninvolved side on which to base fixation. In this case, extensive pubic diastasis combined with bilateral SI joint dislocation and instability required both anterior and posterior pelvic fixation. Anatomical reduction and stabilization of both SI joints were performed. Under fluoroscopic control, bilateral single 7.3-mm cannulated screws were inserted percutaneously into the body of S1. The external fixator was removed.

The perioperative course was unremarkable. Postoperative conventional x-rays and CT scans were obtained (Figure, E-H). The patient was discharged home on postoperative day 6. She was restricted to 4-point weight-bearing using 2 crutches for 6 weeks, and she performed physical therapy. During follow-up visits, standard pelvic radiographic series showed stable symphysiodesis of the pubic symphysis and closure of bilateral SI joints. Alignment of the pelvic ring was stable, and implants of both the anterior plate and the posterior screws were correctly positioned.

During the first 3 months, pain symptoms persisted predominantly during mobilization and weight-bearing. The patient could not lift and nurse her child properly. Physical therapy was performed regularly.

Twelve months after surgery, the patient noticed significant progress and alleviation of pain symptoms. Sixteen months after surgery, she was fully weight-bearing and used a cane intermittently for balance. She had resumed daily activities as a homemaker but had not returned to recreational activities (eg, bike riding, swimming). She reported an uneventful third pregnancy and vaginal delivery of a third child without any recurrence of osteitis pubis or associated symptoms 15 months after the initial diagnosis of postpartum pelvic disruption. At 23 months, x-ray control showed that iliosacral screws had backed out slightly, and there was some evidence of surrounding lysis. The SI joint screws were then removed 2 years after the initial surgery because of referred posterior pelvic pain. Even though there were signs of front plate loosening, the hardware was not removed, as the patient was asymptomatic anteriorly. Two and a half months after removal of iliosacral screws, the patient reported complete relief of the pelvic pain and return to preinjury activity (Figure, I).

## DISCUSSION

Delivery of a mature infant can result in injury of the pubic symphysis.<sup>15</sup> Relaxation of the ligaments and widening of the pubic symphysis occur physiologically during pregnancy and delivery and is mediated by hormonal changes. Elevated levels of progesterone and relaxin are responsible for increased elasticity of ligaments.<sup>5</sup> Ligamentous relaxation

provides relative mobility of the pubic symphysis and SI joint synchondroses, resulting in widening of the birth canal and facilitating delivery. Physiologic peripartum symphyseal widening ranges from 3 to 7 mm and often remains asymptomatic. Slight pubic diastasis in the absence of clinical symptoms is frequent and insignificant.<sup>15</sup>

After delivery, the relaxation process is reversible; it returns to normal within 12 weeks postpartum. With restoration of normal ligamentous elasticity, pubic diastasis is resolved, and the pelvic ring is restabilized. Symphyseal separation of more than 10 mm is pathologic and indicative of rupture of the ligaments. Ligamentous rupture renders the pubic symphysis unstable. Symphysiolysis is seldom associated with diastasis of more than 15 mm.<sup>8</sup> Significant symphyseal widening, exceeding 4 to 6 cm and more, has been reported.<sup>7,8</sup> Significant anterior separation of the pubic symphysis (>2.5 cm) causes progressive injury to the posterior pelvic ring, including disruption of the SI joint or sacral fractures as well as injuries to the lumbosacral plexus.<sup>8</sup>

Incidence of pathologic symphyseal separation after vaginal delivery is not well documented. Few studies have reported incidences, which have ranged from 1 in 521 in a historic report by Boland<sup>2</sup> in 1933; 1 in 20,000 by Eastman and Hellman<sup>3</sup> in 1966; 1 in 600 by Taylor and Sonson<sup>5</sup> in 1986; and 1 in 800 in recent reports.<sup>4</sup>

The etiology of symphysis rupture has not been completely elucidated. Mechanical stresses contribute to disruption during delivery. Specifically, rapid and forceful descent of the presenting fetal part into the birth canal in stage 2 of labor and wedging of the head against the anterior pelvic ring create mechanical shear forces that can cause ligamentous rupture. In addition, a complicated delivery, fetal dystocia, maternal hip dysplasia, and previous pelvic trauma have been implicated.<sup>8</sup>

Clinically, patients present with typical symptoms and signs. The sudden onset of intense pain and feeling of separation over the pubic symphysis during delivery may be indicative of rupture rather than relaxation of pubic ligaments. Pain can be found over the SI joint and the inguinal area and in the deep pelvis and lumbar region. A palpable pubic diastasis, grating, and pain on bilateral trochanteric compression are pathognomonic. Additional symptoms suggestive of pelvic instability include intensified pain over the pubic symphysis provoked by mobilization and weight-bearing, as well as increased pain over the SI joint region with single-leg weight stress or the Patrick test. Our patient presented with these characteristic symptoms. No additional injuries during diagnostic workup were detected.

For diagnostic imaging, standard x-rays of the pelvis—AP, inlet, outlet, Judet obturator, and iliac x-rays—are required. A pubic diastasis of more than 10 mm is classified as pathologic.<sup>7</sup> Vertical displacement of the SI joint can be diagnosed with examination under anesthesia and stress imaging with a single-leg standing AP pelvis x-ray (Flamingo view). Vertical instability is defined with a displacement exceeding 5 mm<sup>7</sup> or, more recently, exceeding 2 mm.<sup>16</sup>

CT scans with 2-mm slice thickness provide additional information on the extent of SI joint dislocation, sclerosis, and bone cysts. Magnetic resonance imaging (MRI) can reveal soft-tissue injuries, including clefts within symphyseal carti-



lage, joint hemorrhage, and edema. In addition, MRI can be used to detect ligamentous injuries of the pelvic floor.

Treatment of choice for postpartum symphysiolysis is conservative. Application of an external pelvic binder exerts sufficient lateral compression to effectively close the pubic diastasis. Temporary immobilization and bed rest supported by well-titrated pain medication often alleviate symptoms. Recovery from symphysiolysis can be expected within 6 weeks.<sup>8,17</sup>

Physical therapy and non-weight-bearing mobilization are performed as tolerated. During the acute stage of symphysiolysis daily local injection with hydrocortisone and anaesthetics<sup>18</sup> or epidural injections have been proposed to relieve pain symptoms and to facilitate ambulation.<sup>19</sup>

Surgical treatment of peripartum pelvic complications is a therapeutic option when conservative treatment has failed to control severe pain symptoms. Shuler and colleagues<sup>20</sup> reported the successful treatment of chronic postpartum pelvic pain by surgical stabilization using anterior pubic symphysiodesis and SI joint arthrodesis with cannulated screws.

Surgical treatment is recommended for proven pelvic instability. Extensive anterior separation of the pubic symphysis and vertical instability of the dorsal pelvic ring causing pelvic dislocation require internal fixation.<sup>1,21</sup>

The 4 Hagen criteria for instability that necessitates internal fixation are pubic diastasis of more than 1 cm, vertical shift of more than 5 mm, widening of the SI joint, and para-articular sclerosis of the SI joint.<sup>7</sup> Some authors base decision making on the extent of pubic diastasis. Hagen<sup>7</sup> observed development of chronic pain symptoms and vertical instability in patients with pubic diastasis of more than 15 mm and recommended internal fixation of all pubic separations. In injuries with pubic diastasis exceeding 4 cm, Kharrazi and colleagues<sup>8</sup> recommended formal examination of symphyseal and SI joint stability under anesthesia. For rotationally stable pelvic ring injuries, ORIF of the pubic symphysis with anterior plating but without prophylactic SI arthrodesis is indicated. In patients with pubic separation of less than 4 cm, conservative treatment with binder and bed rest was the treatment of choice.

Other studies advocate an extensive operative approach, including symphysiodesis and stabilization of the SI joint, if pain symptoms are suggestive of, or imaging studies have proved, vertical instability in the SI joints.<sup>1,22</sup> Kharrazi and colleagues<sup>8</sup> concluded that reevaluation of the role of operative intervention in women with severe pelvic dislocation associated with childbirth is justified.

Our treatment concept is equivalent to the management of traumatic pelvic ring injuries and is based on the AO (Arbeitsgemeinschaft für Osteosynthesefragen) and Tile classification,<sup>9</sup> which differentiates between unstable and stable injuries of the pelvic ring depending on continuity of the posterior arch.

Our treatment protocol is to fix the front and the back of the pelvis when there is no uninvolved side on which to base fixation. However, in cases in which only rotational instability is present, anterior fixation is the recommended treatment when nonoperative management proves unsuccessful.

## CONCLUSIONS

In the case reported here, our patient suffered an unstable pelvic ring injury with rupture of the pubic symphysis with subsequent rotational instability on the left and complete instability on the right. Anterior and posterior instability of the pelvic ring mandated ORIF of the pubic symphysis and SI joints. The patient recovered almost completely from the debilitating sequelae of peripartum traumatic disruption of pubic symphysis. Rehabilitation was prolonged but successful. Operative stabilization of the pelvic ring did not impair the course and delivery of a subsequent, third child and protected the patient from recurrence of disruption of the pelvic ring. Based on our limited case experience, after this surgical treatment of fibrous fusion, there is enough joint elasticity to accommodate subsequent normal vaginal delivery.

## AUTHORS' DISCLOSURE STATEMENT

The authors report no actual or potential conflict of interest in relation to this article.

## REFERENCES

- Rommens PM. Internal fixation in postpartum symphysis pubis rupture: report of three cases. *J Orthop Trauma*. 1997;11(4):273-276.
- Boland, B. F. Rupture of the symphysis pubis articulation during delivery. *Surg., Gynec. and Obstet*. 1933;57: 517-522.
- Eastman NJ, Hellman LM. *Williams Obstetrics*. 13th ed. New York, NY: Appleton-Century-Crofts. 1966:820-821.
- Scriven MW, Jones DA, McKnight L. The importance of pubic pain following childbirth: a clinical and ultrasonographic study of diastasis of the pubic symphysis. *J R Soc Med*. 1995;88(1):28-30.
- Taylor RN, Sonson RD. Separation of the pubic symphysis. An underrecognized peripartum complication. *J Reprod Med*. 1986;31(3):203-206.
- Moral M, Ruiz R, Alonso M, Marquez G, Odriozola JM. Two cases of postpartum pubis diastasis mistaken for neurological complications of epidural analgesia. *Rev Esp Anestesiol Reanim*. 2004;51(8):448-451.
- Hagen R. Pelvic girdle relaxation from an orthopaedic point of view. *Acta Orthop Scand*. 1984;45:550-563.
- Kharrazi FD, Rodgers WB, Kennedy JG, Lhowe DW. Parturition-induced pelvic dislocation: a report of four cases. *J Orthop Trauma*. 1997;11(4):277-281.
- Tile M, Pennal GF. Pelvic disruption: principles of management. *Clin Orthop*. 1980;151:56-64.
- Culligan P, Hill S, Heit M. Rupture of the symphysis pubis during vaginal delivery followed by two subsequent uneventful pregnancies. *Obstet Gynecol*. 2002;100:1114-1117.
- Peterson AC, Rasmussen KL. Internal fixation as treatment for total puerperal rupture of the pubis symphysis. *Acta Obstet Gynecol. Scand*. 1992;71(4):308-310.
- Mau C, Ovansen J, Jensen J. Rupture of the symphysis after spontaneous delivery: surgical treatment of four cases. *Ugeskr Laeger*. 2001;163(10):1442-1443.
- Dalal SA, Burgess AR, Siegel JH, et al. Pelvic fracture in multiple trauma: classification by mechanism is key to pattern of organ injury, resuscitative requirements, and outcome. *J Trauma*. 1989;29(7):981-1000.
- David RJ, Collins JW Jr. Differing birth weight among infants of U.S.-born blacks, African-born blacks, and U.S.-born whites. *N Engl J Med*. 1997;337(17):1209-1214.
- Putschar WG. The structure of the human symphysis pubis with special consideration of parturition and its sequelae. *Am J Phys Anthropol*. 1976;45(3 pt 2):589-594.
- Walheim GG, Olerud S, Ribbe T. Motion of the pubic symphysis in pelvic instability. *Scand J Rehabil Med*. 1984;16:163-169.
- Rommens PM. Internal fixation in postpartum symphysis pubis rupture: report of three cases. *J Orthop Trauma*. 1997;11(4):273-276.
- Schwartz Z, Katz Z, Lancet M. Management of puerperal separation of the symphysis pubis. *Int J Gynaecol Obstet*. 1985;23:125-128.
- Fuller JG, Janzen J, Gambling DR. Epidural analgesia in the management of symptomatic symphysis pubis diastasis. *Obstet Gynecol*. 1989;73(5 Pt 2):855-857.
- Shuler TE, Boone DC, Gruen GS, Peitzman AB. Percutaneous iliosacral screw fixation: early treatment for unstable posterior pelvic ring disruptions. *J Trauma*. 1995;38(3):453-458.
- Olerud S, Walheim GG. Symphysiodesis with a new compression plate. *Acta Orthop Scand*. 1984;55:315-318.
- Shuler TE, Gruen GS. Chronic postpartum pelvic pain treated by surgical stabilization. *Orthopedics*. 1996;19:687-689.