

Intraosseous Stab Wound to the Arm

Joseph A. Abboud, MD, Brent Wiesel, MD, Daniel Tomlinson, MD, and Matthew Ramsey, MD

Although stab wounds are common in metropolitan settings, involvement or injury to the bone is seldom reported.¹⁻⁴ We report on a patient who presented with a knife retained in the humerus after a stab wound to the arm. To our knowledge, this is the first documented case of a patient who presented for treatment after receiving an intraosseous stab wound to the upper extremity with the foreign body still lodged in the bone. Our patient was informed that data concerning this case would be submitted for publication.

CASE REPORT

A 53-year-old woman presented to our trauma bay with pain in her left upper extremity. She reported that she had been assaulted and stabbed in the left arm less than an hour earlier. On arrival, the patient's primary survey was intact; on secondary survey, it was noted that the patient had a foreign body retained in the left deltoid. Neurologic function in the right upper extremity was intact on physical examination.

Upright chest x-ray showed a foreign body, which seemed to traverse the humerus toward the thorax with no evidence of a pneumothorax (Figure 1). The patient was immediately given antibiotics (cefazolin, gentamycin) and a tetanus booster. After she was determined to be hemodynamically stable, computed tomography (CT) scans of the chest and neck were obtained; they showed a knife lodged in the proximal metaphyseal region of the left humerus (Figures 2A-2D). The knife had traversed the posterior inferior aspect of the glenoid and entered the scapulothoracic space. Despite depth of injury, there were no pneumothorax and no apparent vascular injury or extravasation. The knife handle had broken off during the stabbing, which made removal more challenging. The

patient was emergently taken to the operating room for removal of the foreign body and irrigation and débridement of the bony tract.

In the operating room, the knife blade was exposed in the proximal humerus by extending an incision both proximal and distal to the blade (Figure 3). The blade was noted as traversing through the deltoid without causing appreciable injury to the axillary nerve. Pliers were used to remove the blade, without incident (Figure 4). The bone tract was débrided using curettes and irrigated with pulse lavage, and the wound was closed loosely.

The patient received intravenous antibiotics (cefazolin, gentamycin) for 48 hours after surgery. She was placed in a sling for comfort and started on pendulum exercises. A routine postoperative x-ray showed no retained foreign body. The patient remained neurovascularly intact and had no appreciable deficits. One week after surgery, she was allowed to return to full activity of the upper extremity as tolerated. One year after surgery, she had full range of motion of the shoulder, no pain, and no evidence of infection.

DISCUSSION

A knife retained from an intraosseous stab wound is a rare entity. With there being no cases reported in the literature, we had no preformed algorithm on which to base treatment for our patient. However, the treatment we advocated was in keeping with the guidelines used for any retained foreign body—remove foreign body, irrigate its tract, provide systemic antibiotics.^{3,5,6}

After primary and secondary surveys of this trauma patient were performed, the foreign body was removed in the operating room. If possible, foreign body removal should be delayed until the patient is in this controlled set-

Dr. Abboud is Clinical Assistant Professor of Orthopaedic Surgery, University of Pennsylvania Health System, Pennsylvania Hospital, Philadelphia, Pennsylvania.

Dr. Wiesel is Orthopaedic Surgery Fellow, Rothman Institute, Thomas Jefferson University, Philadelphia, Pennsylvania.

Dr. Tomlinson is Attending Orthopaedic Surgeon, Middletown, New York.

Dr. Ramsey is Associate Professor of Orthopaedic Surgery, Thomas Jefferson University, Philadelphia, Pennsylvania.

Address correspondence to: Joseph Abboud, MD, University of Pennsylvania Health System, Pennsylvania Hospital, 3B Orthopaedics, 800 Spruce Street, Philadelphia, PA 19107 (tel, 215-829-2451; fax, 215-829-2454; e-mail, Joseph.Abboud@uphs.upenn.edu).

Am J Orthop. 2008;37(3):E52-E54. Copyright, Quadrant HealthCom Inc., 2008. All rights reserved.

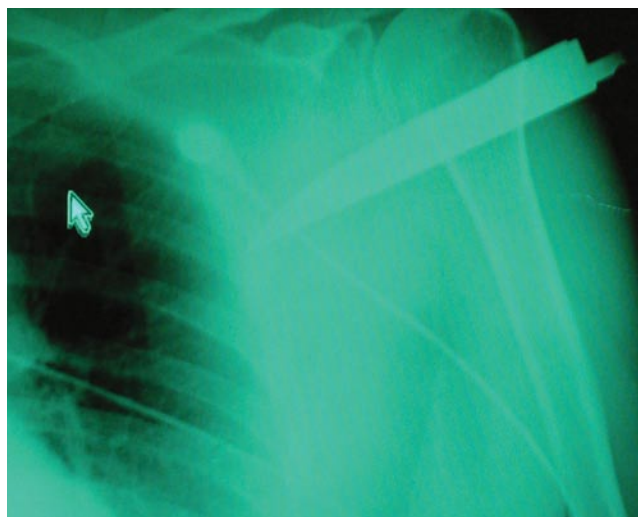
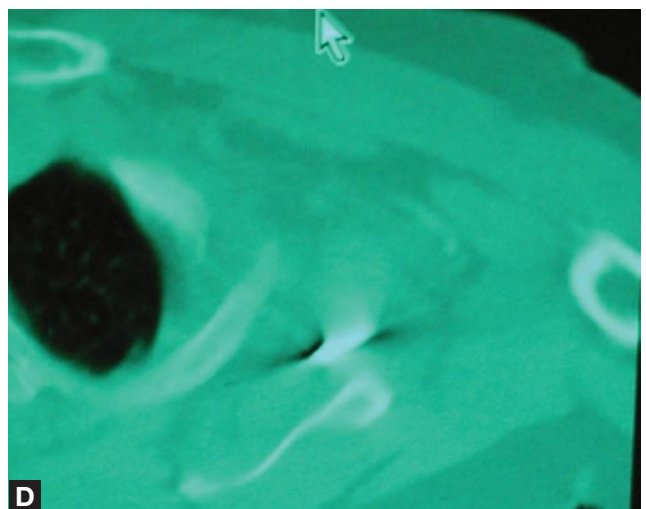
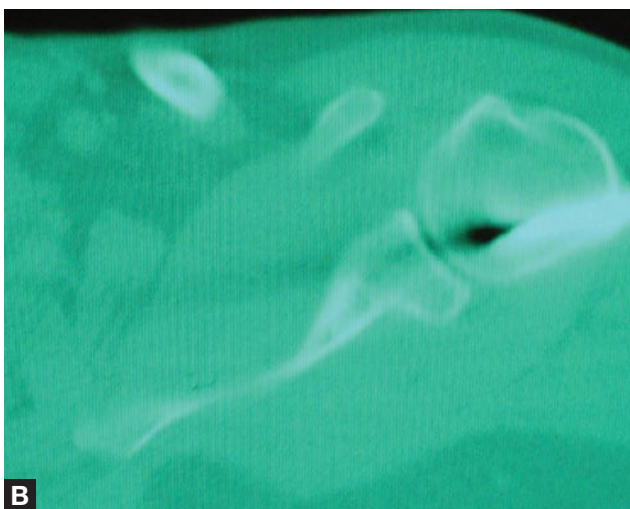
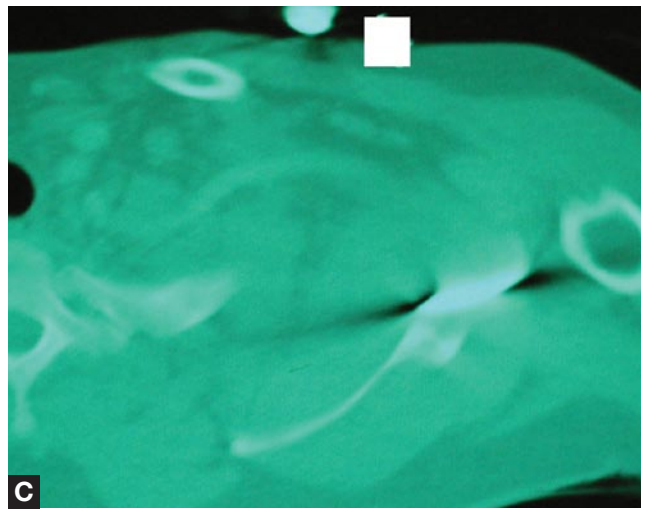
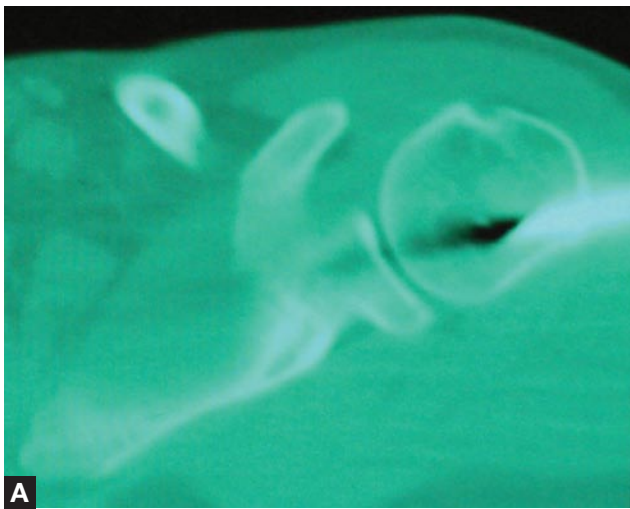


Figure 1. Chest x-ray shows knife retained in the left humerus.



Figures 2A-2D. Axial computed tomography images sequentially show knife traversing the bone and penetrating the scapulothoracic space.

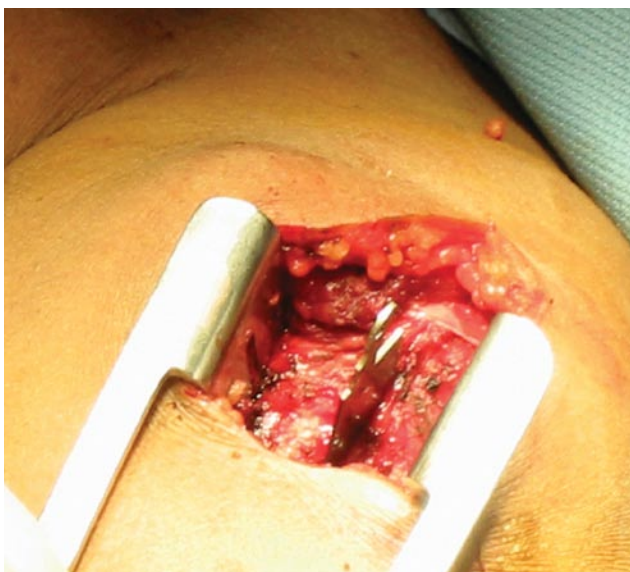

Figure 3. Intraoperative image of knife penetrating the deltoid and proximal humerus.

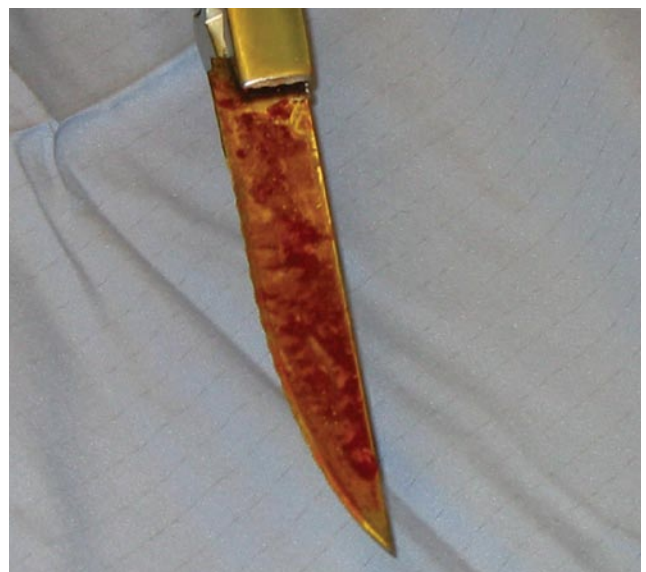

Figure 4. Intraoperative image of knife after being removed from patient.

ting in case extraction results in hemodynamic instability or reveals a significant vascular injury that requires repair. After the foreign body is removed, débridement and copious irrigation should be performed to remove any residual foreign matter. In this case, to avoid unnecessary morbidity, deep dissection into the knife tract was not attempted. Timely removal of the knife and prompt introduction of intravenous antibiotics also guided our decision not to perform a deeper dissection.

Intraosseous stab wound injuries are rare because of the considerable force needed to impale a sharp object through bone. Studies designed to help in body armor manufacturing have estimated that the maximum energy in a stabbing action is approximately 115 J, and the load produced by the knife on contact with the target is approximately 1000 N.^{7,8} In our patient's case, postmenopausal status plus the metaphyseal entry point of the knife blade likely contributed to the feasibility of the bony injury.

Although we report the first case of an isolated intraosseous stab wound, there have been reports of fatal stabbings with a 53% incidence of bony and cartilaginous injuries.¹ We believe that nonfatal stabbings, such as in our patient's case, occur with a frequency higher than that reported in the orthopedic literature.

As there are no reports of retained intraosseous stab wounds in the orthopedic literature, the present case report

provides a loose guideline on which treatment for this type of injury can be based.

AUTHORS' DISCLOSURE STATEMENT

The authors report no actual or potential conflict of interest in relation to this article.

REFERENCES

1. Banasr A, de la Grandmaison GL, Durigon M. Frequency of bone/cartilage lesions in stab and incised wounds fatalities. *Forensic Sci Int.* 2003;131(2-3):131-133.
2. Ford TC, Anania WC, Rosen RC. Osseous trauma of the lower extremity secondary to knife wounds. Two case reports. *J Am Podiatr Med Assoc.* 1986;76(8):462-463.
3. Grobbelaar A, Knottenbelt JD. Retained knife blades in stab wounds of the face: is simple withdrawal safe? *Injury.* 1991;22(1):29-31.
4. Rose SC, Fujisaki CK, Moore EE. Incomplete fractures associated with penetrating trauma: etiology, appearance, and natural history. *J Trauma.* 1988;28(1):106-109.
5. Greene MW, Hackney FL, Nishioka GJ, Triplitt RG. Fractured knife blade—an incidental finding. *Oral Surg Oral Med Oral Pathol.* 1991;72(6):758-759.
6. Maloon S, Singer M. Radial nerve laceration two years after a stab wound to the distal humerus: a case report. *J Hand Surg Br.* 1990;15(4):494-495.
7. Chadwick EK, Nicol AC, Lane JV, Gray TG. Biomechanics of knife stab attacks. *Forensic Sci Int.* 1999;105(1):35-44.
8. Horsfall I, Prosser PD, Watson CH, Champion SM. An assessment of human performance in stabbing. *Forensic Sci Int.* 1999;102(2-3):79-89.