

Pathologic Femoral Neck Fractures in Children

M. Wade Shrader, MD, Joseph H. Schwab, MD, William J. Shaughnessy, MD, and David J. Jacofsky, MD

ABSTRACT

Pathologic fractures in children occur in a variety of malignant and benign pathologic processes. Pediatric pathologic femoral neck fractures are particularly rare. Until now, all reported cases have been isolated cases, small series, or cases reported in series of adult pathologic hip fractures. The present article is the first report of a relatively large series of pathologic femoral neck fractures in a pediatric population.

We identified pathologic femoral neck fractures, including 2 basicervical fractures, in 15 children (9 boys, 6 girls) ranging in age from 18 months to 15 years (mean age, 9 years) and treated between 1960 and 2000. The pathologic diagnoses were fibrous dysplasia (5 children), unicameral bone cyst (2), Ewing's sarcoma (2), osteomyelitis (2), leukemia (1), rhabdomyosarcoma (1), osteogenesis imperfecta (1), and osteopetrosis (1). Treatment methods, including time to reduction and fixation, were reviewed in detail. One patient was lost to follow-up. All others were followed until union; mean long-term follow-up was 7 years (range, 1-16 years).

All patients ultimately went on to union. Mean time to union was 19 weeks (range, 5-46 weeks). However, 2 patients died before 2 years. There was a 40% complication rate, with limb-length discrepancy being the most common (4 children). No patient developed avascular necrosis.

Pathologic femoral neck fractures are rare in children. Pediatric patients who present with a pathologic hip fracture are at significant risk for complications. Physicians and family should be alerted to the prolonged course involved in treating these fractures to union.

Pathologic fractures are a known complication of certain disease processes, including primary malignancy, metastatic disease, and infection. For disorders particularly common in children, especially fibrous dysplasia (FD), unicameral bone cysts (UBCs), and osteogenesis imperfecta (OI), pathologic fractures are not an uncommon problem faced by pediatric orthopedic surgeons. Pathologic hip fractures are much

Dr. Shrader is Orthopedic Resident, Dr. Schwab is Orthopedic Resident, Dr. Shaughnessy is Associate Professor of Orthopedic Surgery, and Dr. Jacofsky is Assistant Professor of Orthopedic Surgery, Department of Orthopedics, Mayo Clinic, Rochester, Minnesota.

Address correspondence to: William J. Shaughnessy, MD, Department of Orthopedics, Mayo Clinic, 200 First Street SW, Rochester, MN 55905 (tel, 507-284-3659; fax, 507-266-4234; e-mail, shaughnessy.william@mayo.edu).

Am J Orthop. 2009;38(2):83-86. Copyright, Quadrant HealthCom Inc. 2009. All rights reserved.

more common in adults and usually are caused by metastatic disease. These fractures are typically treated with internal fixation, intramedullary fixation, or arthroplasty.¹ Fractures in the femoral neck of children are extremely rare and require special treatment considerations because of growth issues and the possibility of avascular necrosis (AVN).²

The literature includes very little on pathologic femoral neck fractures in children. Fractures in FD have received the most attention. In their series on femoral neck insufficiency fractures in FD, Enneking and Gearen³ indicated that 6 of the 15 patients were children. Funk and Wells⁴ reported on 4 pediatric patients with FD, 2 of whom had pathologic femoral neck fractures. In addition, several other authors have documented single cases of pathologic hip fracture in patients with simple bone cysts, aneurysmal bone cysts, parathyroid adenoma, and Gaucher disease.^{2,5-9} An article in the radiology literature covered a series of 37 pediatric pathologic femoral neck fractures, but not much of the article was focused on their orthopedic management.¹⁰

In the present, retrospective review, we evaluate a relatively large case series of pediatric pathologic femoral neck fractures treated at an academic, tertiary-care referral cen-

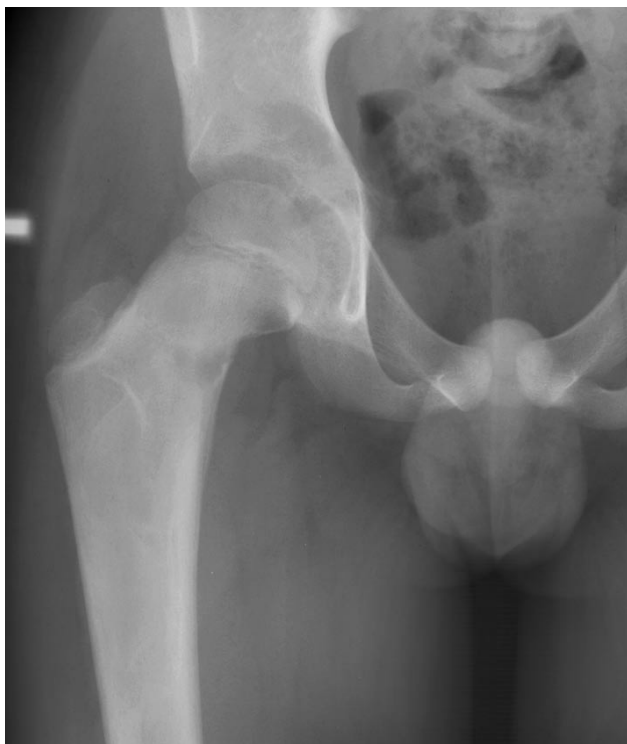

Figure 1. A 9-year-old boy with persistent hip pain was diagnosed with fibrous dysplasia.

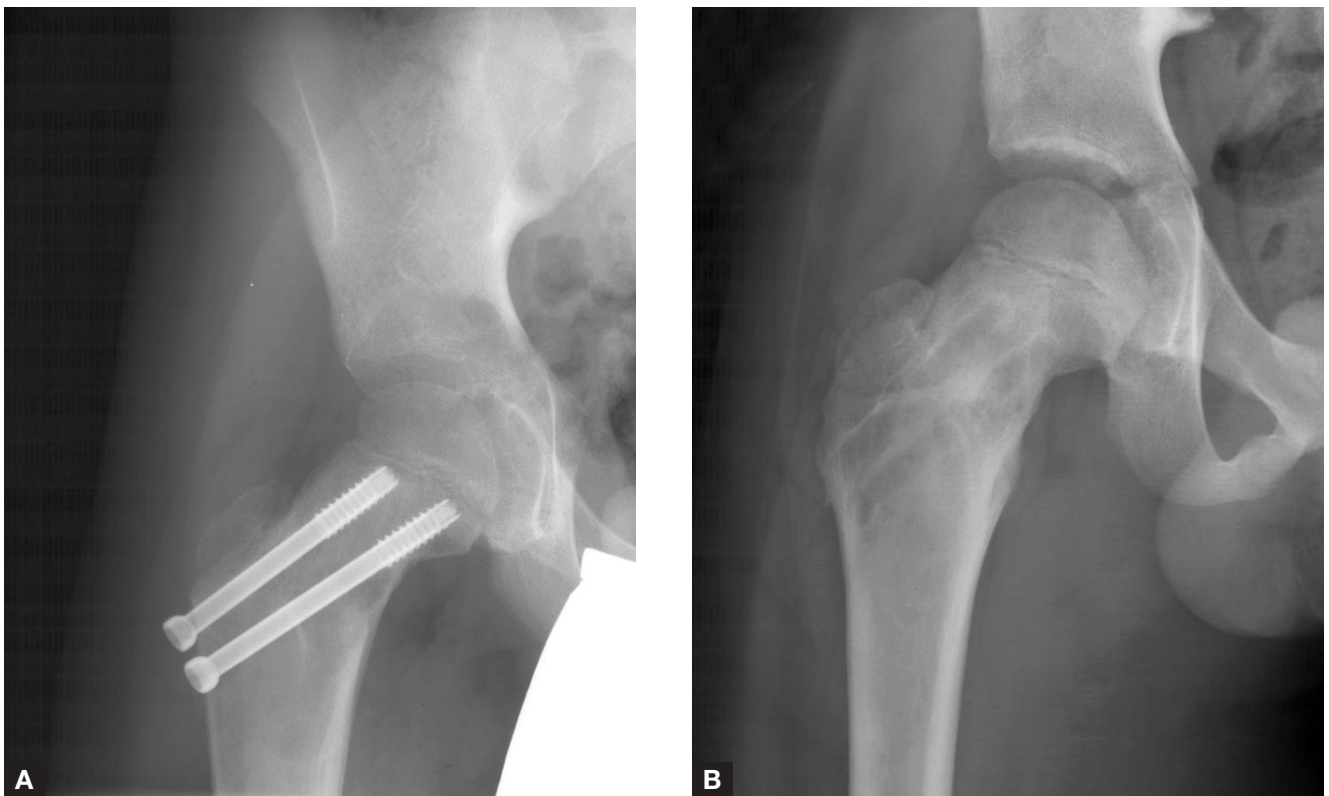


Figure 2. (A) Immediate postoperative radiographs show treatment with screw fixation and open bone grafting of lesion. (B) The patient had normal hip motion and no pain 2 years after hardware removal.

ter. Our goal in this study was to determine the presentations, treatment methods, and results of treatment for children with pathologic hip fractures. In particular, complications and instances of AVN were investigated.

MATERIALS AND METHODS

This investigation was performed in the Department of Orthopedic Surgery at the Mayo Clinic and Mayo Foundation in Rochester, Minnesota. We reviewed the medical records and radiographs of all pediatric patients brought to our institution with a pathologic femoral neck fracture between 1960 and 2000. After excluding patients older than 16 and intertrochanteric hip fractures, and including femoral neck and basicervical fractures, we identified 15 pediatric patients for study (9 boys, 6 girls; mean age, 9 years; range, 18 months–15 years). Patients were followed until union (mean long-term follow-up, 7 years; range, 1–16 years). One patient was lost to follow-up. One child died 3 months after the pathologic fracture was diagnosed, and 1 child died 1 year after diagnosis.

The pathologic diagnoses were FD (5 patients), UBCs (2), Ewing’s sarcoma (2), osteomyelitis (2), leukemia (1), rhabdomyosarcoma (1), OI (1), and osteopetrosis (1). Patient demographics are listed in the Table.

We reviewed the medical histories of these children in detail and recorded patient demographics. Details of the pathologic diagnosis were determined, when possible, along with any mechanism of injury. Specific operative techniques, methods of internal fixation, and postoperative immobiliza-

tion were documented in detail. Complications were recorded in detail, with special attention paid to the complication of AVN. Any reoperation or revision surgery was recorded.

When available, initial radiographs were analyzed for fracture classification and initial displacement. Immediate postoperative radiographs were closely analyzed to determine adequacy of reduction. Follow-up radiographs were reviewed to determine time to union and to determine long-term sequelae, such as AVN, angular deformity, and limb-length discrepancy (LLD).

RESULTS

Fifteen pediatric patients with pathologic femoral neck fractures were identified. Thirteen of the fractures were through the femoral neck; the other 2 were basicervical. Five fractures occurred after a significant fall and 1 after a bicycle accident; in the remaining 9 cases, a specific mechanism of injury was not recalled by the parents or the child. For 10 children, the initial presenting complaint was hip pain (ie, the hip fracture diagnosis led to the pathologic process diagnosis); for the other 5 children, the hip fracture occurred after the pathologic process had been diagnosed.

Treatments for these fractures are outlined in the Table. One patient with a minimally displaced fracture with FD was treated nonoperatively with protected weight-bearing and crutches. Three patients with minimally displaced fractures (1 with UBC, 1 with osteopetrosis, 1 with OI) were treated with spica casting alone. All other patients were treated surgically. Of the 6 patients who underwent open

Table. Data on 15 Pediatric Patients With Pathologic Femoral Neck Fractures

Pt No.	Age	Sex	Pathology	Surgery	Union	Follow-Up	Complication
1	10	M	Unicameral bone cyst	Open reduction, bone grafting, internal fixation with Knowles pins	Union at 15 wk	7 y	Leg-length discrepancy
2	9	M	Ewing's sarcoma	Percutaneous Knowles pins	Union at 14 wk	Died 1 y after surgery	Leg-length discrepancy
3	15	M	Rhabdomyosarcoma	Percutaneous Knowles pins	Died 3 mo after surgery	Died 3 mo after surgery	—
4	5	M	Osteopetrosis	Spica cast	Lost to follow-up	Lost to follow-up	—
5	15	M	Fibrous dysplasia	Protected weight-bearing	Union at 15 wk	4 y	—
6	5	F	Fibrous dysplasia	Open reduction, internal fixation with dynamic hip screw	Union at 25 wk	2 y	Lesion recurrence
7	6	F	Fibrous dysplasia	Open bone grafting and spica cast	Malunion	16 y	Malunion
8	6	M	Ewing's sarcoma	Open reduction, internal fixation with dynamic hip screw	Union at 45 wk	8 y	Leg-length discrepancy
9	12	F	Osteomyelitis	Open debridement and spica cast	Union at 47 wk	9 y	Leg-length discrepancy
10	1	F	Leukemia	Open debridement and bone grafting	Union at 5 wk	14 y	—
11	10	M	Unicameral bone cyst	Spica cast	Union at 27 wk	1 y	—
12	6	M	Osteogenesis imperfecta	Spica cast	Union at 5 wk	12 y	—
13	15	F	Fibrous dysplasia	Open reduction, bone grafting, internal fixation with dynamic hip screw	Union at 13 wk	6 y	—
14	9	M	Fibrous dysplasia	Open reduction, bone grafting, internal fixation with cannulated screws	Union at 9 wk	1.5 y	—
15	13	F	Osteomyelitis	Open debridement and spica cast	Union at 13 wk	1 y	—

reduction and internal fixation, 3 (2 with FD, 1 with UBC) had bone grafting of the lesion as well. Figure 1 shows the minimally displaced fracture of a patient with FD; the postoperative radiographs show screw fixation after open bone grafting (Figure 2). Two of the patients who underwent open reduction and internal fixation also were immobilized with a spica cast after surgery.

The patient with rhabdomyosarcoma was treated with closed reduction and percutaneous pinning. The 2 patients with fractures in the setting of osteomyelitis, and 1 additional patient with FD, underwent débridement of the lesion, bone grafting, and spica cast immobilization.

The patient with rhabdomyosarcoma died before union. The patient with osteopetrosis was lost to follow-up before the determination of union was made. Union occurred in all the other hips; there were no nonunions. Union was defined as progressive radiographic evidence of bony bridging with associated lack of clinical symptoms. Union occurred at a mean of 19 weeks (range, 5–46 weeks). One malunion occurred in the case of FD treated with bone grafting alone. This patient underwent osteotomy and correction with internal fixation at a later date.

Complications occurred in 6 of the 15 patients (complication rate, 40%). Clinically significant LLDs were found in 4 patients. One patient with FD had a recurrence of the femoral neck lesion with symptoms, though without fracture. In addition, the malunion mentioned previously was considered a complication. No patient developed AVN.

Mean radiographic follow-up was 4 years (range, 6 months–13 years). However, because of the time frame in which many of these fractures were treated, both preoperative and postoperative radiographs were available for analysis for only 8 of the 15 patients. Unfortunately, the other radiographs had been discarded at the warehouse used by our institution. Therefore, no meaningful analysis of the amount of displacement or the adequacy of the reduction could be determined with the remaining radiographs.

DISCUSSION

Pathologic fractures are not uncommon in children, especially in disease processes such as FD, UBC, and OI. However, pathologic fractures in the femoral neck are exceedingly rare. Most reports in the literature have either been isolated case reports, series of 5 cases or fewer, or cases that are part of a larger series that includes adult pathologic hip fractures. To our knowledge, the present article is the first report of a relatively large series of pathologic femoral neck fractures in a pediatric population.

Unfortunately, for adults, pathologic femoral neck fractures are much more common. These fractures commonly occur in the setting of primary malignancies, such as lymphoma and myeloma. However, adult pathologic hip fractures occur much more commonly in the setting of metastatic disease. The literature includes much on treatments, which include internal fixation, intramedullary fixation, and arthroplasty. However, because of concerns about children's growth and the more severe complication of AVN, treatment of pathologic hip fractures in children mandates different techniques and philosophies.

FD has received the most attention in the literature on these pediatric fractures. Enneking and Gearen³ reported on femoral neck insufficiency fractures in FD, with 6 pediatric patients treated with cortical bone grafting. Funk and Wells⁴ reported on 4 pediatric patients with FD, 2 of whom had pathologic femoral neck fractures; these patients were treated with cancellous bone grafting. Our series had 5 patients with FD—3 treated with bone grafting and internal fixation, 1 with bone grafting alone, and 1 simply with protected weight-bearing. This last patient ultimately went on to malunion; all the other patients with FD healed successfully. This outcome was very similar to that described in previous reports.^{3,4}

One striking feature of this study was the extended time required for union (mean, 19 weeks) for the overall

series—considerably longer than that typically seen in traumatic, pediatric femoral neck fractures. Both the parents and the physician should be cognizant of the long time required for healing in these pathologic fractures. Also, the complication rate of 40% was not insignificant. Most of the complications were minor but still clinically significant LLDs. Parents should also be made aware of this risk before initiation of treatment.

This study certainly has limitations and weaknesses. First, retrospective reviews by their nature have limitations and biases. Second, not all initial radiographs were available for analysis, and so conclusions drawn from the amount of initial displacement and adequacy of reduction are limited. Third, missing radiographs limited what could have been learned from more interesting examples. Fourth, the diversity of the fractures and pathologic processes in the study limits any generalizable conclusions about treatment options and outcomes; the data may be applied only to one specific type of pathologic fracture. However, we grouped these fractures into a single case-series (instead of several case reports) so we could discuss the overall topic of pathologic hip fractures in children and describe the various presentations, treatment options, and outcomes in such a series.

Our study results demonstrate that pathologic femoral neck fractures seldom occur in children. Pediatric patients who present with a pathologic hip fracture are at significant risk for complications and prolonged time to union. Physicians and family should be alerted to the prolonged course involved in treating these fractures to union.

AUTHORS' DISCLOSURE STATEMENT

The authors report no actual or potential conflict of interest in relation to this article.

REFERENCES

1. Swanson KC, Pritchard DJ, Sim FH. Surgical treatment of metastatic disease of the femur. *J Am Acad Orthop Surg*. 2000;8(1):56-65.
2. Erol B, Pill SG, Guttenberg ME, Meyer JS, Dormans JP. Pathologic hip fracture in a 4-year-old boy. *Clin Orthop*. 2002;(403):264-273.
3. Enneking WF, Gearen PF. Fibrous dysplasia of the femoral neck: treatment by cortical bone-grafting. *J Bone Joint Surg Am*. 1986;68(9):1415-1422.
4. Funk FJ, Wells RE. Hip problems in fibrous dysplasia. *Clin Orthop*. 1973;(90):77-82.

5. Goldman AB, Jacobs B. Femoral neck fracture complicating Gaucher disease in children. *Skeletal Radiol*. 1984;12(3):162-168.
6. Bennett JT, Alexander HH, Morrissy RT. Parathyroid adenoma presenting as a pathologic fracture of the femoral neck in an adolescent. *J Pediatr Orthop*. 1986;6(4):473-476.
7. Taneda H, Azuma H. Avascular necrosis of the femoral epiphysis complicating a minimally displaced fracture of solitary bone cyst of the neck of the femur in a child. A case report. *Clin Orthop*. 1994;(304):172-175.
8. Adler CP. Solid aneurysmal bone cyst with pathologic bone fracture. *Skeletal Radiol*. 1995;24(3):214-216.
9. Taroni A, Faccini R, Ventre T. Pathologic fracture on bone cyst of the femoral neck treated by external fixator. Description of one case. *Chir Organi Mov*. 1997;82(1):91-94.
10. Azouz EM, Karamitsos C, Reed MH, Baker L, Kozlowski K, Hoeffel JC. Type and complications of femoral neck fractures in children. *Pediatr Radiol*. 1993;23(6):415-420.

COMMENTARY

This study by Shrader and colleagues of 15 young patients with pathologic femoral neck fractures points out the wide variety of lesions and metabolic bone problems that can lead to pathologic fractures. It also emphasizes the complications that can occur even with appropriate treatment: osteonecrosis, malunion, leg-length discrepancy. Prophylactic fixation before pathologic fracture would be ideal, but, as these authors reported, the fracture often is the first sign of a pathologic process (10 of their 15 patients).

In an earlier series reported by Ortiz and colleagues¹ of 88 pathological fractures in children, 18 of which were in the proximal femur, the authors noted the importance of determining the etiology of pathologic fracture because fracture treatment may be affected by treatment of the primary pathology, such as with malignant bone tumors.

Treatment of any pathologic fracture, especially in a young, growing patient, must be customized as to the choice of operative or nonoperative treatment, implant choice, use of bone grafting, and postoperative immobilization to obtain fracture union and to avoid complications, such as osteonecrosis and leg-length discrepancy.

James H. Beaty, MD
Memphis, Tennessee

Reference

1. Ortiz EJ, Isler MH, Navia JE, Canosa R. Pathologic fractures in children. *Clin Orthop*. 2005;(432):116-126.

This paper will be judged for the Resident Writer's Award.
