

Radiographic Assessment of Sternal Notch Level and Its Significance in Approaching the Upper Thoracic Spine

Palaniappan Lakshmanan, MS (Orth), AFRCS, FRCS (Orth), Kathleen Lyons, FRCR, Paul Rhys Davies, FRCS, FRCS (Orth), John P. Howes, FRCS, FRCS (Orth), and Sashin Ahuja, MS (Orth), FRCS, FRCS (Orth)

Abstract

In this retrospective study, we used anteroposterior plain radiographs of the neck to analyze sternal notch level in relation to the upper thoracic spine and to assess the usefulness of this relation in deciding how to approach the upper thoracic spine.

We reviewed 53 patients' anteroposterior plain radiographs of the cervicothoracic spine and thoracic magnetic resonance imaging (MRI) scans. On the plain radiographs, we drew a horizontal line joining the lower-fifth edge of the medial end of the 2 clavicles; on the midsagittal thoracic MRI scans, we drew a tangential line to the sternal notch. Then we noted the vertebral level of the 2 lines.

In all cases, the horizontal line on the plain radiographs and the tangential line on the MRI scans corresponded to each other without discrepancy. We evaluated this method in a patient with a fractured T3 vertebral body, in whom a satisfactory procedure was performed using low anterior cervical spine approach.

As the level of sternal notch is found to be present below the level of T2 and T3 radiologically in most cases, a low cervical approach can be contemplated in most patients with upper thoracic spine pathology depending on their sternal level as determined by preoperative radiographs. MRI scans are not needed to decide the approach, as it can be assessed with plain radiographs alone, as shown in this study.

Surgical approach to the upper thoracic spine has always been difficult.¹⁻⁸ It involves major procedures, such as sternotomy and thoracotomy, which are associated with high morbidity and mortality. It

was recently shown that, on midsagittal thoracic magnetic resonance imaging (MRI) scan, a tangential line drawn on the upper limit of the sternal notch and then extended bisected the upper thoracic spine to a level up to the lower border of T4 in some cases and up to T3 in most cases.⁶ It was also illustrated that such a line represents the level of upper thoracic vertebra accessible with a low anterior cervical approach without sternotomy or thoracotomy. Further, this approach is familiar to all spine surgeons and is associated with low morbidity and mortality.

We used anteroposterior (AP) plain radiographs of the neck to analyze sternal notch level in relation to the upper thoracic spine and to assess the usefulness of this relation in deciding how to approach the upper thoracic spine. This method was then used in a patient to assess the importance of AP radiographs and MRI scans in preoperative planning of the approach.

MATERIAL AND METHODS

This retrospective study involved 53 patients with AP plain radiographs of the cervicothoracic spine and thoracic MRI scans.

On each midsagittal MRI scan, a tangential line to the upper border of the manubrium (sternal notch) was extended posteriorly to intersect the spine, and the intersection level was recorded. This level represented the level of upper thoracic vertebra accessible with a low anterior cervical approach without sternotomy or thoracotomy.⁶ When the manubrium sternum was not clearly visible on T₂-weighted MRI scan, then either a T₁-weighted or a short tau inversion recovery sequence midsagittal MRI scan was used to draw the tangential line.

On each cervicothoracic spine AP plain radiograph, a horizontal line joining the lower-fifth edge of the medial end of the 2 clavicles was drawn, and its level in relation to the upper thoracic spine was noted.

For each patient, the intersection levels on MRI scan and radiograph were compared. Patient positioning for the cervicothoracic region was similar to the basic AP projection of the cervical spine, but the radiograph was positioned to include the area from the fourth cervical vertebra to the fourth thoracic vertebra with the center at the sternal notch level.

This method was evaluated in a patient with a fractured T3 vertebral body. Preoperative midsagittal T₂-weighted MRI scan showed that the tangential line lay

Dr. Lakshmanan is Specialist Registrar, Trauma and Orthopaedics, Newcastle General Hospital, Newcastle-Upon-Tyne, United Kingdom.

Dr. Lyons is Consultant Radiologist, and Dr. Rhys Davies, Dr. Howes, and Dr. Ahuja are Consultant Spinal Surgeons, University Hospital of Wales, Cardiff, United Kingdom.

Address correspondence to: Palaniappan Lakshmanan, 36, Greenhills, Killingworth, Newcastle-Upon-Tyne, NE12 5BB, United Kingdom (tel, 44-0-191-216-0109; fax, 44-0-709-287-3857; e-mail, lakunns@gmail.com).

Am J Orthop. 2009;38(4):E71-E74. Copyright, Quadrant HealthCom Inc. 2009. All rights reserved.

Table. Sternal Notch Level in Relation to Upper Thoracic Vertebral Bodies in 53 Cases as Determined by Plain Radiographs and Midsagittal T₂-Weighted Magnetic Resonance Imaging Scans

Sternal Notch Level	n	%
T1	2	3.8
T1–T2	13	24.5
T2	8	15.1
T2–T3	12	22.6
T3	13	24.5
T3–T4	4	7.6
T4 and below	1	1.9

below the fractured vertebra and intersected the T5 vertebral body in the upper half. Therefore, a low anterior cervical approach was performed to access the fractured T3 vertebral body.

RESULTS

There were 31 women and 22 men in this study. Mean age was 43.27 years (range, 19–77 years). The diagnosis was lower cervical spine spondylosis in 27 patients, cervical disc prolapse in 6 patients (1 of whom had C5–C6 disc prolapse plus C7–T1 disc bulge), congenital fusion in 1 patient, previous C4–C6 surgical fusion in 1 patient, plaque in spinal cord at C2–C3 level in 1 patient, fracture of T3 in 1 patient, C7–T1 tuberculous paraspinal abscess in 1 patient, mid and lower thoracic spine discitis in 4 patients, and no pathology in 11 patients.

Sternal notch level corresponded to the level of T2 and T3 in 62.2% of the cases: T2 in 15.1%, T2–T3 in 22.6%, and T3 in 24.5% (Table). In 2 cases, the body of T4 could be seen cranial to the tangential line to sternal notch. In all

cases, the C7 vertebral body lay cranial to the suprasternal level; in 3 cases, only up to the T1 vertebral body could be visualized suprasternally.

In all cases, the horizontal line on the plain radiographs of the cervicothoracic spine and the tangential line on the midsagittal thoracic MRI scans corresponded to each other without discrepancy (Figures 1, 2). In the patient in whom the fractured vertebra lay cranial to the sternal notch on preoperative MRI scans, the low anterior cervical approach yielded good exposure up to the lower body of T4—exposure that allowed us to perform the planned procedure with stabilization from T2–T4 using Synex (Synthes Spine, Welwyn Garden City, United Kingdom) and cervical spine locking plate (Figure 3).

DISCUSSION

In most cases, an anterior approach to the vertebral body is preferred, as the pathology is anterior, and surgery can be directed against the pathologic lesion through an anterior surgical approach. Since the advent of new technologies, more

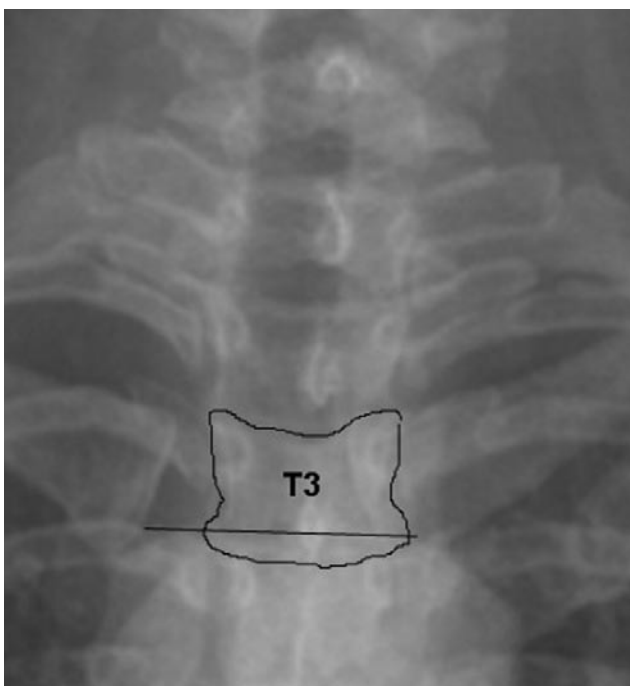


Figure 1. Anteroposterior radiograph shows biconvex line at lower fifth of medial end intersecting T3 body.

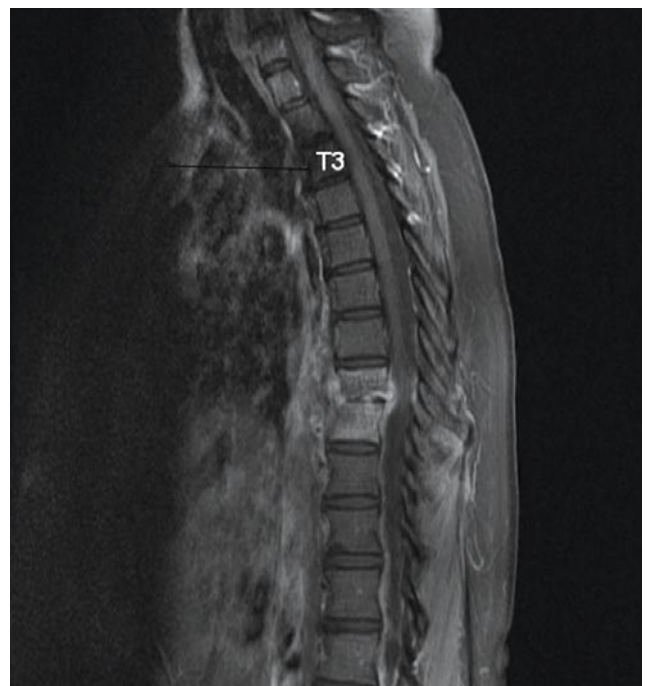

Figure 2. Midsagittal T₁-weighted magnetic resonance imaging scan of same patient (Figure 1) shows tangential line to suprasternal notch intersecting T3 body.

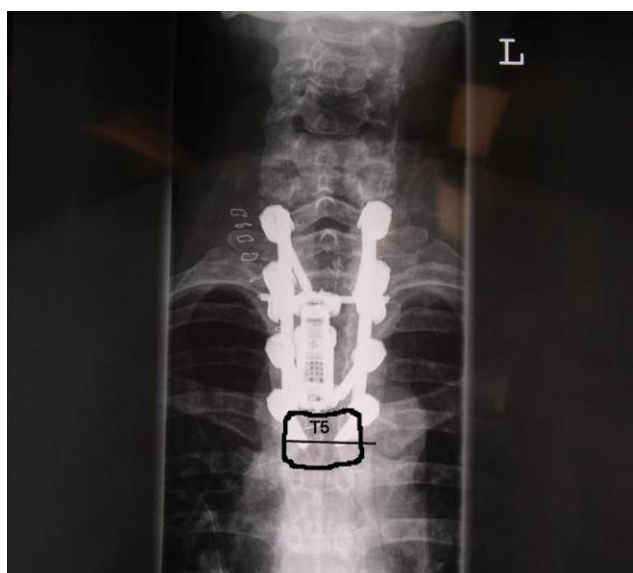

Figure 3. Postoperative radiograph shows use of Synex (Synthes Spine, Welwyn Garden City, United Kingdom) and cervical spine locking plate for fractured T3 vertebral body and low anterior cervical approach where line intersects T5 vertebral body. Posterior pedicle screw instrumentation was used to supplement anterior fixation. Reproduced with permission from: Lakshmanan P, Ahmed S, Al-Maiyah M, Lyons K, Davies PR, Howes J, Ahuja S. The low anterior cervical approach to the upper thoracic vertebrae: a decision by preoperative MR imaging. *Diagn Interv Radiol.* 2007;13(1):30-32.

pathologies related to the upper thoracic spine have been diagnosed, confirmed, and surgically addressed. Technically, exposing the upper thoracic spine is always a challenge.

In most cases, presence of the aortic arch and great vessels significantly impairs accessing the upper thoracic vertebrae. Further, there are anatomical constraints, such as presence of sternum anteriorly and physiologic transition of cervical lordosis to thoracic kyphosis.¹

Turner and Webb⁸ described a surgical exposure to the upper thoracic vertebra using posterior thoracotomy, particularly in the elderly. The lateral extracavitary approach was also described,⁷ but the scapula limited the exposure. Lazenec and colleagues⁵ advocated partial cervicosternotomy, which offered direct access to the upper thoracic vertebrae without involving the reconstruction problems caused by unilateral or bilateral sternoclaviculotomies.

Gieger and colleagues⁴ proposed the simple anterior cervical approach to the upper thoracic vertebrae. This is a familiar approach to the lower cervical spine. However, the level of the upper thoracic vertebra that can be exposed suprasternally varies by individual.

As the frequency of visualizing T2 and T3 suprasternally is high, a low cervical approach can be contemplated for most patients with upper thoracic spine pathology. However, in each case, the level of the vertebral body in the upper thoracic spine in relation to the sternal notch should be ascertained before surgery.

Sharan and colleagues⁶ evaluated 106 MRI scans to visualize the upper thoracic spine and determine its relation

to the sternal notch. They found that, in 7 cases, midsagittal MRI scans were useful in ascertaining the feasibility of approaching the upper thoracic spine without sternotomy or thoracotomy. Saturation bands are routinely used in midsagittal T₂-weighted MRI scans to decrease movement artifact. These bands obscure visualization of the sternum in some cases. This does not usually matter when the MRI scan is performed only to assess the lesion in the upper thoracic spine. In addition, Fraser and colleagues³ showed that the instrument manubrial thoracic distance correlated most reliably with the surgeon's choice of the anterior approach to the cervicothoracic junction using preoperative MRI scans.

In all our cases, the radiographic biclavicular line bisected the same vertebra as the tangential line to the suprasternal notch on the MRI scan. The technique that we have described is simple, readily available at all hospitals, and cost-effective (the cost of a radiograph is much less than that of an MRI scan).

We used the lower fifth of the medial end of the clavicle as the height of the sternal notch, as in most cases it is difficult to clearly visualize the upper edge of the manubrium on cervical spine plain radiographs. Cervical spine lateral radiographs may prove to be more useful but may be limited in that the upper thoracic vertebral bodies are not clearly visualized on most radiographs. The other alternative to plain radiographs and MRI scans in assessing sternal notch level may be a computed tomography sagittal section, which can clearly show both the sternal notch and the upper thoracic spine.

In the present study, we found that loss of lordosis in the cervical spine may not affect the relation of the sternal notch to the vertebral level measured using sagittal MRI scan or AP plain radiograph, as most patients in this study had cervical spondylosis and in most patients there were different degrees of loss of lordosis in the cervical spine. In spite of the different degree of loss of lordosis in the cervical spine in each patient, sternal notch level in relation to vertebral level, found by cervicothoracic spine AP plain radiograph, is not different from that assessed by midsagittal MRI scan.

Our study has 2 limitations. As most of the radiographs were taken in the normal position, it is difficult to know the effect of using a hard cervical collar or a spine board in trauma patients on the sternal notch level in relation to the vertebral level on AP plain radiographs. However, as the movement (ie, flexion or extension) occurs in the cervical spine and not in the upper thoracic spine, theoretically it should not alter sternal notch level in relation to vertebral level. When the x-ray tube is positioned much higher or lower than for a normal cervicothoracic spine radiograph, it can alter the sternal notch level in relation to the vertebral level; however, such a radiograph cannot be termed a proper AP cervicothoracic spine radiograph. The second limitation is that this study was based entirely on the study performed by Sharan and colleagues,⁶ who performed upper thoracic spine surgery using preopera-

tive MRI scans and the relation to the sternal notch using a tangential line in 7 patients. We performed surgery on only 1 patient. Our study showed that sternal notch level in relation to upper thoracic spine is the same in both techniques (ie, assessment with AP cervicothoracic spine radiographs and midsagittal MRI scans of the upper thoracic spine).

As in the study by Sharan and colleagues,⁶ we found that sternal notch level corresponds to the level of T2 and T3 in 62.2% of cases. In conclusion, as the level of sternal notch is found to be present below the level of T2 and T3 radiologically in most cases, a low cervical approach can be contemplated in most patients with upper thoracic spine pathology depending on their sternal level as determined by preoperative radiographs. MRI scans are not needed to decide the approach, as it can be assessed with plain radiographs alone, as shown in this study.

AUTHORS' DISCLOSURE STATEMENT

The authors report no actual or potential conflict of interest in relation to this article.

REFERENCES

1. Capener N. The evolution of rhachotomy. *J Bone Joint Surg Br.* 1954;36(2):173-179.
2. Charles R, Govender S. Anterior approach to the upper thoracic vertebra. *J Bone Joint Surg Br.* 1989;71(1):81-84.
3. Fraser JF, Diwan AD, Peterson M, et al. Preoperative magnetic resonance imaging screening for a surgical decision regarding the approach for anterior spine fusion at the cervicothoracic junction. *Spine.* 2002;27(7):675-681.
4. Gieger M, Roth PA, Wu JK. The anterior cervical approach to the cervicothoracic junction. *Neurosurgery.* 1995;37(4):709-710.
5. Lazennec JY, Roy-Camille R, Guerin-Surville H, Saillant G, Luzzati A. Partial cervicosternotomy: a useful anterior surgical approach to the cervicothoracic junction. *Ital J Orthop Traumatol.* 1993;19(1):19-23.
6. Sharan AD, Przybylski GJ, Tartaglino L. Approaching the upper thoracic vertebrae without sternotomy or thoracotomy: a radiographic analysis with clinical application. *Spine.* 2000;25(8):910-916.
7. Sundaresan N, Shah J, Feghali JG. A transsternal approach to the upper thoracic vertebrae. *Am J Surg.* 1984;148(4):473-477.
8. Turner PL, Webb JK. A surgical approach to the upper thoracic spine. *J Bone Joint Surg Br.* 1987;69(4):542-544.

This paper will be judged for the Resident Writer's Award.
