

Arthroscopic Rotator Cuff Repair With Biceps Tendon Augmentation

Jonathan T. Nassos, MD, and Steven C. Chudik, MD

ABSTRACT

Arthroscopic rotator cuff repair has become an increasingly popular treatment for rotator cuff tears. For orthopedic surgeons, treating large to massive rotator cuff tears is challenging in many ways. Patients with this pathology do not have the same healing rates and clinical outcomes as patients with smaller tears. Some surgeons have augmented repair with collagen-based grafts, but the success of this method has been limited.

The same patient population may have concomitant biceps tendon pathology. Biceps tenotomy and biceps tenodesis are procedures in the surgeon's treatment armamentarium. Rotator cuff repair and biceps tenodesis or tenotomy are commonly performed simultaneously.

In this article, we describe a technique that incorporates biceps tenodesis into double-row rotator cuff repair with the goal of providing more collagen and, ultimately, more healing potential.

The popularity of arthroscopic rotator cuff repair has increased in recent years, partly because of reports of good clinical outcomes and tendon healing rates.¹⁻³ Unfortunately, repairs of large to massive tears do not necessarily have the same success, and retear rates are higher in this patient population.⁴ New collagen-based grafts are becoming available to augment rotator cuff tears. These products, however, may be costly and may produce intense inflammatory reactions that require additional surgical procedures, as some authors have reported.⁵

In this same group of patients, concomitant biceps pathology is often found. There are different treatments for full and partial biceps tears, including débridement, tenotomy, and tenodesis, and each has its advantages

and disadvantages.⁶ An open rotator cuff repair technique that uses the biceps tendon to augment the repair has been reported to have improved rates of postoperative repair integrity.⁷ To our knowledge, an arthroscopic approach to this technique has not been described.

In this article, we describe a technique that incorporates biceps tenodesis into double-row rotator cuff repair with the goal of providing more collagen to support the repair (Figure 1).

TECHNIQUE

Standard beach-chair or lateral positioning is used for the shoulder arthroscopy. Dr. Chudik prefers beach-chair positioning after interscalene block, induction of general anesthesia, and administration of a dose of an intravenous cephalosporin. Standard posterior and anterior arthroscopic portals are made for complete diagnostic arthroscopy of the shoulder joint. A lateral subacromial portal is then made with needle localization, and débridement of the footprint of the supraspinatus and the undersurface of the rotator cuff tear is performed with a non-aggressive shaver. An 18-gauge spinal needle is introduced through the rotator cuff defect from the lateral portal and is passed through the proximal end of the biceps tendon. The free end of a 0 or 2-0 polypropylene suture is shuttled through the biceps tendon via the spinal needle and retrieved out the cuff defect and lateral portal with an arthroscopic grasper. From either the anterior or lateral arthroscopic portal, an arthroscopic basket is used to transect the biceps tendon just proximal to the polypropylene suture. The biceps tendon is allowed to retract distally into the groove, and the tagging polypropylene suture is shuttled to and parked in the anterior portal.

After a coracoacromial arch-sparing subacromial exposure is performed, the rotator cuff is repaired with a double-row repair configuration with double-loaded medial and lateral anchors. The medial sutures are passed in mattress fashion and the lateral sutures in interrupted fashion. The sutures from the medial anchor are tied, and those from the lateral anchors are parked in the lateral portal adjacent to the clear tying cannula, which is 8.25 mm in diameter. The arthroscope is temporarily placed through the clear tying cannula in the lateral portal while a suture retriever is introduced from the posterior portal running between the medial suture limbs (previously passed through the rotator cuff) and the

Dr. Nassos is Attending Orthopaedic Surgeon, G & T Orthopaedics, Chicago, Illinois. He was a resident at Loyola University Medical Center, Maywood, Illinois, at the time the article was written.

Dr. Chudik is Director of the Orthopaedic Sports Performance Institute, Westmont, Illinois; Clinical Assistant Professor, Loyola University Medical Center, Maywood, Illinois; and Orthopaedic Surgeon, Hinsdale Orthopaedic Associates, Hinsdale, Illinois.

Address correspondence to: Jonathan T. Nassos, MD, G & T Orthopaedics, 6374 North Lincoln Avenue, Suite 301, Chicago, IL 60659 (tel, 773-463-2377; e-mail, jtn22@aol.com).

Am J Orthop. 2009;38(6):279-281. Copyright, Quadrant HealthCom Inc. 2009. All rights reserved.

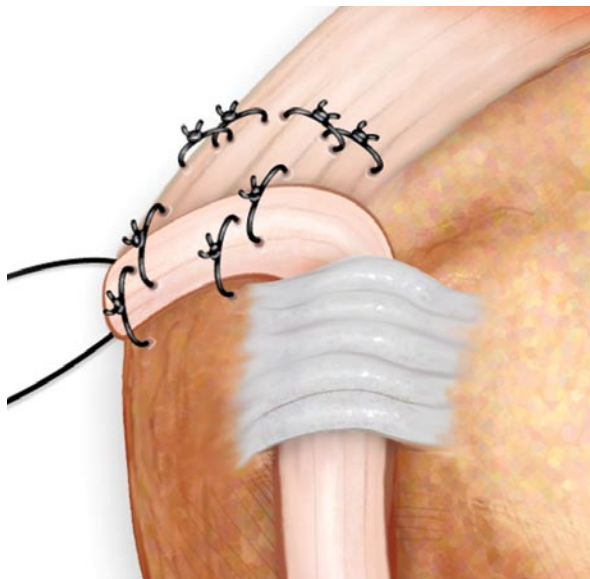


Figure 1. Viewed from anterior aspect of right shoulder, this schematic demonstrates augmentation of double-row rotator cuff repair with long head of biceps tendon. Copyright 2008, Patrick Carrico.

lateral suture limbs from the lateral anchors. The polypropylene suture tagging the proximal cut end of the biceps tendon is grasped with the retriever and drawn out the posterior portal to pull the biceps tendon between the medial and lateral suture limbs of the lateral anchors. A hemostat is placed on the polypropylene at the opening to the posterior portal to position the biceps tendon over the rotator cuff

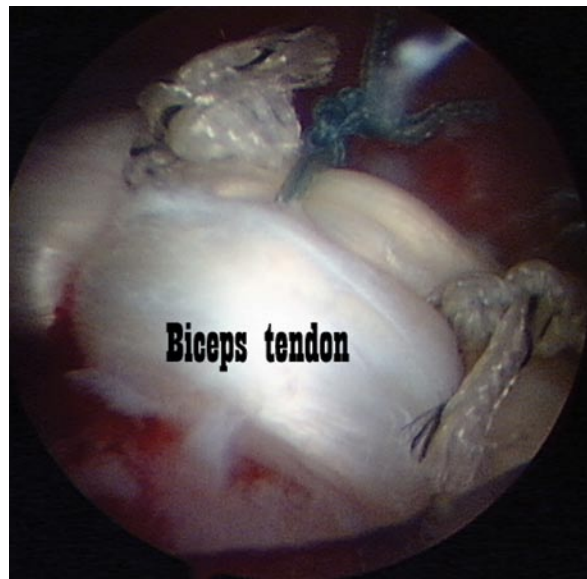


Figure 2. Arthroscopic biceps augmentation of double-row rotator cuff repair. After lateral row sutures are passed through cuff tendon in interrupted fashion, sutures are passed through biceps tendon and then tied.

then retrieved through the lateral clear tying cannula, and the 2 suture limbs are tied arthroscopically to create a single interrupted stitch through the rotator cuff and biceps. The same steps are repeated with the lateral (not passed through the rotator cuff) suture limb from the posterior suture of the anterolateral anchor, which allows these interrupted sutures to capture alternating lateral and medial aspects of the biceps tendon

“The biceps tendon provides a local autologous source of collagen graft that can be performed arthroscopically without an additional exposure or implant.”

repair site at its proper length–tension relationship. The arthroscope is returned to the posterior portal, and a suture-shuttling device (spinal needle, Linvatec Spectrum [ConMed Linvatec, Largo, Fla.], or commercially available suture-shuttling device) is introduced through the 8.25-mm clear cannula, and a polypropylene suture is passed through the biceps tendon at the same level as the passed medial suture limb of the most anterior suture from the anterolateral anchor. The polypropylene suture and the passed medial suture limb are retrieved through another small cannula in the anterior portal. A loop is created in the polypropylene to secure the suture limb from the anchor outside the anterior cannula. The polypropylene is withdrawn from the shoulder by pulling on its free end exposed from the lateral clear tying cannula to shuttle the medial suture limb through the biceps tendon. The lateral suture limb of the same most anterior suture from the anterolateral anchor is

in the repair. These steps are then repeated for all remaining anchors. If necessary, the sutures from the most posteromedial anchor (passed in mattress fashion through the cuff) can also be used to incorporate the biceps tendon into the rotator cuff repair. The repair is inspected from both the posterior and lateral portals before completion of the procedure (Figure 2).

DISCUSSION

Treating large to massive rotator cuff tears is a challenge. Given the degenerative nature of these tears and their propensity to heal incompletely, grafting or augmentation of repairs is desirable. Proximal biceps pathology is commonly associated with these larger tears and can be a significant source of pain, which is also commonly addressed during surgery. The biceps tendon provides a local autologous source of collagen graft that can be performed arthroscopically without an additional exposure or implant.

We have described an arthroscopic technique of augmenting a double-row repair of large to massive rotator cuff tears with the proximal biceps tendon. We have performed this procedure in 6 cases, and subjective and objective short-term outcomes have been satisfactory. There has been no clinical evidence of failure of the biceps tenodesis with regard to its cosmetic appearance, strength, or symptoms when tested with manual resisted flexion and supination. Studies of the long-term outcomes and integrity of the rotator cuff repair are necessary.

CONCLUSIONS

Arthroscopic augmentation of large to massive rotator cuff repairs with the proximal biceps tendon are technically challenging but offer an attractive potential solution to this difficult clinical problem.

AUTHORS' DISCLOSURE STATEMENT

The authors report no actual or potential conflict of interest in relation to this article.

REFERENCES

1. Boileau P, Brassart N, Watkinson DJ, Carles M, Hatzidakis AM, Krishnan SG. Arthroscopic repair of full-thickness tears of the supraspinatus: does the tendon really heal? *J Bone Joint Surg Am.* 2005;87(6):1229-1240.
2. Liem D, Lichtenberg S, Magosch P, Habermeyer P. Clinical outcome and tendon integrity of arthroscopic versus mini-open supraspinatus tendon repair: a magnetic resonance imaging-controlled matched-pair analysis. *Arthroscopy.* 2007;23(5):514-521.
3. Youm T, Murray DH, Kubiak EN, Rokito AS, Zuckerman JD. Arthroscopic versus mini-open rotator cuff repair: a comparison of clinical outcomes and patient satisfaction. *J Shoulder Elbow Surg.* 2005;14(5):455-459.
4. Galatz LM, Ball CM, Teefey SA, Middleton WD, Yamaguchi K. The outcome and repair integrity of completely arthroscopically repaired large and massive rotator cuff tears. *J Bone Joint Surg Am.* 2004;86(2):219-224.
5. Walton JR, Bowman NK, Khatib Y, Linklater J, Murrell GA. Restore orthobiologic implant: not recommended for augmentation of rotator cuff repairs. *J Bone Joint Surg Am.* 2007;89(4):786-791.
6. Boileau P, Baqué F, Valerio L, Ahrens P, Chuinard C, Trojani C. Isolated arthroscopic biceps tenotomy or tenodesis improves symptoms in patients with massive irreparable rotator cuff tears. *J Bone Joint Surg Am.* 2007;89(4):747-757.
7. Pavlidis T, Ganten M, Lehner B, Dux M, Loew M. Tenoplasty of the long head of the biceps in massive rotator cuff tear [in German]. *Z Orthop Ihre Grenzgeb.* 2003;141(2):177-181.

This paper will be judged for the Resident Writer's Award.

ERRATA

In the article entitled "Impact of Erythropoietin on Allogenic Blood Exposure in Orthopedic Surgery," by Jennifer E. Santoro, PharmD, Robert K. Eastlack, MD, James M. Mirocha, PhD, and William D. Bugbee, MD, published in *Am J Orthop* 2007;36(11):600-604, the third author was listed with the incorrect degree. The correct listing for this author is "James M. Mirocha, MS."

In the article entitled "Sacral Stress Fractures in Children," by Mangla J, Young JO, Thomas T, and Karaikovic EE, published in *Am J Orthop* 2009;38(5):232-236, the second author was listed with the incorrect middle initial. The correct listing for this author is "Young JL."