

Structural Bone Allograft in Pediatric Foot Surgery

Philip D. Nowicki, MD, Chester M. Tylkowski, MD, Henry J. Iwinski, MD, Vishwas Talwalkar, MD, Janet L. Walker, MD, and Todd A. Milbrandt, MD, MS

Abstract

Structural bone allografts are used in a variety of surgical procedures, but only a few investigators have examined their use and associated complications in the pediatric population specifically.

In a retrospective review of pediatric foot procedures, we sought to determine types and rates of complications associated with structural bone allografts as well as time to incorporation of these allografts. Minimum follow-up was 12 months. Eighteen patients with 31 structural allografts were reviewed. The total complication rate was 7.1%, and the allograft incorporation rate was 90% (mean time after surgery, 9 months). Mean follow-up was 22 months. There were no pseudarthroses, nonunions, or fractures at the bone-graft sites. Structural bone allografts can be safely used in foot procedures in pediatric neuromuscular patients without major risk for complications, and their use can reduce autograft-harvest morbidity in pediatric patients with neuromuscular conditions.

One allografts, both structural and nonstructural, have been widely used in orthopedic surgery since the 1950s.¹ Structural allografts, which are used in a variety of orthopedic procedures, can produce satisfactory long-term clinical results. Areas of use include anterior spinal fusions in the cervical spine,² idiopathic scoliosis fusion,^{2,3} pelvic osteotomy,⁴ general foot and ankle procedures,⁵⁻⁹ revision total joint arthroplasty,¹⁰⁻¹² trauma,^{13,14} and tumor limb salvage reconstruction.^{15,16}

The main concern in using structural bone allografts is viral and bacterial transmission to and infection of the host.¹⁵ With current allografts, disease transmission is extremely low or not even evident, and, with modern

preparation techniques, there have been no reported cases of human immunodeficiency virus (HIV) or hepatitis B or C virus transmission from allografts since the early 1990s.¹ Other complications associated with allograft use include deep infection, graft resorption, malunion, delayed union, nonunion, graft collapse, and graft fatigue fracture.^{4,7,17,18}

Only a few investigators have examined the use of allografts in pediatric orthopedic surgery patients, and their studies have found few complications and satisfactory results in terms of fusion rates, correction maintenance, and postoperative graft fractures.^{2,4,6,8} Studies of structural allograft in pediatric orthopedics have focused on foot reconstruction and postoperative functional results⁶⁻⁸ but not solely on complication or graft incorporation rates.

The main goals of our retrospective review were to determine time to incorporation of structural allografts and to examine any clinical or radiologic complications related to the use of structural allografts in pediatric foot surgery.

METHODS

We reviewed all foot reconstructions performed between May 2004 and June 2007 at Shriners Hospital for Children in Lexington, Kentucky, to identify those that used cadaveric structural bone allograft and had a minimum follow-up of 12 months. Patient charts were reviewed for age at time of surgery, sex, allograft type, associated underlying conditions, type of surgery using the allograft, length of follow-up, and postoperative complications. Radiographs were reviewed by a single examiner (Dr. Nowicki) for graft extrusion, early graft resorption causing loss of surgical alignment, postsurgical allograft fracture, and time to graft incorporation. Grafts were considered incorporated when there was no pain in the affected foot and when trabecular bone from normal bone bridged the allograft bone on both sides of the graft with no further trabecular bridging or changes apparent on subsequent follow-up radiographs (Figure). Institutional review board approval was obtained for this study. Informed consent was waived given the minimal risk to patients.

RESULTS

Eighteen patients (31 allografts) met the criteria for study inclusion. Thirteen of these patients underwent bilateral procedures, and 5 underwent a unilateral procedure.

Dr. Nowicki is Fellow, Pediatric Orthopaedics, Department of Orthopaedic Surgery, University of Michigan Health System, Ann Arbor, Michigan.

Dr. Tylkowski is Chief of Staff, Dr. Iwinski is Assistant Chief of Staff, and Drs. Talwalkar, Walker, and Milbrandt are Attending Physicians, Shriners Hospital for Children, Lexington, Kentucky.

Address correspondence to: Todd A. Milbrandt, MD, MS, Shriners Hospital for Children, 1900 Richmond Rd, Lexington, KY 40502 (tel, 859-266-2101; fax, 859-268-5636; e-mail, tmlbrandt@shrinenet.org).

Am J Orthop. 2010;39(5):238-240. Copyright Quadrant HealthCom Inc. 2010. All rights reserved.

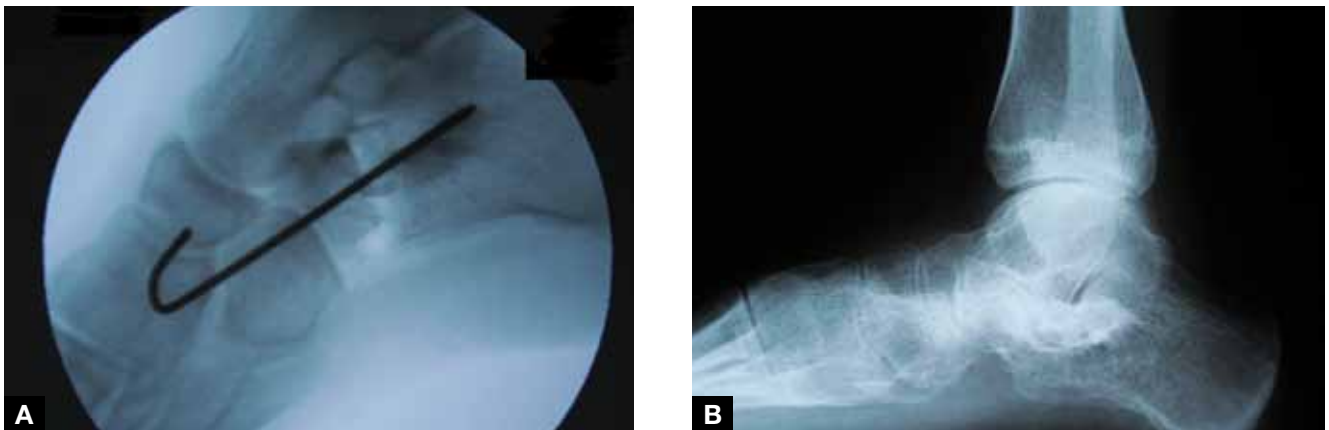


Figure. (A) Intraoperative radiograph of a lateral column lengthening. Note the good overall position of the allograft within the calcaneal osteotomy. (B) Postoperative radiograph taken at 5 months. The allograft has completely incorporated into the surrounding host bone with sclerosis as determined by incorporation and trabecular bridging from host bone to allograft bone on both sides of the allograft.

Procedures were performed for pes planovalgus deformities by multiple surgeons. Of the 18 patients, 13 (72%) were male and 5 (28%) female. Thirteen grafts (8 patients) were used for lateral column lengthening and 18 grafts (10 patients) for extra-articular subtalar arthrodesis. Seventeen (94%) of the 18 patients had an underlying neuromuscular disorder (eg, cerebral palsy, tuberous sclerosis, familial spastic paraparesis, Charcot-Marie-Tooth disease, Angelman syndrome, traumatic brain injury). All allografts were tricortical iliac crest wedges, except for 2 femoral diaphyseal segments used for bilateral extra-articular subtalar arthrodesis in 1 patient. Mean age at surgery was 11 years, 0 month (range, 4 years, 9 months to 14 years, 6 months). Mean follow-up was 22 months (range, 12-50 months).

Twenty-eight of the 31 allografts incorporated radiographically into the surrounding host bone. Mean time to graft incorporation was 9.2 months (range, 1-22 months). The other 3 allografts were lost to follow-up but had demonstrated early radiographic incorporation at time of last radiographic follow-up. The 2 patients with these 3 grafts each returned for a single postoperative visit 4 weeks after surgery. Given the incomplete radiographic follow-up for these grafts, incorporation time and development of any pseudarthroses or nonunions could not be determined, but their numbers were included in the incorporation data for an intent-to-treat analysis.

There were 2 complications among the 28 grafts that incorporated radiographically, for a complication rate of 7.1%. One of the complications was a superficial wound dehiscence related to the postoperative cast, and the other was a graft dislodgement found 6 months after surgery. With local soft-tissue treatment and use of oral antibiotics, the dehiscence healed without consequence. The patient with the graft dislodgement was asymptomatic and was treated conservatively, with a brace; the allograft went on to heal and incorporate into the surrounding host bone 11 months after surgery. The 3 grafts that were lost to follow-up were not considered complications, as we could not definitively determine that incorporation failed to occur.

DISCUSSION

Structural bone allografts have been used in orthopedic surgery since the 1950s.¹ The advantage of structural allografts is that they are highly resistant to compression load failure and allow for load-bearing immediately after surgery.¹⁵ Use of structural allografts reduces autograft-harvest morbidity, which includes second incision, harvest-site pain, increased procedure time, and potential for limited amount of bone stock for the graft.⁴

As with autografts, allografts have many associated risks and complications, including viral transmission. The first reported case of HIV transmission from an allograft occurred in 1988 and was associated with a fresh-frozen allograft.¹ Since the early 1990s, when modern graft preparations were instituted, there has not been a single reported case of HIV or hepatitis B or C virus transmission from allograft bone.¹ Other complications associated with allograft are deep infection, early graft resorption, delayed union, pseudarthrosis, nonunion, malunion, graft collapse, and fracture.^{4,7,17,18}

Most structural allograft-autograft comparison studies have been conducted with adult populations. Structural allografts and autografts have been found equally efficacious in their union rates, particularly in foot and ankle surgery.^{5,9} Very few studies have focused on structural allograft use in the pediatric population, but structural allograft use has demonstrated success in anterior spinal fusion for idiopathic scoliosis,³ Pemberton pelvic osteotomies,⁴ lateral column lengthening,^{6,7} and subtalar arthrodesis.⁸ Although the studies on structural allograft use in pediatric orthopedics have demonstrated efficacy equal to that of autograft with respect to overall complication and union rates, none has specifically examined complications or graft incorporation rates related to structural allografts in this patient population.

Our patients' complication rate was 7.1%; there were 2 complications among 28 radiographically incorporated grafts. We removed 3 other grafts from the complications analysis because their follow-ups were incomplete, and we could not determine whether the grafts incorporated. We

used their numbers in the incorporation data for an intent-to-treat analysis to prevent selection bias. At a mean of 9 months, graft incorporation was 90%, a rate similar to that found by Mosca,⁶ who reported that all allografts used in his study on lateral column lengthening incorporated and healed within 12 months after surgery. Mosca also found that 2 of his 31 grafts demonstrated postoperative subluxation—similar to what we found in our study. Although Danko and colleagues⁷ noted that 29% of allografts collapsed in lateral column lengthening when the graft was placed as part of a calcaneocuboid fusion, no allografts collapsed when used with an intracalcaneal osteotomy. We found no allograft collapses in the present study, as all lateral column lengthenings used an intracalcaneal osteotomy. Examining subtalar joint arthrodesis using structural allograft, Senaran and colleagues⁸ noted that risk for nonunion and pseudarthrosis of grafts was small, approximately 2.7%, with 2% of patients requiring revision surgery to promote graft union. Three (9.7%) of our 31 grafts had inadequate follow-up, so we could not determine whether incorporation occurred. There were no fractures associated with any of the incorporated structural allografts in our series. One reason may be that surgical procedures in the foot are inherently stable given the various complex forces from the surrounding structures.

Problems with the present study are similar to those found in all noncontrolled retrospective cohort studies. There was no control group, but the goal of the study was focused not on functional outcomes, improvement of radiographic parameters, or comparisons of surgical procedures, but on describing the complications and graft incorporation rates associated with structural bone allografts in a pediatric population. Multiple surgeons were involved in this study, and follow-up and radiography protocols were not standardized. We evaluated only anteroposterior and lateral radiographs, as these studies were obtained for all patients to determine graft incorporation. It would have been ideal to also obtain oblique radiographs to evaluate bone-graft incorporation, particularly after lateral column lengthening. The chosen cohort was varied, but almost all patients had an underlying neuromuscular disorder. Despite this variance, foot deformities in neuromuscular patients are treated similarly, and these patients can benefit significantly when autograft harvest is unnecessary.

Graft incorporation is often difficult to determine with standard radiographs, particularly in the foot, where bony structures are positioned in complex 3-dimensional relationships creating bony and soft-tissue structural overlap. We considered allografts incorporated when the patient was asymptomatic (no pain in affected foot) and when trabecular bone or rim sclerosis bridged the allograft bone on both sides of the graft with no further trabecular bridging or changes apparent on subsequent follow-up radiographs. Computerized tomography scans

can potentially be used when there are doubts about graft incorporation, but none of the patients in the present cohort needed any such advanced imaging.

CONCLUSIONS

Structural bone allografts are safe to use in pediatric foot surgery patients with neuromuscular conditions; the risk for complications is low. Use of structural allografts in this patient population obviates the need for additional, painful procedures. Use of allografts allows for timely bony incorporation and postoperative healing in the pediatric neuromuscular population. Allograft incorporation into host bone is 90% or more, and grafts can be expected to incorporate by a mean of 9 months. As graft dislodgement is possible, it is imperative to obtain serial postoperative radiographs, including 3 views of the foot, to ensure that postoperative correction is maintained until healing occurs.

AUTHORS' DISCLOSURE STATEMENT

The authors report no actual or potential conflict of interest in relation to this article.

REFERENCES

1. Woolf SK, Gross RH. Perceptions of allograft safety and efficacy among spinal deformity surgeons. *J Pediatr Orthop*. 2001;21(6):767-771.
2. Buttermann GR, Glazer PA, Bradford DS. The use of bone allografts in the spine. *Clin Orthop*. 1996;(324):75-85.
3. Watkins RG 4th, Hussain N, Freeman BJ, Grevitt MP, Webb JK. Anterior instrumentation for thoracolumbar adolescent idiopathic scoliosis: do structural interbody grafts preserve sagittal alignment better than morselized rib autografts? *Spine*. 2006;31(20):2337-2342.
4. Kessler JI, Stevens PM, Smith JT, Carroll KL. Use of allografts in Pemberton osteotomies. *J Pediatr Orthop*. 2001;21(4):468-473.
5. Myerson MS, Neufeld SK, Uribe J. Fresh-frozen structural allografts in the foot and ankle. *J Bone Joint Surg Am*. 2005;87(1):113-120.
6. Mosca VS. Calcaneal lengthening for valgus deformity of the hindfoot. Results in children who had severe, symptomatic flatfoot and skewfoot. *J Bone Joint Surg Am*. 1995;77(4):500-512.
7. Danko AM, Allen B Jr, Pugh L, Stasikelis P. Early graft failure in lateral column lengthening. *J Pediatr Orthop*. 2004;24(6):716-720.
8. Senaran H, Nagai MK, Dabney KW, et al. Subtalar fusion in cerebral palsy patients: results of a new technique using corticocancellous allograft. In: *Proceedings, Pediatric Orthopedic Society of North America 2007 Annual Meeting*. Hollywood, CA: Pediatric Orthopaedic Society of North America; 2007:E-poster 2.
9. Dolan CM, Henning JA, Anderson JG, Bohay DR, Kornmesser MJ, Endres TJ. Randomized prospective study comparing tri-cortical iliac crest autograft to allograft in the lateral column lengthening component for operative correction of adult acquired flatfoot deformity. *Foot Ankle Int*. 2007;28(1):8-12.
10. Gross AE, Blackley H, Wong P, Saleh K, Woodgate I. The role of allografts in revision arthroplasty of the hip. *Inst Course Lect*. 2002;51:103-113.
11. Graham NM, Stockley I. The use of structural proximal femoral allografts in complex revision hip arthroplasty. *J Bone Joint Surg Br*. 2004;86(3):337-343.
12. Sporer SM, O'Rourke M, Chong P, Papprosky WG. The use of structural distal femoral allografts for acetabular reconstruction: surgical technique. *J Bone Joint Surg Am*. 2006;88(suppl 1):92-99.
13. Haddad FS, Duncan CP. Cortical onlay allograft struts in the treatment of periprosthetic femoral fractures. *Inst Course Lect*. 2003;52:291-300.
14. Muscolo DL, Ayerza MA, Aponte Tinao LA, Ranalletta M. Distal femur osteoarticular allograft reconstruction after grade III open fractures in pediatric patients. *J Orthop Trauma*. 2004;18(5):312-315.
15. Khan SN, Cammisa FP, Sandhu HS, Diwan AD, Girardi FP, Lane JM. The biology of bone grafting. *J Am Acad Orthop Surg*. 2005;13(1):77-86.
16. Moran SL, Shin AY, Bishop AT. The use of massive bone allograft with intramedullary free fibular flap for limb salvage in a pediatric and adolescent population. *Plast Reconstr Surg*. 2006;118(2):413-419.
17. Gazdag AR, Lane JM, Glaser D, Forster RA. Alternatives to autogenous bone graft: efficacy and indications. *J Am Acad Orthop Surg*. 1995;3(1):1-8.
18. Burchardt H. The biology of bone graft repair. *Clin Orthop*. 1983;(174):28-42.

This paper will be judged for the Resident Writer's Award.
