

Posterior Cruciate Ligament Resection for Ganglion Cyst and Associated Ligament Degeneration

Denis Nam, MD, Alec Macaulay, BS, Michael Cross, MD, Michael K. Shindle, MD, and Russell F. Warren, MD

Abstract

With increased use of magnetic resonance imaging (MRI) and arthroscopy, intra-articular ganglion cysts of the posterior cruciate ligament (PCL) have received more recognition as a possible cause of knee discomfort. Reported treatment options have ranged from ultrasound-guided cyst aspiration to arthroscopic cyst resection.

In this report, we present the case of a patient who, on MRI, was diagnosed with a symptomatic intrasubstance PCL ganglion that later, during surgery, demonstrated mucinous degeneration of the entire ligament. Treatment was complete resection of the PCL. Five years after surgery, the patient demonstrated excellent, asymptomatic knee function.

Although the best treatment for an intrasubstance PCL ganglion cyst that has caused degeneration of the entire ligament is unknown, PCL resection without reconstruction should be considered a viable option. It can result in a large increase in range of motion and function.

Investigators have reported numerous cases of intra-articular ganglion cysts of the knee, including those arising from the posterior cruciate ligament (PCL).¹⁻¹¹ In their review of 1767 consecutive patients referred for magnetic resonance imaging (MRI) of the knee, Bui-Mansfield and Youngberg³ found 23 patients with intra-articular ganglia, 8 of which were associated with the PCL.

Although awareness of intra-articular ganglion cysts of the knee has risen, controversies persist with respect

to their etiology, clinical significance, and management, as they can present in both symptomatic and asymptomatic patients.⁹ Krudwig and colleagues⁵ noted 85 cystic masses in almost 8000 knee arthroscopies. With only 9 of the 85 deemed symptomatic, they concluded that, though most ganglion cysts of the knee are incidental findings, they can occasionally cause discomfort and mechanical symptoms, depending on their location and size. Treatment options have included nonoperative management, arthroscopic cyst debridement or excision, and radiographically guided aspiration.²⁻¹⁰

In this report, we present the case of a patient who, on MRI, was diagnosed with a symptomatic intrasubstance PCL ganglion that later, during surgery, demonstrated mucinous degeneration of the entire ligament. Treatment was complete resection of the PCL. Five years after surgery, the patient demonstrated excellent, asymptomatic knee function. The patient provided written informed consent for print and electronic publication of this case report.

CASE REPORT

The patient was an otherwise healthy 62-year-old man with no significant past medical history and past surgical history of herniorrhaphy. He presented nonemergently to our institution in September 2004 with a 2-year history of progressive discomfort in the back of the left knee. He reported no acute trauma but noted pain in the posterior aspect of the knee, aggravated by running and increased knee flexion. He reported no history of swelling, popping, locking, instability, or subluxation, but noted occasional "buckling." The pain did not radiate down the leg but was isolated to the popliteal fossa. In addition, the patient denied any history of hip pain, back discomfort, or sciatica.

Earlier, in August 2003, an MRI of the knee showed an isolated tear of the medial meniscus with no other reported pathologic anomalies appreciated intra-articularly. The patient underwent an arthroscopic partial medial meniscectomy at an outside hospital. He now reported no symptomatic relief from the procedure. In March 2004, he received a cortisone injection to the knee. After only 2 weeks of symptomatic relief, the discomfort returned.

In September 2004, the patient underwent ultrasound-guided aspiration and injection of a 2×0.3-cm popliteal

Dr. Nam is Orthopaedic Surgery Resident, Hospital for Special Surgery, New York, New York.

Mr. Macaulay is Medical Student, Columbia University College of Physicians and Surgeons, New York, New York.

Dr. Cross and Dr. Shindle are Orthopaedic Surgery Residents and Dr. Warren is Professor of Orthopaedic Surgery, Hospital for Special Surgery.

Address correspondence to: Denis Nam, MD, Sports Medicine and Shoulder Service, Department of Orthopaedic Surgery, Hospital for Special Surgery, Weill Medical College of Cornell University, 535 E 70th St, New York, NY 10021 (tel, 917-596-0620; fax, 212-606-1477; e-mail, namd@hss.edu).

Am J Orthop. 2011;40(6):E110-E114. Copyright Quadrant HealthCom Inc. 2011. All rights reserved.

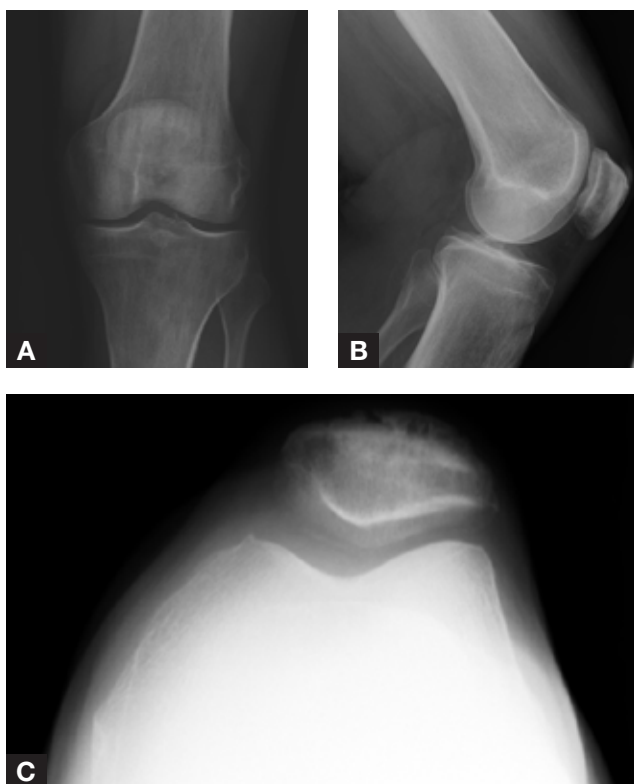


Figure 1. Preoperative anteroposterior (A), lateral (B), and Merchant (C) views of left knee show well-preserved joint spaces before surgery.

cyst at the posteromedial aspect of the knee. The cyst was decompressed under ultrasound visualization and then injected with triamcinolone acetonide 1 mL (40 mg/mL), bupivacaine 0.5 mL, and 1% lidocaine 0.5 mL. Again, the patient experienced only 2 weeks of symptomatic relief.

Radiographs of the knee in September 2004 showed minimal lateral spurring of the tibial spine but well-preserved joint spaces (Figure 1). At our institution, MRI of the knee showed an intercondylar notch ganglion with extensive involvement of the PCL, plus thickening and high signal intensity of the ligament related to intrasubstance ganglion formation (Figure 2). The intra-articular cyst extended from the PCL up to the posterior medial condyle. In addition, degeneration and blunting of the posterior horn and body of the medial meniscus were appreciated, consistent with prior debridement, along with a posterior parameniscal cyst. Mild cartilage fibrillation was also evident in all compartments, but there was no full-thickness defect or flap.

Physical examination revealed a slightly valgus alignment with passive flexion limited to 115° and pain at maximum flexion that worsened with attempts at increased flexion. The patient lacked full extension by approximately 5° and felt pain at this degree of extension. He had no medial or lateral joint-line tenderness; no varus, valgus, anterior, or posterior instability; and no signs of patellofemoral instability or discomfort. McMurray, Lachman, pivot shift, and reverse pivot shift tests were consistent

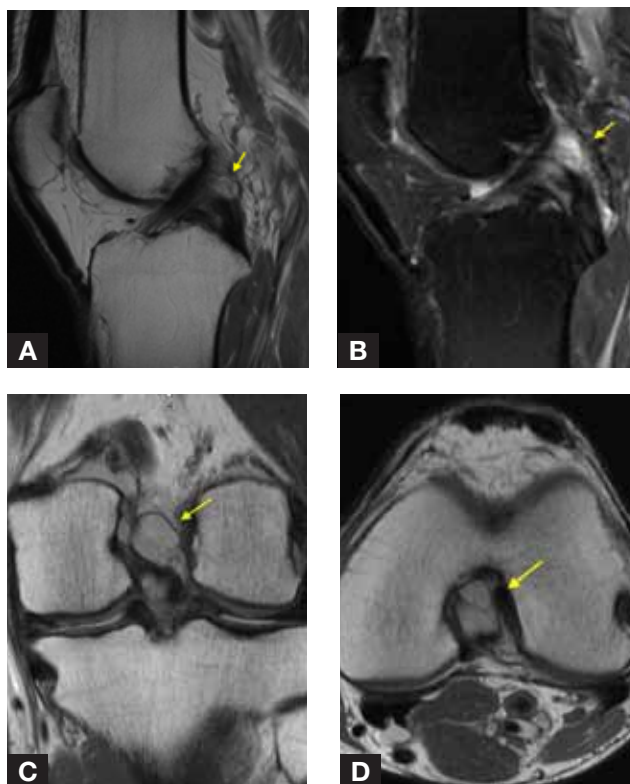


Figure 2. T₁-weighted sagittal (A), T₂-weighted sagittal (B), coronal (C), and axial (D) images show intercondylar notch ganglion with extensive involvement of posterior cruciate ligament (arrows).

with the contralateral, asymptomatic knee. The patient's neurovascular examination was unremarkable.

In December 2004, the patient underwent arthroscopic debridement of the PCL ganglion cyst along with complete resection of the PCL. He received a spinal anesthetic and was placed on the operating room table in the supine position. Examination under anesthesia was consistent for stable anterior, posterior, varus, and valgus stress testing, and the knee reached full extension and flexed to approximately 135°. Lachman, pivot shift, and reverse pivot shift tests were again negative. Through an anterolateral portal, diagnostic arthroscopy was performed. It revealed no loose bodies in the superior pouch or in the medial or lateral gutters; an intact patellofemoral joint with mild (grade 3) articular changes in the trochlea; and grade 2 changes in the medial facet of the patella.¹² The medial compartment had a longitudinal, degenerative-type tear in the posterior horn. An anteromedial portal was then created, and the undersurface of the tear was debrided using a combination of an arthroscopic biter and shaver. No significant chondral lesions of the femoral condyle or tibial plateau were appreciated, and no significant cystic fluid was observed on debridement of the posterior horn. The lateral compartment failed to demonstrate any significant cartilaginous changes in the femoral condyle or tibial plateau, and the lateral meniscus was intact.

The intercondylar notch was significant for a 1×1-cm cyst extending from the midsubstance of the PCL.

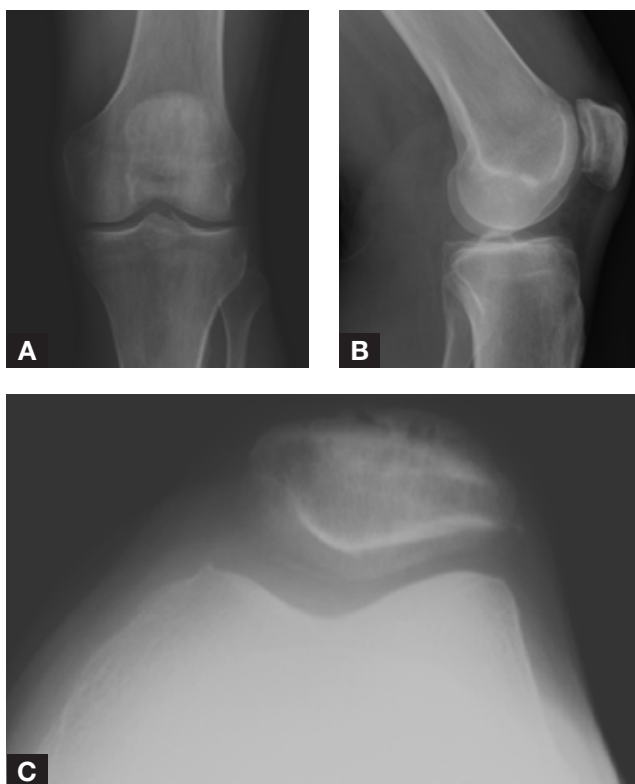


Figure 3. Anteroposterior (A), lateral (B), and Merchant (C) views of knee 5 years after surgery show well-maintained joint spaces.

Arthroscopic scissors were used to cut the stalk of the cyst, and the cyst was removed. The contents of the cyst revealed significant mucinous degeneration of fibrinous tissue. The remaining portion of the PCL was composed mainly of gelatinous, mucinous-type degenerative tissue interposed by a limited number of morphologically healthy-appearing fibers. Although on clinical examination the degenerative tissue and the few remaining healthy fibers appeared to provide posterior stability, the significant amount of mucinous tissue was a concern, as it was not clear if this tissue could increase the risk for cyst recurrence and generate pain in the future. Thus, the decision was made to completely debride the PCL. Radiofrequency ablation (ArthroCare, Austin, Texas) and a 5.5-mm full radius shaver were used in combination. PCL remnants were debrided completely to the footprint of the PCL on the tibia and the femur. Great care was taken throughout the resection to protect the anterior cruciate ligament (ACL), and several branches of the middle genicular artery were encountered and cauterized as necessary.

A posteromedial portal was then created under direct visualization. This portal was used to assess the posteromedial and posterolateral compartments. No significant cystic cavity or tissue was appreciated in those compartments. A 70° arthroscope was used to identify any remaining degenerative PCL fibers, which were then removed. After debridement and arthroscopic evaluation were completed, the joint was copiously lavaged and then drained of

any extra arthroscopic fluid. The portals were closed with buried 4.0 Monocryl sutures (Ethicon, Somerville, New Jersey) and Steri-Strips (3M, St. Paul, Minnesota). Final pathologic analysis of the cyst revealed fibromyxoid synovial tissue, consistent with a ganglion, synovial cyst. The resected PCL demonstrated degenerative and proliferative changes, consistent with disruptive enthesopathy.

After surgery, the patient was given crutches for comfort but immediately began physical therapy for range of motion (ROM) and strengthening. On postoperative day 12, he was doing well, with knee flexion to 125° and no difficulty reaching full extension. Two months after surgery, he reported much improved knee pain, denied any pain with ambulation, and resumed running. Knee ROM was well maintained, with flexion to 125° and full extension. The patient denied any knee instability. At 1-year follow-up, he reported running 10 miles without discomfort. At 5-year follow-up, he reported continuing all normal activities, including distance running, without knee pain or discomfort. Physical examination revealed knee flexion to 150° with full extension, and radiographs showed well-maintained joint spaces (Figure 3).

DISCUSSION

Incidence of cystic masses of the PCL has varied with detection method.^{2,3,5,8} Shetty and colleagues⁸ retrospectively reviewed the cases of 1206 patients who underwent MRI for knee pain. Of these patients, 23 (1.9%) had ganglion cysts involving the PCL. Bui-Mansfield and Youngberg³ reported a slightly lower rate; only 8 ganglion cysts of the PCL (0.5%) were appreciated in 1767 knee MRIs. Incidence of ganglion cysts of the PCL seen arthroscopically is lower still, as Krudwig and colleagues⁵ noted only 16 cysts (0.2%) in approximately 8000 arthroscopic knee procedures. Although increased use of MRI and diagnostic arthroscopy has led to improved awareness of ganglion cysts of the PCL, questions remain as to their clinical significance, pathogenesis, and appropriate management.

Although ganglia and synovial cysts technically are different entities—ganglia have a connective-tissue capsule and viscous contents, whereas synovial cysts are a membrane-lined collection of synovial fluid—the terms are often used interchangeably or even in combination (ganglion cyst), as they are essentially identical from a clinical perspective.⁵ The true etiology of intra-articular ganglion cysts of the knee remains unknown, but it is believed that they result either from a mucinous degeneration of connective tissue or from a herniation of synovial tissue and could be either congenital or secondary to repetitive microtrauma.^{5,9}

The most common reports from patients presenting with symptomatic ganglion cysts of the PCL is vague discomfort or pain. Often the pain is described as dull or aching and, occasionally, it can be located along the joint line, with symptoms worsening with more rigorous activities, with posture changes, and with maximum

knee flexion.^{2,4-7,9,11,13} In addition, patients may present with loss of ROM of the affected knee, as ganglion cysts of the ACL tend to limit terminal extension, whereas those of the PCL tend to limit terminal flexion.^{5,13} However, it has been noted that ganglion cysts of either cruciate ligament can unpredictably affect either flexion or extension, and thus ROM limitations do not reliably correlate with cyst location.^{6,7,10,14} Yasuda and Majima¹⁵ initially proposed that decreased ROM was secondary to a mechanical block caused by the ganglion cyst, but this has been questioned, primarily because of the patient's ability to achieve full ROM when examined under anesthesia. It has also been proposed that limited ROM is actually caused by stimulation of nerve endings in the synovial membrane during cyst compression, thus leading to decreased ROM secondary to discomfort.^{4,7,13} This theory explains the ability to achieve full ROM under anesthesia (as was seen in our patient's case) and justifies why the vast majority of PCL ganglion cysts are incidental findings, and asymptomatic. A cyst that is not compressed, because of its small size or intra-articular location, would not cause pain or decreased ROM.⁵

Reported management options for PCL ganglion cysts have varied from conservative, nonoperative management to ultrasound-guided or computed tomography-guided aspiration and arthroscopic cyst removal; symptom improvements and extremely low recurrence rates have been reported for these treatment options.^{2,4-8,10,13,16-20} DeFriend and colleagues,¹⁶ reporting on use of percutaneous ultrasound-guided aspiration in 2 patients with ganglion cysts of the PCL, noted complete relief of symptoms and lack of recurrence at 1- and 2-year follow-ups, respectively. Huang and colleagues¹⁸ treated 10 patients with symptomatic ACL or PCL ganglion cysts. Eight patients (4 ACL, 4 PCL) were treated with resection, and the other 2 patients (both PCL) were treated with ultrasound-guided aspiration. All 10 patients experienced improvement in symptoms, and there were no recurrences over a follow-up period ranging from 7 months to 2 years. Shetty and colleagues⁸ arthroscopically resected ganglion cysts of the PCL in 20 patients and found no cyst recurrence on MRI evaluation at a mean follow-up of 2 years. In 13 of the 20 patients, the ganglion cyst was the only knee pathology found arthroscopically, and all 13 patients experienced relief of symptoms after resection.

In all previously reported cases, however, the ganglion cyst was amenable to isolated resection or aspiration, and the integrity of the PCL was maintained. In our patient's case, the ganglion cyst originated from the PCL, which led to degeneration and enthesopathic changes in the ligament. The mucinous appearance of the remaining ligament fibers—few interposed healthy fibers remained—raised the concern that the patient's symptoms might continue or recur if the degenerative tissue were not removed. In addition, it was unclear if performing only partial debridement of the remaining ligament, and thus

allowing mucinous tissue to remain, would predispose the patient to cyst recurrence. Therefore, the decision was made during the course of the arthroscopic cyst resection to remove the entire PCL, even though doing so meant creating a PCL-deficient knee. The possibility of resection of the entire PCL had been discussed with the patient before the procedure. He was informed that it was unclear whether the cyst could be removed in isolation, without compromising the integrity of the PCL. Kumar and colleagues²¹ reported good results in a case of cystic degeneration of the ACL treated with resection of the ganglion and ACL, but cystic degeneration of the PCL appears to be a newly reported phenomenon. Thus, the appropriate treatment for a ganglion cyst arising from the PCL and associated with complete degeneration of the ligament itself remains unclear.

The PCL has long been known to be the primary restraint against posterior tibial translation, but secondary roles include resistance to external tibial rotation and varus stress in the flexed knee.²²⁻²⁴ The interplay of these functions of the PCL leads to a complex change in kinematics after PCL injury or resection, which has been hypothesized to lead to a higher rate of patellofemoral and medial compartment osteoarthritis in PCL-deficient knees.²²⁻²⁵ Logan and colleagues²⁶ used MRI to assess tibiofemoral motion between 0° and 90° of flexion in 6 patients with a PCL-deficient knee and compared the results with those of the contralateral, intact knees. They reported that PCL deficiency led to a "fixed" anterior translation of the medial femoral condyle on the medial tibial plateau, and they hypothesized that this may increase susceptibility to osteoarthritis in the medial compartment. Keller and colleagues²⁷ retrospectively reviewed 40 patients treated nonoperatively after an isolated PCL injury, with a mean follow-up of 6 years. They noted increased pain and difficulty with ambulation as well as increased radiographic degenerative joint changes. In addition, Boynton and Tietjens¹ evaluated 30 patients with isolated PCL-deficient knees, at a mean follow-up of 13.4 years, and reported that 81% of patients experienced at least occasional pain, and 56% had at least occasional swelling at time of final evaluation. In addition, radiographs showed increased articular degeneration with longer time from initial injury. However, several investigators have reported successful subjective outcomes with nonoperative management of PCL-deficient knees.²⁸⁻³¹ Patel and colleagues³² reported the results of 58 knees treated nonoperatively for an acute, isolated PCL injury, with a mean follow-up of 6.9 years. Mean Lysholm-II knee score at latest follow-up was 85.2 points, with results being "excellent" in 23 knees (40%), "good" in 30 knees (52%), "fair" in 2 knees (3%), and "poor" in 3 knees (5%). Shelbourne and Muthukaruppan²⁹ prospectively followed 215 patients with acute isolated PCL injuries treated nonoperatively, for a mean of 7.8 years, noting a mean (SD) total Noyes knee score of 85.6 (15.0) points, with scores remaining consistent during the follow-up

period. In addition, there was no correlation between objective posterior laxity and subjective outcome scores, and thus it was concluded that no identifiable characteristics would predict which patients would have deteriorating knee function after an isolated PCL injury.

There are no clear prognostic indicators as to which isolated PCL-deficient knees will progress to become symptomatic and undergo articular surface degeneration.¹ In addition, there is no definitive evidence that PCL reconstruction alters the natural history of the PCL-deficient knee, and there are no randomized controlled trials demonstrating increased clinical benefits of PCL reconstruction vs nonoperative management.³³ It was concerning to remove a PCL from a very active runner, but the decision to proceed in this case was based on the significant amount of mucinous degeneration of the remaining ligament and on the uncertainty as to whether the remaining fibers would become a source of symptoms or cyst recurrence. The option of performing an arthroscopic cyst resection and leaving the remaining fibers intact was raised, with the possibility of a repeat arthroscopy in the future if warranted by symptoms. However, given the patient's prolonged course of symptoms and prior arthroscopy with no symptomatic improvement, it was determined that, in this case, it would be best to eliminate the PCL as a possible pain generator. As this method of management has not yet been reported for a ganglion cyst of the PCL, with the mucinous degeneration of the remaining ligament, the indications for this procedure are not well defined. The patient in this report was an avid runner. We would be more hesitant to perform a PCL resection in an athlete who is more active in sports that require cutting movements, such as soccer or tennis, as this procedure may not be as well tolerated. At this point, an individualized approach that considers patient age, activity level, and goals must be taken, as the optimal course of treatment for the PCL-deficient knee remains unknown.

In this report, we presented the case of a very active patient who had excellent, asymptomatic knee function 5 years after PCL resection for a ganglion cyst and enthesopathic degeneration of the PCL. In our opinion, PCL resection should be considered a viable option in this uncommon scenario.

AUTHORS' DISCLOSURE STATEMENT

The authors report no actual or potential conflict of interest in relation to this article.

REFERENCES

1. Boynton MD, Tietjens BR. Long-term followup of the untreated isolated posterior cruciate ligament-deficient knee. *Am J Sports Med.* 1996;24(3):306-310.
2. Brown MF, Dandy DJ. Intra-articular ganglia in the knee. *Arthroscopy.* 1990;6(4):322-323.
3. Bui-Mansfield LT, Youngberg RA. Intraarticular ganglia of the knee: prevalence, presentation, etiology, and management. *AJR Am J Roentgenol.* 1997;168(1):123-127.
4. Kim RS, Kim KT, Lee JY, Lee KY. Ganglion cysts of the posterior cruciate ligament. *Arthroscopy.* 2003;19(6):E36-E40.
5. Krudwig WK, Schulte KK, Heinemann C. Intra-articular ganglion cysts of the knee joint: a report of 85 cases and review of the literature. *Knee Surg Sports Traumatol Arthrosc.* 2004;12(2):123-129.
6. Nakagawa Y, Matsusue Y, Nakamura T. Ganglia of the posterior cruciate ligament. A report of three cases and a review of the literature. *Bull Hosp Jt Dis.* 1998;57(3):165-168.
7. Noda M, Kurosaka M, Maeno K, Mizuno K. Case report ganglion cysts of the bilateral cruciate ligaments. *Arthroscopy.* 1999;15(8):867-870.
8. Shetty GM, Nha KW, Patil SP, et al. Ganglion cysts of the posterior cruciate ligament. *Knee.* 2008;15(4):325-329.
9. Zantop T, Rusch A, Hassenpflug J, Petersen W. Intra-articular ganglion cysts of the cruciate ligaments: case report and review of the literature. *Arch Orthop Trauma Surg.* 2003;123(4):195-198.
10. Deutsch A, Veltre DM, Altchek DW, Potter HG, Warren RF, Wickiewicz TL. Symptomatic intraarticular ganglia of the cruciate ligaments of the knee. *Arthroscopy.* 1994;10(2):219-223.
11. Bromley JW, Cohen P. Ganglion of the posterior cruciate ligament: report of a case. *J Bone Joint Surg Am.* 1965;47:1247-1249.
12. Outerbridge RE. The etiology of chondromalacia patellae. 1961. *Clin Orthop.* 2001;(389):5-8.
13. Sumen Y, Ochi M, Deie M, Adachi N, Ikuta Y. Ganglion cysts of the cruciate ligaments detected by MRI. *Int Orthop.* 1999;23(1):58-60.
14. Kaempffe F, D'Amato C. An unusual intra-articular ganglion of the knee with interosseous extension. A case report. *J Bone Joint Surg Am.* 1989;71(5):773-775.
15. Yasuda K, Majima T. Intra-articular ganglion blocking extension of the knee: brief report. *J Bone Joint Surg Br.* 1988;70(5):837.
16. DeFriend DE, Schranz PJ, Silver DA. Ultrasound-guided aspiration of posterior cruciate ligament ganglion cysts. *Skeletal Radiol.* 2001;30(7):411-414.
17. Favorito PJ, Schwend RM. Intraarticular knee ganglion: a case report of an unusual cause of limping in a 4-year-old. *J Pediatr Orthop B.* 2000;9(2):125-127.
18. Huang GS, Lee CH, Chan WP, et al. Ganglion cysts of the cruciate ligaments. *Acta Radiol.* 2002;43(4):419-424.
19. Recht MP, Applegate G, Kaplan P, et al. The MR appearance of cruciate ganglion cysts: a report of 16 cases. *Skeletal Radiol.* 1994;23(8):597-600.
20. Seki K, Mine T, Tanaka H, Isida Y, Taguchi T. Locked knee caused by intra-articular ganglion. *Knee Surg Sports Traumatol Arthrosc.* 2006;14(9):859-861.
21. Kumar A, Bickerstaff DR, Grimwood JS, Suvama SK. Mucoid cystic degeneration of the cruciate ligament. *J Bone Joint Surg Br.* 1999;81(2):304-305.
22. Gill TJ, DeFrate LE, Wang C, et al. The effect of posterior cruciate ligament reconstruction on patellofemoral contact pressures in the knee joint under simulated muscle loads. *Am J Sports Med.* 2004;32(1):109-115.
23. Li G, Papanagari R, Li M, et al. Effect of posterior cruciate ligament deficiency on in vivo translation and rotation of the knee during weightbearing flexion. *Am J Sports Med.* 2008;36(3):474-479.
24. Sekiya JK, Whiddon DR, Zehms CT, Miller MD. A clinically relevant assessment of posterior cruciate ligament and posterolateral corner injuries. Evaluation of isolated and combined deficiency. *J Bone Joint Surg Am.* 2008;90(8):1621-1627.
25. Skyhar MJ, Warren RF, Ortiz GJ, Schwartz E, Otis JC. The effects of sectioning of the posterior cruciate ligament and the posterolateral complex on the articular contact pressures within the knee. *J Bone Joint Surg Am.* 1993;75(5):694-699.
26. Logan M, Williams A, Lavelle J, Gedroyc W, Freeman M. The effect of posterior cruciate ligament deficiency on knee kinematics. *Am J Sports Med.* 2004;32(8):1915-1922.
27. Keller PM, Shelbourne KD, McCarroll JR, Rettig AC. Nonoperatively treated isolated posterior cruciate ligament injuries. *Am J Sports Med.* 1993;21(1):132-136.
28. Shelbourne KD, Davis TJ, Patel DV. The natural history of acute, isolated, nonoperatively treated posterior cruciate ligament injuries. A prospective study. *Am J Sports Med.* 1999;27(3):276-283.
29. Shelbourne KD, Muthukaruppan Y. Subjective results of nonoperatively treated, acute, isolated posterior cruciate ligament injuries. *Arthroscopy.* 2005;21(4):457-461.
30. Parolie JM, Bergfeld JA. Long-term results of nonoperative treatment of isolated posterior cruciate ligament injuries in the athlete. *Am J Sports Med.* 1986;14(1):35-38.
31. Fowler PJ, Messieh SS. Isolated posterior cruciate ligament injuries in athletes. *Am J Sports Med.* 1987;15(6):553-557.
32. Patel DV, Allen AA, Warren RF, Wickiewicz TL, Simonian PT. The nonoperative treatment of acute, isolated (partial or complete) posterior cruciate ligament-deficient knees: an intermediate-term follow-up study. *HSS J.* 2007;3(2):137-146.
33. Petrigliano FA, McAllister DR. Isolated posterior cruciate ligament injuries of the knee. *Sports Med Arthrosc.* 2006;14(4):206-212.

This paper will be judged for the Resident Writer's Award.